



Case report

Laparoscopic lymph node biopsy for lymphoma with a novel use of indocyanine green fluorescence in a 66-year-old male patient

Marco Casaccia^{a,*}, Marco Mora^b, Gregorio Santori^c, Chiara Ghiggi^d, Emanuele Angelucci^d^a *Surgical Clinic Unit II, Department of Surgical Sciences and Integrated Diagnostics (DISC), University of Genoa, Genoa, Italy*^b *Department of Pathology, IRCCS Ospedale Policlinico San Martino, Genoa, Italy*^c *Department of Surgical Sciences and Integrated Diagnostics (DISC), University of Genoa, Genoa, Italy*^d *Hematology Unit and Transplant Center, IRCCS Ospedale Policlinico San Martino, Genoa, Italy*

ARTICLE INFO

Keywords:

Indocyanine green
ICG
Fluorescence
Laparoscopic surgery
Laparoscopic biopsy
Lymphoma
Case report

ABSTRACT

Introduction: Indocyanine green (ICG) near-infrared fluorescence is primarily employed in detecting Intra-operative sentinel lymph node (SLN) mapping or to evaluate the extent of radical lymphadenectomy mainly in colo-rectal and gastric cancer. To date there are no reports indicating the use of this dye to detect pathologic lymphatic tissue when a lymph node biopsy for suspected lymphoproliferative disease is performed.

Presentation of case: A 66-year-old male patient was admitted to the hospital for severe pain of left renal colic type. A computed tomography (CT) scan and a positron emission tomography (PET) showed a left hydro-ureteronephrosis due to ureter compression by paraortic solid tissue of lymphomatous aspect with a standardized uptake value (SUV) of 15. Multiple lymphadenopathies on paracaval, para-aortic and common iliac sites were present as well.

Discussion: A laparoscopic lymph node biopsy (LLB) was planned for diagnostic purposes. After induction of anesthesia a ICG solution was injected Intradermally at both inguinal regions. At laparoscopy a complete visualization of the pathologic lymphnodes was achieved, enabling incisional biopsies of the lymphomatous mass. Histopathological examination showed an extranodal localization of an aggressive B-cell non-Hodgkin lymphoma.

Conclusion: ICG-fluorescence seems to offer a simple and safe method for pathologic lymph node detection. LLB in the suspicion of intra abdominal lymphoma can largely take advantage by this novel opportunity not yet tested to date. More studies with large case series are needed to confirm the efficacy of ICG-fluorescence for detecting pathologic lymph nodes.

1. Introduction

Near-infrared indocyanine green (ICG) fluorescence can be a very valuable tool for intraoperative decision-making in minimally invasive surgeries. Real-time visualization of lymph flow (lymphatic mapping) was proven as feasible, potentially helping the surgeon to more accurate staging. In addition, lymphatic mapping can help identify the pattern and status of lymph node basin implementing the concept of tailored lymphadenectomy.

ICG fluorescence for sentinel lymph node (SLN) detection has been previously described with promising results for breast, endometrial and cervical, gastric, colorectal and pancreatic carcinoma [1–3]. The

effectiveness of ICG fluorescent imaging was affirmed by two systematic reviews, done by Van der Zaag et al. and Emile et al. [4,5].

When a lymphoproliferative disease is suspected, a surgical biopsy of the pathological lymph nodes is required to establish the diagnosis. When the inguinal, axillary, cervical lymph nodes are accessible this is easy to approach. If the lymphadenopathies are deeply located in the abdomen, a needle biopsy is often not possible due to proximity to large vessels and the risk of bleeding. In this setting a laparoscopic lymph node biopsy (LLB) is the correct option.

Until now, no records are reported in literature concerning the use of ICG for the diagnosis of lymphoproliferative diseases with involvement of the abdominal lymph node stations. In this case, we describe the

* Corresponding author at: UOC Clinica Chirurgica 1, IRCCS Azienda Ospedaliera Universitaria San Martino, IST Monoblocco XI piano - Largo Rosanna Benzi, 10 16132 Genova, Italy.

E-mail address: marco.casaccia@unige.it (M. Casaccia).

<https://doi.org/10.1016/j.ijscr.2021.106692>

Received 17 November 2021; Received in revised form 12 December 2021; Accepted 14 December 2021

Available online 20 December 2021

2210-2612/© 2021 The Authors. Published by Elsevier Ltd on behalf of IJS Publishing Group Ltd. This is an open access article under the CC BY-NC-ND license

(<http://creativecommons.org/licenses/by-nc-nd/4.0/>).

laparoscopic biopsy of periaortic pathologic lymph nodes stained with ICG by means of a preoperative injection of an ICG solution into the inguinal regions.

2. Case report

A 66-year-old male patient was admitted to the hospital emergency room for severe pain of left renal colic type. No previous abdominal surgery or relevant past medical history were present. The only altered laboratory tests were serum creatinine 1.7 mg/dL, Beta 2 microglobulin 2.2 mg/L and PCR C-reactive protein 73 mg/L. The computed tomography (CT) scan showed a left hydronephrosis due to ureter compression by paraortic solid tissue with a lymphomatous aspect. Multiple lymphadenopathies on paracaval, para-aortic and Common iliac sites were present as well. The next day a ureteral stent was placed to resolve the hydronephrosis.

A fluorodeoxyglucose (FDG) positron emission tomography (PET) showed a pathological uptake with standardized uptake value (SUV) of 15 at the level of the paraortic lymphomatous tissue while a lower uptake occurred for the lymphadenopathies located along the aorta and below the aforementioned tissue with extension to the aorto-bisiliac carrefour and to the proximal tract of the left common iliac artery (max SUV 5) (Fig. 1). Therefore, a LLB was planned for diagnostic purposes in the suspicion of a lymphoproliferative disease. The procedure was performed by MC, surgeon experienced in laparoscopic procedures.

2.1. Surgical technique

After induction of anesthesia, Indocyanine green (ICG) (Verdyne, Diagnostic Green GmbH, Aschheim-Dornach, Germany) was administered to the patient placed in the lithotomy position. The concentration used was 2.5 mg/mL. A 25 mg vial with ICG powder was diluted in 10 cc of aqueous sterile water. Three milliliters of this ICG solution was injected intradermally at both inguinal regions, at the level of the femoral triangle of Scarpa.

The pneumoperitoneum was achieved through the umbilicus via an open technique; a 10-mm trocar was inserted to accommodate a 30°-angle telescope. A 10-mm trocar was inserted in the right iliac fossa and a 5-mm trocar in the right hypocondrium. The surgeon and camera holder stood on the right side of the patient. A right tilt and mild Trendelenburg position were given to the table. Para-aortic lymphadenopathy was reached by an incision of the peritoneum covering the superior part of

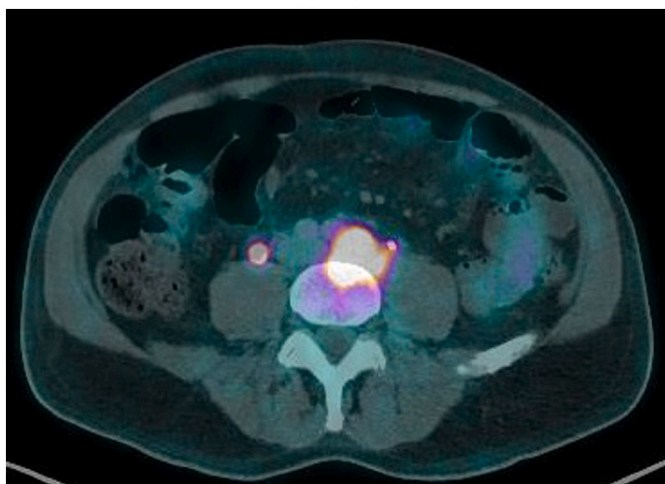


Fig. 1. Fluorodeoxyglucose (FDG) positron emission tomography (PET) showing a pathological uptake with standardized uptake value (SUV) of 15 at the level of the paraortic lymphomatous tissue.

the right common iliac artery. This incision was prolonged along the left aspect of the aorta, just above the inferior mesenteric artery.

A Thunderbeat™ (Olympus Medical Systems Corp., Tokyo, Japan) device was used for dissection. A dedicated clinical endoscopic system (Visera Elite II, Olympus Medical Systems Corp., Tokyo, Japan) equipped with infra-red (IR) light source and IR UHD telescope was used to illuminate regional lymph nodes. To obtain a clear visualization of the surgical field due to the small bowel, one transabdominal stay suture was passed through the edge (margin) of the incised peritoneum for lifting it, achieving a better exposition (Fig. 2). Taking advantage of the lymphatic drainage that from the superficial inguinal lymph nodes drain first to the body's external iliac lymph nodes, second to the pelvic lymph nodes, and finally to the paraaortic lymph nodes, twenty minutes after the injection, lymph nodes stained with ICG were observed in the subserosa, surrounding the left iliac artery (Fig. 3). Pathologic nodes came into contact with the known mass. An incisional biopsy of the same was made in two different points (Fig. 4). The operation was completed laparoscopically and an abdominal drainage was not necessary. The postoperative course was uneventful and the patient was discharged at postoperative day 1. Histopathological examination showed an extranodal localization of an aggressive B-cell non-Hodgkin lymphoma. The work has been reported in line with the SCARE criteria [6].

3. Discussion

Reports on the use of ICG in medical practice have been described since the second half of the last century [7]. Particularly following recent developments in video endoscopy techniques, the use of ICG has expanded to include many different specialties and with different medical applications. The value of ICG-fluorescence guided surgery is now established in colo-rectal and gastric surgery as well as in breast surgery and in gynecological field. The real-time visualization of lymphatic flow (lymphatic mapping) has proven feasible, potentially aiding the surgeon to identify sentinel lymph nodes and to perform a better lymphadenectomy [8].

In the suspicion of lymphoproliferative disease and when isolated abdominal lymphadenopathy is poorly accessible to percutaneous biopsy, LLB is the key tool for making diagnosis [9–11].

Paraortic and pericaval lymph nodes are often affected by the onset of the disease, and when they are the only sites involved, diagnosis can be difficult. In fact, due to the proximity to the great vessels, an ultrasound or a CT-guided biopsy is not viable due to the high risk of bleeding. The option of a laparoscopic biopsy approach is safer in this setting. The technique is now standardized according to two situations: supramesocolic and submesocolic lymphadenopathy [12]. In case of supramesocolic lymphadenopathy (lymph nodes of the celiac axis, hepatic pedicle, splenic hilum) the access to these structures doesn't represent a real obstacle. On the other hand, in case of submesocolic

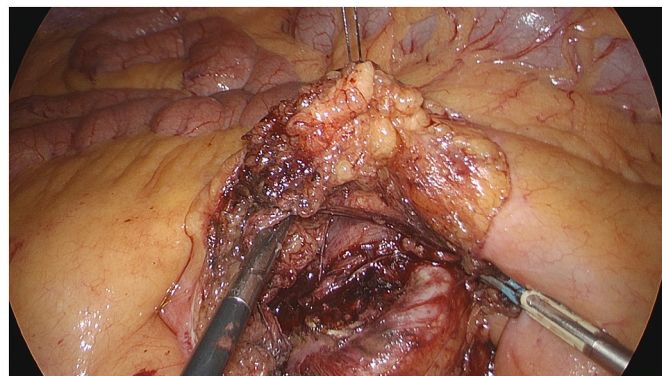


Fig. 2. A transabdominal stay suture is passed through the margin of the incised peritoneum for lifting it.

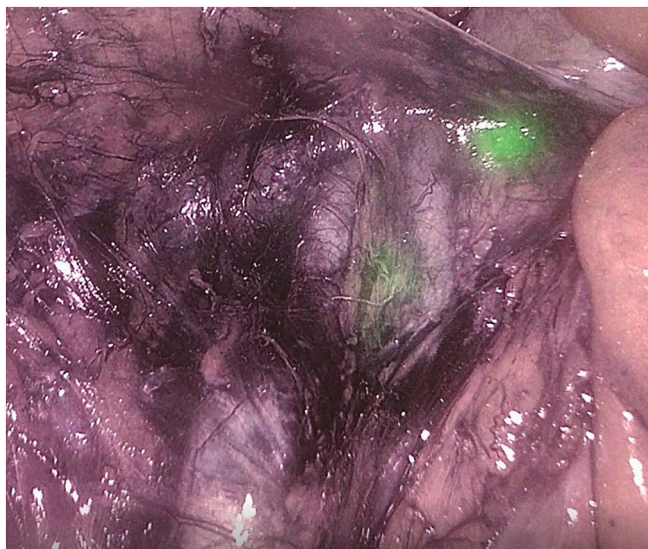


Fig. 3. Lymph nodes stained with ICG in the subserosa, surrounding the left iliac artery.

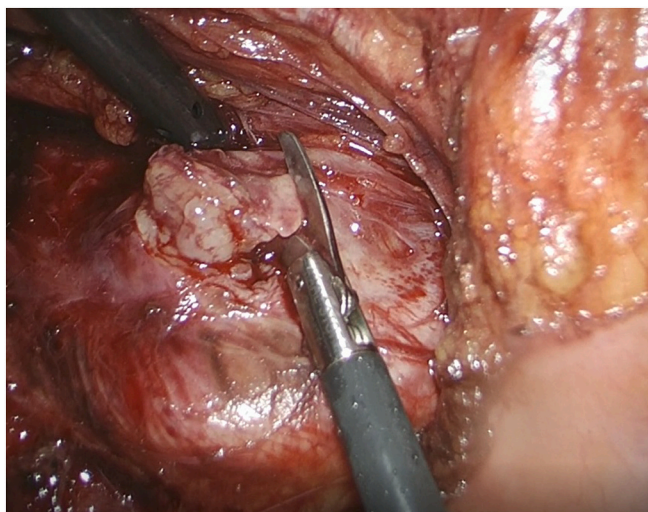


Fig. 4. Incisional biopsy of the paraortic lymphomatous tissue.

lymphadenopathy (lymph nodes of the mesentery, periaortic, pericaval and periiliac) the deep situation, the presence of surrounding fatty tissues and the small bowel can make the procedure technically demanding.

In our case, instead of adding one or more trocars, we succeeded to obtain a correct exposition of the surgical field by means of trans-abdominal sutures as described in the “puppeteering technique” [13]. In literature there are only sporadic reports on the use of fluorescence ICG in abdominal lymphomas but its use for diagnostic purposes is via intravenous infusion in the case of lymphoma originating from the intestinal wall [14,15].

Our report is the first to describe the use of ICG fluorescence in the search for pathological lymph nodes in the suspicion of lymphoproliferative disease originating from the abdominal lymph nodes.

In this setting, however, the issue of whether the dye is retained by the pathological lymph node as the healthy one is not known up to now. In colo-rectal or gastric cancer, after the peritumoral injection of ICG, the dye follows the lymphatic pathways and colors the lymph nodes it finds along the collectors. The presence of cancer cells within the metastatic lymph node does not seem to decrease the intensity of staining

[16].

However, this statement is not univocal. Widespread lymph node metastases have been observed to induce an obstruction of lymphatic channels, and lymphatic drainage is bypassed to other (nonsentinel) lymph nodes [17]. In our case, the iliac lymph nodes visualized at PET as pathological, at laparoscopy turned out to be stained up close to the large lymphomatous lesion. The latter, however, did not stain with ICG. Histopathological examination showed that the tissue biopsied did not belong to a lymph node but it was extranodal tissue. Extranodal involvement can be seen with lymphoma in approximately 25–40% of cases and almost any organ can be involved [18]. This could explain the lack of vital staining as extra-nodal lymphomatous tissue is excluded from lymphatic drainage, as well as could limit the dye's usefulness in detecting pathologic lymph nodes. However in our case, it was mandatory to perform a biopsy on the largest lesion since it had the highest SUV and therefore able to provide us with the best diagnostic indications [19].

Based upon our preliminary experience, ICG-enhanced fluorescence seems to provide several advantages in LLB, allowing both to better identify the surgical anatomy and to reduce the surgical time. The patients who could benefit most would be those in whom dissection could be dangerous due to proximity to the great vessels, or visualization of lymphadenopathies could be difficult because of their deep location. As for other applications of ICG, the characteristics of reproducibility and effectiveness of the method might be confirmed also for LLB, enabling the surgeon to act with greater safety. Our report, although encouraging, needs to be supported by more studies with large case series before considering this novel application of ICG-enhanced fluorescence in LLB as completely reliable.

Funding

This research did not receive any specific grant from funding agencies in the public, commercial, or not-for-profit sectors.

Ethical approval

The Ethical Committee of the IRCCS Ospedale Policlinico San Martino has exempted the work from ethical approval because it involves only negligible risk for the patient; furthermore, the patient data publicly recorded contain only non-identifiable data about him.

Consent

Written informed consent was obtained from the patient for publication of this case report and accompanying images. A copy of the written consent is available for review by the Editor-in-Chief of this journal on request.

Registration of research studies

NA.

Guarantor

Marco Casaccia.

Provenance and peer review

Not commissioned, externally peer-reviewed.

CRediT authorship contribution statement

Marco Casaccia: study design, writing.
Marco Mora: acquisition of data, writing.
Gregorio Santori: review & editing.

Chiara Ghiggi: acquisition of data.

Emanuele Angelucci: Supervision and final approval of the version to be submitted.

Declaration of competing interest

None.

References

- [1] R. Peltrini, M. Podda, S. Castiglioni, et al., Intraoperative use of indocyanine green fluorescence imaging in rectal cancer surgery: the state of the art, *World J. Gastroenterol.* 27 (38) (2021) 6374–6386.
- [2] G.L. Baiocchi, M. Diana, L. Boni, Indocyanine green-based fluorescence imaging in visceral and hepatobiliary and pancreatic surgery: state of the art and future directions, *World J. Gastroenterol.* 24 (27) (2018) 921–930.
- [3] L.A. Moukartzel, J. Feinberg, E.J. Levy, M.M. Leitao Jr., Current and novel mapping substances in gynecologic cancer care, *Int. J. Gynecol. Cancer* 30 (3) (2020) 387–393.
- [4] S.H. Emile, H. Elfeki, M. Shalaby, et al., Sensitivity and specificity of indocyanine green near-infrared fluorescence imaging in detection of metastatic lymph nodes in colorectal cancer: systematic review and meta-analysis, *J. Surg. Oncol.* 116 (2017) 730–740.
- [5] E.S. Van der Zaag, W.H. Bouma, P.J. Tanis, et al., Systematic review of sentinel lymph node mapping procedure in colorectal cancer, *Ann. Surg. Oncol.* 19 (2012) 3449–3459.
- [6] R.A. Agha, T. Franchi, C. Sohrabi, G. Mathew, for the S.C.A.R.E. Group, The SCARE 2020 guideline: updating consensus Surgical CAse REport (SCARE) guidelines, *Int. J. Surg.* 84 (2020) 226–230.
- [7] H.O. Wheeler, W.I. Cranston, J.I. Meltzer, Hepatic uptake and biliary excretion of indocyanine green in the dog, *Proc. Soc. Exp. Biol. Med.* 99 (1958) 11–14.
- [8] A. Hackethal, M. Hirschburger, S.O. Eicker, et al., Role of indocyanine green in fluorescence imaging with near-infrared light to identify sentinel lymph nodes, lymphatic vessels and pathways prior to surgery – a critical evaluation of options, *Geburtshilfe Frauenheilkd.* 78 (1) (2018) 54–62.
- [9] H. Tilly, M. Gomes da Silva, U. Vitolo, et al., on behalf of the European Society for Medical Oncology Guidelines Committee, Diffuse large B-cell lymphoma (dlbcl): esmo clinical practice guidelines for diagnosis, treatment and follow-up, *Ann. Oncol.* 26 (suppl 5) (2015), v116-25.
- [10] R.W.D. Gilbert, B.H. Bird, M.G. Murphy, C.J. O'Boyle, Should laparoscopic lymph node biopsy be the preferred diagnostic modality for isolated abdominal lymphadenopathy? *Curr. Oncol.* 26 (3) (2019) e341–e345.
- [11] S.C. Daly, M. Klairmont, B. Arslan, et al., Laparoscopy has a superior diagnostic yield than percutaneous image-guided biopsy for suspected intra-abdominal lymphoma, *Surg. Endosc.* 29 (2015) 2496–2499.
- [12] M. Casaccia, R.M. Lemoli, E. Angelucci, et al., Feasibility of single-port laparoscopic lymph node biopsy for intra-abdominal lymphoma: a case series, *J. Laparoendosc. Adv. Surg. Tech. A* 31 (4) (2021) 458–461.
- [13] A.G. Chow, S. Purkayastha, E. Zacharakis, P. Paraskeva, Single incision laparoscopic surgery for right hemicolectomy, *Arch. Surg.* 146 (2011) 183–186.
- [14] P.F. Veiga, E. Licardie, I. Alarcón, S. Morales-Conde, Use of fluorescent imaging with indocyanine green (ICG) for the identification of intestinal lymphoma, *Cir. Esp.* 98 (10) (2020) 628.
- [15] C. Esposito, F. Del Conte, M. Cerulo, et al., Clinical application and technical standardization of indocyanine green (ICG) fluorescence imaging in pediatric minimally invasive surgery, *Pediatr. Surg. Int.* 35 (2019) 1043–1050.
- [16] Q.Y. Chen, Q. Zhong, P. Li, et al., Comparison of submucosal and subserosal approaches toward optimized indocyanine green tracer-guided laparoscopic lymphadenectomy for patients with gastric cancer (FUGES-019): a randomized controlled trial, *BMC Med.* 19 (1) (2021) 276.
- [17] W. Kelder, A.E. Braat, A. Karrenbeld, et al., The sentinel node procedure in colon carcinoma: a multi-centre study in the Netherlands, *Int. J. Color. Dis.* 22 (2007) 1509–1514.
- [18] A.G. Glass, L.H. Karnell, H.R. Menck, The National Cancer Data Base report on non-Hodgkin's lymphoma, *Cancer* 80 (1997) 2311–2320.
- [19] A. Noy, H. Schöder, M. Gönen, et al., The majority of transformed lymphomas have high standardized uptake values (SUVs) on positron emission tomography (PET) scanning similar to diffuse large B-cell lymphoma (DLBCL), *Ann. Oncol.* 20 (3) (2009) 508–512.