

Macular Choroidal Thickness: Evaluation of Variability among Measurements and Assessment of Predictive Value of Glaucomatous Visual Field Damage

Maria Marenco^a Federico Rissotto^a Andrea Palamini^a Carlo Alberto Cutolo^a
Giulia Agosto^a Antonio Ferreras^b Carlo Enrico Traverso^a Michele Iester^a

^aEye Clinic, Department of Neuroscience, Rehabilitation, Ophthalmology, Genetics, Maternal and Child Health (DiNOGMI), University of Genoa and Ospedale Policlinico San Martino IRCCS, Genoa, Italy; ^bDepartment of Ophthalmology, IIS-Aragon, Miguel Servet University Hospital, University of Zaragoza, Zaragoza, Spain

Keywords

Glaucoma · Swept-source optical coherence tomography · Choroidal thickness · Retinal nerve fiber layer

Abstract

Introduction: This study aimed to investigate the relationship between the choroidal circulation and glaucoma, assessing macular choroidal thickness (MCT) as a predictive value of glaucomatous visual field damage. **Methods:** Twenty primary open-angle glaucoma patients were recruited. Patients underwent 2 SS-OCT scans: one with DRI OCT (Topcon) and the other with PLEX Elite 9000 (Zeiss). Standard OCT parameters were acquired by DRI OCT, while MCT was manually measured in 5 points on Plex ELITE 9000 images. The relationship among MCT, standard OCT parameters, and visual field indices was evaluated. Pearson's r correlation was calculated to evaluate these relationships. Reproducibility of measurements was analyzed. **Results:** MCT measurements showed a good intra- and interobserver repeatability. A negative correlation appeared between MCT and BMI ($r = -0.518$, $p = 0.023$). Mean deviation showed a statistically significant correlation with MCT measured at subfoveal and at 1,000 μm nasally ($r = 0.50$, $p = 0.03$, and $r = 0.52$, $p = 0.023$). A correlation was found between the 2 MCT (Zeiss vs. Topcon) measurements and between MCT and peripapillary choroidal

thickness ($r = 0.944$ and $r = 0.740$, $p < 0.001$, respectively).

Conclusions: A good intra- and interobserver reproducibility was found. MCT showed a weak predictive value of glaucomatous visual field damage. A significant correlation was found between MCT and BMI.

© 2021 The Author(s)

Published by S. Karger AG, Basel

Introduction

Primary open-angle glaucoma (POAG) is a multifactorial chronic, progressive, optic neuropathy characterized by typical structure-function changes. Progressive retinal ganglion cell loss in the macula, peripapillary, and optic disc area is typical of this disease [1, 2]. The exact mechanical and/or vascular pathophysiology of glaucoma remains unclear [3]. It has been also hypothesized that impaired choroidal structure and function are involved in the glaucomatous optic neuropathy, since the choroidal vasculature supplies the prelaminar portion of the optic nerve head (ONH) [4–8]. An association between choroidal morphology and glaucoma was found in previous histological studies, in which the authors showed thinner choroidal layer in glaucomatous eyes than in nonglaucomatous ones [9–11], even if it is unclear whether this finding represents a risk factor or a consequence of the dis-

ease. Furthermore, in those histological studies, there was some bias such as a small number of patients, the fixation method of the histological samples, the delay between death and fixation that may induce artifacts, and no data for other factors now known to influence choroidal thickness (CT) including age and axial length (AXL) [9, 12, 13]. Also, ethnicity could be related to the CT, but most of the published studies do not outline the race of the included patients which is possible to suppose just reading the affiliation of the study, but it could be also wrong.

The development of a new generation of high-penetration OCT devices, a modified version of spectral-domain optical coherence tomography (SD-OCT), makes OCT be able to improve choroidal assessment and to measure the living choroid into normal and pathological processes. However, the choroidal-scleral boundary may be difficult to identify, and the choroidal segmentation software is not readily available, so the assessment of CT has often relied on manual measurements at localized points [14–17]. These SD-OCT devices are based on an alternative approach to image acquisition, known as swept-source OCT (SS-OCT), and allow for a better viewing of deeper ocular structures including the choroid, besides a segmentation software enables to separate the different retinal layers and the choroid.

The relationship between different types of glaucoma and CT by using SD-OCT and SS-OCT is still under investigation. In some studies, no difference was found for peripapillary or macular choroidal thickness (PCT and MCT, respectively) between OAG patients and normal controls in most of the OCT studies, and no relationship between CT and glaucoma severity was reported [8, 18–25]. However, some other studies have found thinning of PCT or MCT in OAG patients [26–29]. Hirooka et al. [30] reported a relationship between CT and glaucoma severity especially in the nasal region 3 mm from the fovea, which is close to the peripapillary choroid, and it might affect the ONH blood supply [31, 32]. The aim of the present study is to assess interobserver reproducibility and intraobserver repeatability of MCT measurements, to compare 2 SS-OCT measurements of CT, and to evaluate MCT as the predictive value of glaucomatous visual field damage.

Methods

This was a clinical retrospective study, and it was approved by the regional ethics committee (CER Liguria: 144/2021). All methods used were carried out according to the criteria set by the Declaration of Helsinki and by EGS guidelines for the clinical practice

useful for following up patients with glaucoma. Informed consent was obtained from all the participants.

Starting from June 7, 2019, and going backward, we included the first 20 Caucasian POAG consecutive eligible eyes seen at the Eye Clinic of the University of Genoa. The more affected eye was analyzed according to mean deviation (MD) and pattern standard deviation (PSD) values. POAG patients were defined as those with an intraocular pressure (IOP) elevated without treatment, ONH with characteristic glaucomatous damage and/or retinal nerve fiber layer changes, glaucomatous visual field defects, and an open anterior chamber angle on gonioscopy [1].

The inclusion criteria for all subjects were to have no history of retinal or optic disc diseases (for example, diabetic retinopathy, macular degeneration, and optic neuritis), a normal anterior chamber, a clinical diagnosis of POAG at least 1 year before the study, a last follow-up visit within 1 month before the OCT analysis, and an early to moderate glaucoma damage at visual field [1]. The exclusion criteria were to be younger than 18 years old, a refractive error >-6 or 4 diopters of sphere or ± 3 diopters of cylinder, to have a history of ophthalmic diseases that could affect the interpretation of the visual field, and a history of ocular trauma or of glaucoma surgeries.

Standard automated perimetry was performed within 6 months of the image acquisition using the Humphrey Field Analyzer II, program 24-2 Swedish Interactive Threshold Algorithm Standard (Carl Zeiss Meditec, Inc., Dublin, CA, USA). Visual fields were considered reliable if fixation losses or false-negative errors were $<33\%$ and false-positive errors $<15\%$. MD and PSD were used, and the mean sensitivity of superior and inferior hemifield was calculated for each visual field print-out.

Data of the last follow-up visit were recorded and included medical history, BMI, water intake in the previous 2 hours, systolic blood pressure (SBP), diastolic blood pressure (DBP), number of glaucoma medications used, best-corrected visual acuity (using a Snellen chart at 4 m), spherical equivalent (SE), slit-lamp biomicroscopy, IOP measurement (using a calibrated Goldmann applanation tonometer), gonioscopy, dilated fundus examination, cup-to-disc ratio (using a 90D lens), central corneal thickness (CCT), AXL, CT, retinal nerve fiber layer thickness (RNFLT), and ganglion cell-inner plexiform layer thickness (GCIPLT).

All eyes were imaged by using deep range imaging (DRI) OCT Triton, SS-OCT (Topcon, Oakland, NJ, USA), and Swept-Source OCT-A PLEX Elite (Carl Zeiss Meditec Inc.), providing uniform scanning sensitivity which allow superior visualization of the vitreous and choroid in the same scan. Poor quality SS-OCT images, defined as those with signal strength ≤ 40 , were not considered and retaken.

The Topcon DRI OCT uses a multi-modal SS-OCT with a laser source of 1,050 nm and operates at 100,000 A-scans per second. All eyes were imaged using the 3D Wide Scan (12 mm \times 9 mm) with the scan centered on the posterior pole through dilated pupils. All DRI OCT images were obtained by a single and well-trained technician. SS-OCT segmentation software (version 9.11; Topcon, Inc., Tokyo, Japan) was used to identify the limits of the choroid and to determine CT. The data were exported using the manufacturer's OCT-Batch (version 9.1.10) utility.

Topcon DRI OCT Analysis

After segmentation analysis, peripapillary RNFLT and PCT were measured at a 3.4-mm diameter peripapillary circle centered on the optic disc and then divided into 6 and 12 sectors, and the

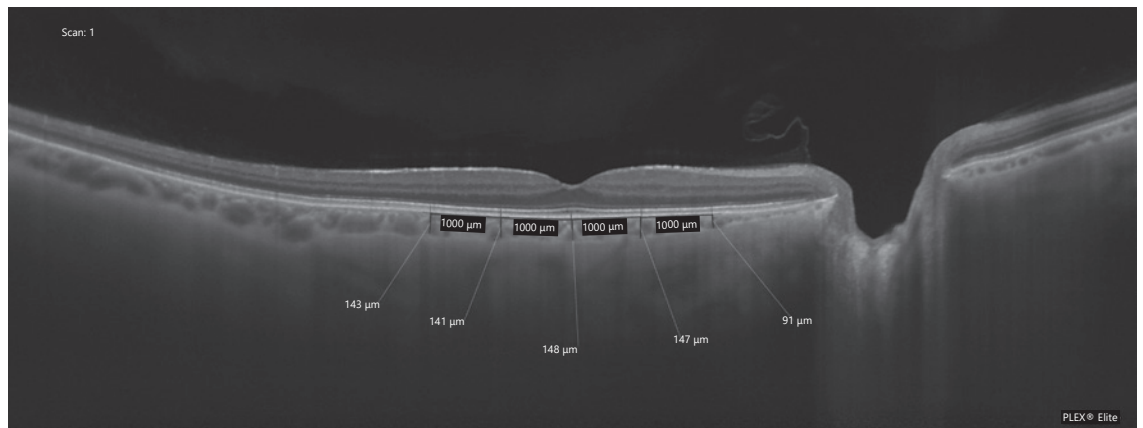


Fig. 1. An image from Plex ELITE 9000 scan of the macula exported to ImageJ. The choroid was delineated over 4 mm by 5 marked locations, centered on the fovea. The outer margin of the RPE was considered the anterior margin of the choroid, and the CSI was the posterior margin of the choroid. RPE, retinal pigment epithelium; CSI, choroidal-scleral interface.

thickness of each single sector was calculated automatically. Mean RNFLT and mean PCT were calculated for each sector. Furthermore, MCT and GCIPLT were calculated automatically by using the software in 6 sectors.

The Swept-Source OCT-A PLEX Elite is a swept laser OCT, utilizing a central wavelength of 1,040- to 1,060-nm sources and a scanning of 100,000 A-scans per second. Its axial and transverse resolutions are approximately 6 μm and 20 μm , respectively. HD spotlight 1 (10–100 \times) scan generates a single high-definition scan at a depth of 3.0 mm with 100 B-scans, each composed of 1,024 A-scans. All HD spotlight 1 scans were centered on the fovea. No image analysis is present on this device for the moment.

Zeiss PLEX Elite 9000 OCT Analysis

All PLEX Elite images were exported to Joint Photographic Expert Group (jpeg) format and analyzed using ImageJ software (<http://imagej.nih.gov/ij/>; provided in the public domain by the National Institutes of Health, Bethesda, MD, USA). The CT was segmented manually from the outer border of the retinal pigment epithelium to the choroidal-scleral interface. A spatial scale was defined to present measurement analysis in micrometer; the straight-line selection tool was used to make a line that corresponded to a known distance of 1,000 μm measured on a PLEX Elite 9000 image using the OCT scale bar.

We measured the CT on horizontally orientated OCT sections at the subfoveal region, at 1,000 μm and 2,000 μm nasal to the fovea and at 1,000 μm and 2,000 μm temporal to the fovea (Fig. 1), as in other published studies [30, 32]. Since the spatial aspect ratio of PLEX Elite 9000 is 2:1, each CT measurement was divided by two [33]. To assess the interobserver reproducibility of the measurements, 4 independent observers (M.M., F.R., A.P., and C.A.C.) manually measured MCT, while for intraobserver repeatability, 1 observer (F.R.) repeated each measurement 3 times.

Statistical Analysis

The statistical analyses were performed using SPSS 21.0 (SPSS, Inc., Chicago, IL, USA). For descriptive analysis, number, percentage, mean, standard deviation, median, minimum, and maximum

values were obtained. The average values of the MCT measured by the observer who repeated each measurement 3 times were used to compare measurements of the 2 different devices and to evaluate the relationship between MCT and the other variables.

Pearson's correlation analysis was conducted to examine the relationship between the measured variables. The relationships between MCT assessed through PLEX Elite 9000 and possible confounding factors including age, gender, race, diabetes mellitus, systemic hypertension, BMI, water intake in the previous 2 hours, SBP, DBP, OPP, SE, IOP, AXL, CCT, visual field MD, visual field PSD, and mean superior and inferior hemifield sensitivity were investigated. The evaluation of the relationships between MCT assessed through Plex Elite 9000 and any OCT parameters (GCIPLT, RNFLT, PCT, and MCT) obtained using DRI OCT Triton was also evaluated.

Coefficient of variation (CoV) was used to analyze the interobserver and intraobserver variability. CoV was calculated using the following formula: $\text{CoV}\% = (\text{SD}/\text{mean}) \times 100$. A CoV exceeding about 30% is often indicative of problems in the data or that the experiment is out of control.

Results

Demographic and Clinical Characteristics of the Study Population

The present study included 20 eyes of 20 patients affected by POAG. The mean age was 74.15 ± 8.39 (\pm standard deviation) (range 56–87 years) with a BMI of 27.82 ± 5.01 kg/m^2 . Eight patients (40%) were females. Eighteen (90%) patients were Caucasian, while 2 (10%) were Latin American. Three patients had diabetes mellitus and 13 systemic hypertension (SBP was 134.25 ± 14.07 , DBP 78.5 ± 10.01 mm Hg, and MAP 95.5 ± 11.11). The water intake in the previous 2 hours was approximately 142.5 ± 185.16 mL.

Table 1. Pearson's correlations between MCT assessed using PLEX Elite 9000 and possible confounding factors

	Mean MCT	2,000 μm temporal to the fovea	1,000 μm temporal to the fovea	Subfoveal	1,000 μm nasal to the fovea	2,000 μm nasal to the fovea
Age						
Pearson's <i>r</i>	-0.39	-0.30	-0.38	-0.43	-0.41	-0.29
<i>p</i> value	0.1	0.21	0.11	0.07	0.08	0.23
Race						
Pearson's <i>r</i>	0.107	0.073	0.070	0.118	0.131	0.110
<i>p</i> value	0.664	0.765	0.777	0.631	0.594	0.654
Gender						
Pearson's <i>r</i>	-0.372	-0.377	-0.377	-0.389	-0.389	-0.240
<i>p</i> value	0.117	0.111	0.112	0.100	0.100	0.322
Diabetes mellitus						
Pearson's <i>r</i>	-0.244	-0.201	-0.221	-0.322	-0.183	-0.209
<i>p</i> value	0.315	0.410	0.363	0.179	0.454	0.391
Hypertension						
Pearson's <i>r</i>	0.102	0.197	0.139	0.126	0.077	-0.068
<i>p</i> value	0.678	0.418	0.571	0.607	0.754	0.782
BMI						
Pearson's <i>r</i>	-0.518*	-0.477*	-0.511*	-0.445	-0.497*	-0.532*
<i>p</i> value	0.023	0.039	0.025	0.056	0.031	0.019
Water intake in the previous 2 hours						
Pearson's <i>r</i>	0.005	0.096	0.069	-0.053	-0.010	-0.069
<i>p</i> value	0.984	0.697	0.779	0.831	0.967	0.780
Glaucoma drugs, <i>n</i>						
Pearson's <i>r</i>	0.229	0.259	0.184	0.226	0.167	0.266
<i>p</i> value	0.346	0.284	0.451	0.353	0.494	0.271
IOP						
Pearson's <i>r</i>	-0.305	-0.399	-0.334	-0.246	-0.262	-0.215
<i>p</i> value	0.204	0.090	0.162	0.309	0.278	0.376
SE						
Pearson's <i>r</i>	0.095	0.158	0.227	-0.007	0.034	0.045
<i>p</i> value	0.700	0.518	0.350	0.978	0.890	0.856
AXL						
Pearson's <i>r</i>	-0.026	-0.168	-0.124	0.107	0.021	0.007
<i>p</i> value	0.916	0.492	0.614	0.663	0.934	0.977
CCT						
Pearson's <i>r</i>	-0.099	0.068	-0.062	-0.013	-0.180	-0.287
<i>p</i> value	0.688	0.782	0.801	0.958	0.462	0.234
Cup-to-disc ratio						
Pearson's <i>r</i>	-0.063	-0.054	0.011	-0.073	-0.139	-0.041
<i>p</i> value	0.799	0.826	0.964	0.767	0.571	0.867
SBP						
Pearson's <i>r</i>	-0.144	-0.081	-0.104	-0.153	-0.217	-0.110
<i>p</i> value	0.557	0.742	0.672	0.531	0.371	0.655
DBP						
Pearson's <i>r</i>	-0.146	-0.098	-0.058	-0.119	-0.229	-0.197
<i>p</i> value	0.550	0.690	0.814	0.629	0.345	0.418
Mean BP						
Pearson's <i>r</i>	-0.147	-0.081	-0.123	-0.123	-0.190	-0.174
<i>p</i> value	0.549	0.742	0.616	0.616	0.437	0.476
Diastolic OPP						
Pearson's <i>r</i>	-0.246	-0.223	-0.128	-0.219	-0.323	-0.287
<i>p</i> value	0.310	0.360	0.600	0.369	0.178	0.233
Systolic OPP						
Pearson's <i>r</i>	-0.086	-0.198	-0.038	-0.108	-0.172	-0.069
<i>p</i> value	0.726	0.999	0.878	0.659	0.480	0.779
Mean OPP						
Pearson's <i>r</i>	-0.074	0.026	-0.039	-0.065	-0.133	-0.130
<i>p</i> value	0.764	0.916	0.874	0.793	0.586	0.596

BMI, body mass index; SE, spherical equivalent; BP, blood pressure; OPP, ocular perfusion pressure. * *p* value <0.05.

Table 2. Pearson's correlations between MCT assessed using PLEX Elite 9000 and visual field parameters

	Mean MCT	2,000 μm temporal to the fovea	1,000 μm temporal to the fovea	Subfoveal	1,000 μm nasal to the fovea	2,000 μm nasal to the fovea
MD						
Pearson's <i>r</i>	0.438	0.318	0.271	0.497*	0.518*	0.454
<i>p</i> value	0.061	0.185	0.262	0.030	0.023	0.051
PSD						
Pearson's <i>r</i>	0.121	0.168	0.207	0.078	0.028	0.100
<i>p</i> value	0.621	0.493	0.395	0.750	0.909	0.684
Mean superior hemifield sensitivity						
Pearson's <i>r</i>	0.054	0.068	-0.070	0.033	0.120	0.130
<i>p</i> value	0.827	0.782	0.777	0.893	0.625	0.597
Mean superior hemifield sensitivity						
Pearson's <i>r</i>	0.124	0.116	0.116	0.199	0.187	0.041
<i>p</i> value	0.613	0.636	0.636	0.413	0.442	0.866

* *p* value <0.05.

Eight eyes were right and 11 were pseudo-phakic. Mean IOP was 15.35 ± 2.8 mm Hg, mean CDR was 0.8 ± 0.12 , and mean CCT was 530.2 ± 40.1 μm . The MD was -6.52 ± 6.39 dB, and the mean PSD was 6.23 ± 3.95 . The mean superior hemifield sensitivity was 21.51 ± 5.18 dB while in the inferior sector was 21.05 ± 7.26 dB.

Reproducibility

Macular choroidal measurements had good intraobserver repeatability (CoV = $2.86\% \pm 0.49$), while the interobserver reproducibility was higher (CoV = $11.51\% \pm 1.28$).

Correlation with Possible Confounding Factors

Mean MCT and each MCT measurement evaluated from images acquired using Swept-Source OCT-A PLEX Elite 9000 showed a significant negative correlation with BMI, except the subfoveal one which showed only a tendency to be significant ($r = -0.445$, $p = 0.056$). By contrast, all the CT measurements were not significantly correlated with other possible confounding factors including age, gender, race, diabetes mellitus, systemic hypertension, water intake in the previous 2 hours, SBP, DBP, OPP (systolic, diastolic, and mean), SE, IOP, AXL, and CCT (Table 1).

Correlation with Visual Field Indices

When correlation between PLEX Elite 9000 CT and visual field indices (MD and PSD) and mean superior and inferior hemifield sensitivity was analyzed, there was only a statistically significant correlation for MCT when mea-

sured at the subfoveal area and at 1,000 μm nasal to the fovea measurements and MD ($r = 0.50$, $p < 0.05$, and $r = 0.52$, $p < 0.05$, respectively) (Table 2).

Correlation with OCT Parameters

When the relationship between PLEX Elite 9000 MCT and DRI OCT Triton OCT parameters such as GCIPLT, RNFLT, PCT, and MCT was calculated, only a positive statistically significant correlation was found between the 2 MCT measurements and between MCT and PCT ($r = 0.944$, $p < 0.01$, and $r = 0.740$, $p < 0.01$, respectively) (Table 3).

Discussion

Since the choroid is a dynamic ocular structure, CT can change due to several factors [31], such as age, IOP, BP, refractive errors, and AXL. A thinner choroid is associated with older age, higher IOP, higher myopia, thicker CCT, and longer AXL [31, 32], while a thicker choroid to a higher diastolic perfusion pressure, a lower IOP, and male sex [32]. Furthermore, CT also varies on a diurnal basis [32], and a significant increase in CT happens during the water drinking test in POAG [31].

The glaucoma vascular theory attributes the optic neuropathy to intraneural ischemia for the hypoperfusion of the optic disc at the level of lamina cribrosa [34, 35]. Since the blood supply of the prelaminar portion of the ONH comes from the peripapillary choroid branches, several

Table 3. Pearson's correlations between MCT assessed using PLEX Elite 9000 and OCT parameters assessed using DRI OCT Triton

	Mean MCT	2,000 μm temporal to the fovea	1,000 μm temporal to the fovea	Subfoveal	1,000 μm nasal to the fovea	2,000 μm nasal to the fovea
Total RNFL						
Pearson's <i>r</i>	0.014	-0.077	-0.107	0.035	0.125	0.089
<i>p</i> value	0.955	0.754	0.662	0.886	0.611	0.717
Total PCT						
Pearson's <i>r</i>	0.740***	0.498*	0.596**	0.814***	0.764***	0.800***
<i>p</i> value	<0.001	0.030	0.007	<0.001	<0.001	<0.001
Total GCIPL						
Pearson's <i>r</i>	0.148	0.080	0.064	0.168	0.245	0.134
<i>p</i> value	0.545	0.744	0.796	0.493	0.312	0.585
Total MCT						
Pearson's <i>r</i>	0.944***	0.840***	0.909***	0.970***	0.915***	0.801***
<i>p</i> value	<0.001	<0.001	<0.001	<0.001	<0.001	<0.001

* *p* value <0.05. ** *p* value <0.01. *** *p* value <0.001.

studies are being conducted to investigate the relationship between the choroidal circulation and glaucoma. In glaucomatous eyes, histologic and imaging (i.e., ultrasonography) studies on CT, as a marker of choroidal blood flow, have produced inconsistent findings [9, 12, 36]. The development of methods to measure CT in vivo has given a new boost to research in new directions for both normal and pathological processes, showing conflicting results [8, 18–29].

In this study, 2 different OCT devices were used and compared. The PLEX Elite 9000 OCT, although without a built-in analysis software, showed good images easy to analyze with an external program. A good intraobserver repeatability and interobserver reproducibility were found. Furthermore, an excellent correlation between the 2 SS-OCT measurements ($p < 0.01$) was found for CT measurements (Table 3), while no other correlation was found between CT and other OCT parameters such as RNFLT and GCIPL (Table 3).

In this study, mean MCT measured ($193.45 \mu\text{m} \pm 95.22 \mu\text{m}$) was thinner when compared with results of other studies among healthy individuals, in particular Ruiz-Medrano et al. [37] showed that mean MCT was $229.7 \pm 66.1 \mu\text{m}$ in subjects older than 60 years. Furthermore, MCT was not correlated with any possible confounding factors, except with BMI ($r = -0.518$; $p < 0.05$).

To the best of our knowledge, this is the first study evaluating the relationship between BMI and CT in POAG patients. Yilmaz et al. [38] reported that higher BMI was associated with thinner choroids in healthy in-

dividuals, while Dogan et al. [39] showed that the MCT of the morbidly obese subjects was statistically thinner than that of the nonobese subjects. By contrast, another study [40] revealed in an obese group significant choroidal tissue thickening subfoveally and at areas 500 μm temporal, 500 μm nasal, and 1,500 μm nasal to the fovea (all $p < 0.05$) and reported a positive correlation between BMI and CT changes.

Furthermore, in the present study, we found a weak positive correlation between MCT and MD visual field: in particular, only the subfoveal and the nasal point at 1,000 μm from the fovea measurements were correlated with MD. Due to the *p* values and the number of correlations studied in Table 2, we could also hypothesize that this result could be obtained just for chance. The lack of correlation between CT and VF could be also related to the horizontal OCT scan we performed in this study, and a vertical OCT scan could have shown a better correlation to the visual field. In several other studies, no correlation between CT and glaucoma visual field progression was found in OAG [18, 21, 23, 41–47]. In particular, Nakakura et al. [41] found no significant difference between POAG and normal subjects for MCT measured by SS-OCT, and besides this was not a significant predictive factor. In another study, also Karaca et al. [42] showed similar results for MCT and PCT between healthy and POAG eyes with different severity of visual field defect. When macular and/or peripapillary CT was correlated with visual field MD, no significant correlation was found in glaucomatous patients [21, 28, 44].

In different studies using SS-OCT, Song et al. [45] and Zhang et al. [18] showed no correlation between PCT or MCT and MD in glaucomatous eyes. Also, the Beijing Eye Study 2011 [46] could not find any association between subfoveal CT and MD in patients affected by glaucoma, including OAG, primary angle-closure glaucoma, and secondary angle-closure glaucoma.

Different results were reported by Park et al. [43] who found a PCT thinning in OAG and pre-perimetric glaucoma patients relative to normal controls; PCT was related to disc area, AXL, and age, but not with glaucoma severity (MD) in OAG. Lin et al. [47] reported that in all the glaucoma subjects of their study, PCT was not significantly correlated with white-on-white MD ($p > 0.05$), but a significant correlation with blue-on-yellow MD ($p < 0.05$) was found. Furthermore, in early glaucomatous eyes, PCT showed significant correlations with white-on-white MD and blue-on-yellow MD ($p < 0.05$).

The current study has some limitations. A small number of eyes were measured, making it difficult to make the results generalizable for all eyes. Furthermore, a control group was not used, and the manual segmentation of MCT could have reduced the accuracy of the CT assessment, although the CoV was good. Besides, we did not evaluate the relationship between IOP-lowering drugs and CT, even if in a recent study IOP values were related to CT [48].

Conclusion

Our study showed a strong correlation between CT and BMI. Further studies are needed with a larger number of patients to evaluate whether MCT would be a useful marker to aid in evaluation for glaucoma detection and progression.

References

- 1 European glaucoma society terminology and guidelines for glaucoma. 4th edition – chapter 2: classification and terminology supported by the EGS foundation: part 1: foreword; introduction; glossary; chapter 2 classification and terminology. *Br J Ophthalmol* 2017;101(5):73–127.
- 2 Heijl A, Leske MC, Bengtsson B, Hyman L, Bengtsson B, Hussein M. Reduction of intraocular pressure and glaucoma progression: results from the early manifest glaucoma trial. *Arch Ophthalmol*. 2002;120(10):1268–79.
- 3 Hayreh SS. Inter-individual variation in blood supply of the optic nerve head. Its importance in various ischemic disorders of the optic nerve head, and glaucoma, low-tension glaucoma and allied disorders. *Doc Ophthalmol*. 1985;59(3):217–46.
- 4 Flammer J, Orgül S, Costa VP, Orzalesi N, Kriegelstein GK, Metzner Serra L, et al. The impact of ocular blood flow in glaucoma. *Prog Retin Eye Res*. 2002;21(4):359–93.
- 5 Cioffi GA, Granstam E, Alm A. Ocular circulation. In: Kaufman PL, Alm A, editors. *Adler's physiology of the eye*. 10th ed. St. Louis: Mosby; 2003. p. 747–84.
- 6 Cristini G, Cennamo G, Daponte P. Choroidal thickness in primary glaucoma. *Ophthalmologica*. 1991;202(2):81–5.
- 7 Tan CS, Ngo WK, Chew MC, Li KZ, Lim LW, Sadda SR. Diurnal variation of retinal thickness measured by optical coherence tomography in normal adults. *Invest Ophthalmol Vis Sci*. 2012;53(3):1639–40. Published 2012 Mar 21.
- 8 Zhang Z, Yu M, Wang F, Dai Y, Wu Z. Choroidal thickness and open-angle glaucoma: a meta-analysis and systematic review. *J Glaucoma*. 2016;25(5):e446–54.
- 9 Yin ZQ, Vaegan, Millar TJ, Beaumont P, Sarks S. Widespread choroidal insufficiency in primary open-angle glaucoma. *J Glaucoma*. 1997;6:23–32.

Acknowledgment

This work was developed within the framework of the DINOG-MI Department of Excellence of MIUR 2018-2022 (Law 232 of 2016).

Statement of Ethics

This was a clinical retrospective study, and it was approved by the regional ethics committee (CER Liguria: 144/2021). All methods used were carried out according to the criteria set by the Declaration of Helsinki and by EGS guidelines for the clinical practice useful for following up patients with glaucoma. Written informed consent was obtained from all the participants.

Conflict of Interest Statement

Authors have no financial or proprietary interest in any material or method mentioned.

Funding Sources

There are no funding sources to declare.

Author Contributions

M.M. and M.I. conceived the study; M.M., F.R., A.P., C.A.C., and G.A. collected the data and patients; M.I. analyzed the data; M.M., A.F., C.E.T., and M.I. wrote the manuscript; all the authors revised and approved the final version of the manuscript.

Data Availability Statement

The datasets generated and analyzed during the current study are not publicly available because we are going to use them for a different purpose, but they are available from the corresponding author on reasonable request.

- 10 Kubota T, Jonas JB, Naumann GO. Decreased choroidal thickness in eyes with secondary angle closure glaucoma. An aetiological factor for deep retinal changes in glaucoma? *Br J Ophthalmol*. 1993;77:430–2.
- 11 Francois J, Neetens A. Vascularity of the eye and the optic nerve in glaucoma. *Arch Ophthalmol*. 1964;71:219–25.
- 12 Spraul CW, Lang GE, Lang GK, Grossniklaus HE. Morphometric changes of the choriocapillaris and the choroidal vasculature in eyes with advanced glaucomatous changes. *Vision Res*. 2002;42:923–32.
- 13 Arora KS, Jefferys JL, Maul EA, Quigley HA. The choroid is thicker in angle closure than in open angle and control eyes. *Invest Ophthalmol Vis Sci*. 2012;53:7813–8.
- 14 Spaide RF, Koizumi H, Pozzoni MC, Pozzoni MC. Enhanced depth imaging spectral-domain optical coherence tomography. *Am J Ophthalmol*. 2008;146:496–500.
- 15 Pellegrini M, Shields CL, Arepalli S, Shields JA. Choroidal melanocytosis evaluation with enhanced depth imaging optical coherence tomography. *Ophthalmology*. 2014;121:257–61.
- 16 Margolis R, Spaide RF. A pilot study of enhanced depth imaging optical coherence tomography of the choroid in normal eyes. *Am J Ophthalmol*. 2009;147(5):811–5.
- 17 Ikuno Y, Kawaguchi K, Nouchi T, Yasuno Y. Choroidal thickness in healthy Japanese subjects. *Invest Ophthalmol Vis Sci*. 2010;51:2173–6.
- 18 Zhang C, Tatham AJ, Medeiros FA, Zangwill LM, Yang Z, Weinreb RN. Assessment of choroidal thickness in healthy and glaucomatous eyes using swept source optical coherence tomography. *PLoS One*. 2014;9(10):e109683.
- 19 Mwanza JC, Sayyad FE, Budenz DL. Choroidal thickness in unilateral advanced glaucoma. *Invest Ophthalmol Vis Sci*. 2012;53(10):6695–701.
- 20 Mwanza JC, Hochberg JT, Banitt MR, Feuer WJ, Budenz DL. Lack of association between glaucoma and macular choroidal thickness measured with enhanced depth-imaging optical coherence tomography. *Invest Ophthalmol Vis Sci*. 2011;52(6):3430–5.
- 21 Maul EA, Friedman DS, Chang DS, Boland MV, Ramulu PY, Jampel HD, et al. Choroidal thickness measured by spectral domain optical coherence tomography: factors affecting thickness in glaucoma patients. *Ophthalmology*. 2011;118(8):1571–9.
- 22 Li L, Bian A, Zhou Q, Mao J. Peripapillary choroidal thickness in both eyes of glaucoma patients with unilateral visual field loss. *Am J Ophthalmol*. 2013;156(6):1277–84.e1.
- 23 Hosseini H, Nilforushan N, Moghimi S, Bitrian E, Riddle J, Lee GY, et al. Peripapillary and macular choroidal thickness in glaucoma. *J Ophthalmic Vis Res*. 2014;9(2):154–61.
- 24 Ehrlich JR, Peterson J, Parlitsis G, Kay KY, Kiss S, Radcliffe NM. Peripapillary choroidal thickness in glaucoma measured with optical coherence tomography. *Exp Eye Res*. 2011;92(3):189–94.
- 25 Suh W, Cho HK, Kee C. Evaluation of peripapillary choroidal thickness in unilateral normal-tension glaucoma. *Jpn J Ophthalmol*. 2014;58(1):62–7.
- 26 Hirooka K, Tenkumo K, Fujiwara A, Baba T, Sato S, Shiraga F. Evaluation of peripapillary choroidal thickness in patients with normal-tension glaucoma. *BMC Ophthalmol*. 2012;12:29.
- 27 Roberts KF, Artes PH, O'Leary N, Reis AS, Sharpe GP, Hutchison DM, et al. Peripapillary choroidal thickness in healthy controls and patients with focal, diffuse, and sclerotic glaucomatous optic disc damage. *Arch Ophthalmol*. 2012;130(8):980–6.
- 28 Park HY, Lee NY, Shin HY, Park CK. Analysis of macular and peripapillary choroidal thickness in glaucoma patients by enhanced depth imaging optical coherence tomography. *J Glaucoma*. 2014;23(4):225–31.
- 29 Usui S, Ikuno Y, Miki A, Matsushita K, Yasuno Y, Nishida K. Evaluation of the choroidal thickness using high-penetration optical coherence tomography with long wavelength in highly myopic normal-tension glaucoma. *Am J Ophthalmol*. 2012;153(1):10–6.e1.
- 30 Hirooka K, Fujiwara A, Shiragami C, Baba T, Shiraga F. Relationship between progression of visual field damage and choroidal thickness in eyes with normal-tension glaucoma. *Clin Exp Ophthalmol*. 2012;40(6):576–82.
- 31 Goharian I, Sehi M. Is there any role for the choroid in glaucoma? *J Glaucoma*. 2016;25(5):452–8.
- 32 Zhang X, Cole E, Pillar A, Lane M, Waheed N, Adhi M, et al. The effect of change in intraocular pressure on choroidal structure in glaucomatous eyes. *Invest Ophthalmol Vis Sci*. 2017;58(7):3278–85.
- 33 Sigal IA, Schuman JS, Ishikawa H, Kagemann L, Wollstein G. A problem of proportions in OCT-based morphometry and a proposed solution. *Invest Ophthalmol Vis Sci*. 2016;57(2):484–5.
- 34 Weinreb RN, Aung T, Medeiros FA. The pathophysiology and treatment of glaucoma: a review. *JAMA*. 2014;311(18):1901–11.
- 35 Agarwal R, Gupta SK, Agarwal P, Saxena R, Agrawal SS. Current concepts in the pathophysiology of glaucoma. *Indian J Ophthalmol*. 2009;57(4):257–66.
- 36 Curcio CA, Messinger JD, Sloan KR, Mitra A, McGwin G, Spaide RF. Human chorioretinal layer thicknesses measured in macula-wide, high-resolution histologic sections. *Invest Ophthalmol Vis Sci*. 2011;52(7):3943–54.
- 37 Ruiz-Medrano J, Flores-Moreno I, Peña-García P, Montero JA, Duker JS, Ruiz-Moreno JM. Macular choroidal thickness profile in a healthy population measured by swept-source optical coherence tomography. *Invest Ophthalmol Vis Sci*. 2014;55(6):3532–42.
- 38 Yilmaz I, Ozkaya A, Kocamaz M, Ahmet S, Ozkaya HM, Yasa D, et al. Correlation of choroidal thickness and body mass index. *Retina*. 2015;35(10):2085–90.
- 39 Dogan B, Kazim Erol M, Dogan U, Habibi M, Bulbul N, Turgut Coban D, et al. The retinal nerve fiber layer, choroidal thickness, and central macular thickness in morbid obesity: an evaluation using spectral-domain optical coherence tomography. *Eur Rev Med Pharmacol Sci*. 2016;20(5):886–91.
- 40 Yumusak E, Ornek K, Durmaz SA, Cifci A, Guler HA, Bacanli Z. Choroidal thickness in obese women. *BMC Ophthalmol*. 2016;16(1):48.
- 41 Nakakura S, Yamamoto M, Terao E, Nagasawa T, Tabuchi H, Kiuchi Y. The whole macular choroidal thickness in subjects with primary open angle glaucoma. *PLoS One*. 2014;9(10):e110265.
- 42 Karaca U, Özge G, Mumcuoglu T, Usta G. No relationship between visual field damage and choroidal thickness in eyes with primary open angle glaucoma. *Ophthalmic Res*. 2020;63(5):491–6.
- 43 Park Y, Kim HK, Cho KJ. Comparison of peripapillary and macular choroidal thickness and ganglion cell complex thickness in glaucomatous and healthy eyes. *Int J Ophthalmol*. 2019;12(4):603–6.
- 44 Akil H, Al-Sheikh M, Falavarjani KG, Francis B, Chopra V. Choroidal thickness and structural glaucoma parameters in glaucomatous, preperimetric glaucomatous, and healthy eyes using swept-source OCT. *Eur J Ophthalmol*. 2017;27(5):548–54.
- 45 Song YJ, Kim YK, Jeoung JW, Park KH. Assessment of open-angle glaucoma peripapillary and macular choroidal thickness using swept-source optical coherence tomography (SS-OCT). *PLoS One*. 2016;11(6):e0157333.
- 46 Wang YX, Xu L, Shao L, Zhang YQ, Yang H, Wang JD, et al. Subfoveal choroidal thickness and glaucoma. *The Beijing Eye Study 2011*. *PLoS One*. 2014;9(9):e107321.
- 47 Lin Z, Huang S, Huang P, Guo L, Shen X, Zhong Y. The diagnostic use of choroidal thickness analysis and its correlation with visual field indices in glaucoma using spectral domain optical coherence tomography. *PLoS One*. 2017;12(12):e0189376.
- 48 Marengo M, Vagge A, Traverso CE, Iester M. Immediate choroidal expansion after bleb needling. *Case Rep Ophthalmol*. 2020;11(3):658–67.