

## GuttaCore Pink, Thermafil and Warm Vertically compacted gutta-percha retreatment: Time required and quantitative evaluation by using ProTaper files

David Emilio FRACCHIA<sup>1</sup>, Andrea AMAROLI<sup>1,2</sup>, Nicola DE ANGELIS<sup>1</sup>, Antonio SIGNORE<sup>1,3</sup>, Steven PARKER<sup>1</sup>, Stefano BENEDECENTI<sup>1</sup> and Andrea POLESEL<sup>1</sup>

<sup>1</sup> Department of Surgical Sciences and Integrated Diagnostic, University of Genoa, Largo Rosanna Benzi 8, Genova 16132, Italy

<sup>2</sup> Department of Orthopaedic Dentistry, Sechenov First Moscow State Medical University, Trubetskaya St. 8, Bldg. 2, Moscow 119991, Russia

<sup>3</sup> Faculty of Therapeutic Stomatology, Institute of Dentistry, I. M. Sechenov First Moscow State Medical University, Trubetskaya St. 8, Bldg. 2, Moscow 119991, Russia

Corresponding author, Andrea AMAROLI; E-mail: andrea.amaroli.71@gmail.com

The goal of non-surgical treatment is to obtain an access to the root canal system in order to remove the previous filling. We analyzed 45 human single-canal roots, mesial roots of mandibular molars and distal roots of maxillary molars without previous endodontic treatment, fractures, resorptive defects or open apices. We evaluated the time required to retreat root canals obturated by a new generation of GuttaCore, GuttaCore Pink<sup>®</sup>, compared to Thermafil<sup>®</sup> and Warm Vertically compacted gutta-percha, by using ProTaper<sup>®</sup> Retreatment and ProTaper<sup>®</sup> Universal. Moreover, a quantitative analysis of residual filling material in the canal after retreating and shaping was performed. The Kruskal-Wallis and Dunn's test were used to determine significant differences. Our data show that the GuttaCore Pink<sup>®</sup> can be removed from the root canal system in a lower amount of time compared to the Thermafil<sup>®</sup>. Concerning the amount of residual filling material, there are no significant differences between the three groups.

**Keywords:** Endodontic retreatment, GuttaCore Pink, ProTaper retreatment, Root canal

### INTRODUCTION

The number of patients needing endodontic retreatment has increased progressively over the years<sup>1</sup>. Periradicular persistent infection and secondary infection are major causes of endodontic failure<sup>2</sup>. The goal of non-surgical treatment is to obtain an access to the root canal system, in order to remove the previous filling, to allow a new accurate shaping as well as disinfection through the removal of both the necrotic tissue and infectious bacteria<sup>2</sup>. There are many techniques available to remove root obturation materials, ranging from the use of solvents, to heat sources or ultrasonic devices, to mechanical steel instruments, laser, ultrasounds, reciprocating steel systems and nickel-titanium (NiTi) rotary instruments<sup>3,4</sup>. However, despite the presence of many methods and devices, several studies have shown that it is not possible to completely remove the previous filling<sup>5,6</sup>. NiTi instruments have been widely used for shaping the root canal system and they have also been proposed for retreatment<sup>7</sup>. The most commonly-used system is the ProTaper<sup>®</sup> Retreatment (PTUR; Dentsply Sirona, Ballaigues, Switzerland), whose effectiveness has been widely demonstrated<sup>8,9</sup>. During retreatment, a variety of filling materials can be found: cement, sealer and gutta-percha cones with cold lateral condensation technique, Warm Vertically compacted gutta-percha technique, or Warm Vertically compacted gutta-percha that is carrier-based, firstly using a steel carrier and then a plastic one<sup>10,11</sup>. The device referenced in the latter

filling example has been commercialized under the name of Thermafil<sup>®</sup> (Dentsply Sirona). However, the plastic carrier does not simplify retreatments.

Additionally, GuttaCore<sup>®</sup> (Dentsply Sirona) has been introduced to the market within recent years. This is a carrier-based system with a cross-linked gutta-percha carrier instead of a plastic carrier. According to the manufacturer, this particular cross-linked gutta-percha is able to guarantee the same advantages as Thermafil<sup>®</sup>, but its removal in case of retreatment and post space-preparation is more straightforward.

Beasley *et al.*<sup>12</sup> first highlighted that GuttaCore<sup>®</sup> could be removed in less time from moderately curved canals using ProTaper files than either Warm Vertically compacted gutta-percha or Thermafil Plus<sup>®</sup> materials.

Nevares *et al.*<sup>13</sup> showed in a sample of forty-five maxillary central incisors that replacing a plastic core with cross-linked gutta-percha allows easier removal of the carrier from the root canal.

In addition, Endal *et al.*<sup>14</sup> pointed out that GuttaCore<sup>®</sup> can be removed in less time from root-end cavities than a root filling performed with a cold lateral condensation technique and Rödiger *et al.*<sup>15</sup> demonstrated that regaining a working length was significantly quicker with GuttaCore<sup>®</sup> when compared with Thermafil<sup>®</sup> and vertically-compacted gutta-percha.

Recently a new GuttaCore with a Pink internal core of cross-linked gutta-percha (GuttaCore Pink<sup>®</sup>) has been introduced on the market, to replace the previous generation of GuttaCore<sup>®</sup>, which showed risks of carrier fractures during their introduction within the canal.

Using an approach similar to that of Beasley *et al.*

Color figures can be viewed in the online issue, which is available at J-STAGE.

Received Jan 12, 2019; Accepted Mar 18, 2019

doi:10.4012/dmj.2019-008 JOI JST.JSTAGE/dmj/2019-008

*al.*<sup>12)</sup>, we evaluated and compared the time required to retreat root canals obturated with the new generation of GuttaCore Pink<sup>®</sup>, compared to Thermafil<sup>®</sup> or Warm Vertically compacted gutta-percha, when using PTUR in combination with ProTaper<sup>®</sup> Universal (PTU). In accordance with Nevares *et al.*<sup>13)</sup>, a quantitative analysis of residual filling material (cleaning rate) in the canal after retreating and shaping were performed. With our study, 45 human single-canal roots, mesial roots of mandibular molars and distal roots of maxillary molars without previous endodontic treatment, fractures, resorptive defects, or open apices were analyzed. The samples were randomly divided into 3 groups using a computerized algorithm obtaining 3 experimental groups ( $n=15$ ).

## MATERIALS AND METHODS

### Ethics approval

All procedures performed in our study involving human participants were in accordance with the ethics standards of the institutional and national research committee and with the 1964 Helsinki declaration and its later amendments or comparable ethical standards. The work was approved by Ethical Committee of Department of Surgical Sciences and Integrated Diagnostic, University of Genoa, n°0010710.

### Specimen preparation

In this study 45 human teeth extracted for orthodontic and periodontal reasons were used. Single-canal roots, mesial roots of mandibular molars and distal roots of maxillary molars without previous endodontic treatment, fractures, resorptive defects, or open apices were selected. The samples were stored in plastic containers with a capacity of 50 mL. The samples were then numbered and immersed in 0.9% sodium chloride at room temperature.

All samples were radiographed from a buccal-lingual direction with 30.5×40.5 mm X-ray plates Ultraspeed<sup>®</sup> (Carestream Dental, Assago, Italy) and were randomly divided into 3 groups using a computerized algorithm (<http://www.random.org>) obtaining 3 experimental groups ( $n=15$ ). Grouping assignment was masked until specimens were prepared for obturation. Access cavities were prepared using high-speed diamond burs with water cooling. A size 10 K-type stainless steel file was advanced in the canal until the tip was visualized through the apical foramen with the aid of a magnifying system 4.5× (Prismatic Headgear Flip-up<sup>®</sup>, Univet, Rezzato, Italy). In order to standardize the samples, the teeth were decoronated with a diamond bur and the working length (WL) was established at 15 mm.

### Shaping and cleaning

All specimens were prepared by a single operator. To achieve canal shaping an endodontic motor X Smart<sup>®</sup> Plus (Dentsply Sirona) was used in order to standardize the experimental protocol. Each canal was navigated initially by using a 10 K-file (Dentsply

Sirona) to the working length and the pre-flaring of the canal was performed with the ProGlider<sup>®</sup> system (0.16–2%, Dentsply Sirona) at 300 rpm and torque 4.0 Ncm according to the manufacturer's instructions. For the canal shaping the ProTaper<sup>®</sup> Next system (Dentsply Sirona) was used. In order to standardize the procedure, all samples were prepared with an apex diameter ISO 30. The first instrument used was the ProTaper<sup>®</sup> Next X1 (0.17–4%) followed by the ProTaper<sup>®</sup> Next X2 (0.25–6%) and the ProTaper<sup>®</sup> Next X3 (0.30–7%), in continuous rotation at 300 rpm and torque of 4.0 Ncm

After each instrument use, the canals were rinsed with 1 mL of 5 % NaOCl at room temperature for 10 seconds and the apical patency was checked with a #10 K-file. After shaping, each canal was irrigated with 1 mL of 17% EDTA for 3 min, before being rinsed with 2 mL of 5 % NaOCl for 10 s. Irrigating solutions were brought with a 5 cc syringe and 27-G needle with Luer Lock connection.

At the end of this phase the grouping assignments were unmasked.

### Obturation

The samples were filled three-dimensionally with Warm Vertically compacted gutta-percha, Thermafil<sup>®</sup>, GuttaCore Pink<sup>®</sup> (Fig. 1).

#### 1. Group 1, Warm Vertical compaction ( $n=15$ )

The samples were completely dried with sterile paper points ProTaper<sup>®</sup> Next X3 (Dentsply Maillefer, Ballaigues, Switzerland). A master gutta-percha cone ProTaper<sup>®</sup> Next X3 size #30 with taper 7% was selected and the tug back was checked. The gutta-percha cone was coated with Topseal<sup>®</sup> (Dentsply Sirona) and introduced into the canal. The down-pack was performed in accordance with the continuous-wave condensation technique with the System B<sup>®</sup> (SybronEndo) adjusted to 200°C, with the fine tip (ISO 40, taper 6%).

The backfilling was carried out by compacting gutta-percha with System-B and previously calibrated pluggers.

#### 2. Group 2, Thermafil<sup>®</sup> ( $n=15$ )

In this group the instructions provided by the Thermafil<sup>®</sup>'s manufacturer (Dentsply Maillefer) were followed. To determine the correct obturator size a "Verifier"<sup>®</sup> (Dentsply Maillefer) ISO 30 and taper 5% was used.

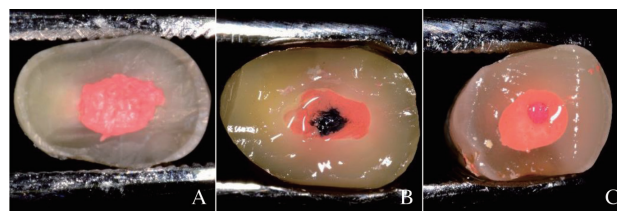


Fig. 1 Examples of samples filled three-dimensionally with Warm Vertically compacted gutta-percha (A), Thermafil<sup>®</sup> (B), GuttaCore Pink<sup>®</sup> (C).

An Obturator Thermafil® X3 (size ISO 30) was selected. The canal was completely dried with sterile paper points ProTaper® Next X3 (Dentsply Maillefer). With the tip of a sterile paper point a small amount of cement Topseal® (Dentsply Maillefer) was applied to the entrance of the canal.

After having been heated in the Thermaprep 2 Oven® (Dentsply Maillefer) adjusted to the lowest temperature (Size 20-30), the obturator was immediately placed with a slow and continuous movement (about 6 s to reach the working length), to avoid an increase of the vertical hydraulic pressure and the consequent exit of the material beyond the apex. After reaching the pre-set length, the Thermafil® was kept in place by applying a pressure for 8–10 s before being sectioned with a diamond bur at the opening of the canal.

### 3. Group 3, GuttaCore Pink® (n=15)

In this group the instructions provided by the GuttaCore's manufacturer (Dentsply Maillefer) were also followed. With a GuttaCore® ISO Verifier® ISO 30 and taper 5% the reaching of a passive working length without interference was verified. The canals were perfectly dried with sterile paper points ProTaper® Next X3 (Dentsply Maillefer) and cement Topseal® (Dentsply Maillefer) was added to canal outlet with sterile paper points.

The GuttaCore Pink® obturator X3 was selected and heated using Thermaprep 2 Oven® (Dentsply Maillefer), adjusted to the lower temperature (Size 20–30). The obturator was inserted with a slow and continuous movement (about 6 s), reaching the working length, keeping it in position for about 8–10 s, allowing the gutta-percha to cool. The obturator's handle was sectioned with an excavator at the level of the opening of the canal.

After obturation, the samples were radiographed from a buccolingual direction to determinate the quality of the filling. The teeth were stored in 0.9% sodium chloride at room temperature for 2 weeks. The samples were masked and re-treated in a random order.

### Retreatment

To remove the gutta-percha from the 3 groups VC, Thermafil® and GuttaCore Pink®, the PTUR was used according to the sequence D1, D2 e D3 (Dentsply Maillefer) and the PTU (Dentsply Maillefer) was used without the aid of solvents. The PTUR was set with 3 different lengths respectively: D1 to 5 mm, D2 to 10 mm, D3 to 15 mm, to allow each instrument to clean a specific region of the canal. The PTU F4 was used at working length, 15 mm. After each instrument, the canals were rinsed with 1 mL 5% NaOCl at room temperature for 10 s. After each use, each file was checked with a magnifying lens 4.5× (Prismatic Headgear Flip-up®, Univet) and any alteration or separation of the instrument was recorded.

All instruments were used with an endodontic motor X Smart® Plus (Dentsply Maillefer) in continuous rotation at 500 rpm and a torque of 4.0 Ncm. A single

operator performed the retreatments. The preparation was considered complete when the instruments were not covered with filling material anymore and when the irrigating solution appeared clear.

After instrumentation each sample was irrigated with 2 mL 17% EDTA, and left in the canal for 3 min before being rinsed with 3 mL 5% NaOCl for 10 s. The canals were then dried with sterile paper points.

### Time required to remove the filling material

The time to reach the predetermined working length for each sample was recorded in seconds, not including changes of instruments and irrigation<sup>12)</sup>. The total time for all files in the sequence to reach the predetermined working length with PTUR was designated as T1 and represents an objective measure of efficiency<sup>12)</sup>.

A PTU F4 (Dentsply Maillefer) was used (size ISO 40 and taper 6%). The time required to obtain a complete removal of the obturating material with PTU F4 was designated as T2.

### Microscopic evaluation of the retreatment

Two longitudinal grooves on the outer surface of the roots were created using a diamond disc and each sample was split into two halves with a stainless-steel chisel. The samples were examined through an optical microscope, as suggested by Nevares *et al.*<sup>13)</sup>, modified by higher magnification at 12× (stereomicroscope apochromatic Wild Heerbrugg M5A®) and expression as mean area of residues. The area occupied by any remaining gutta-percha was measured in mm<sup>2</sup>, with an image analyzer (Leica Q500IW®, Buccinasco, Italy, Fig. 2).

### Statistical analysis

The analysis is performed by analysis of variance (ANOVA) one-way or non-parametric test, called Kruskal-Wallis. A non-parametric *post-hoc* tests for multiple comparisons, Dunn's test, was also performed,

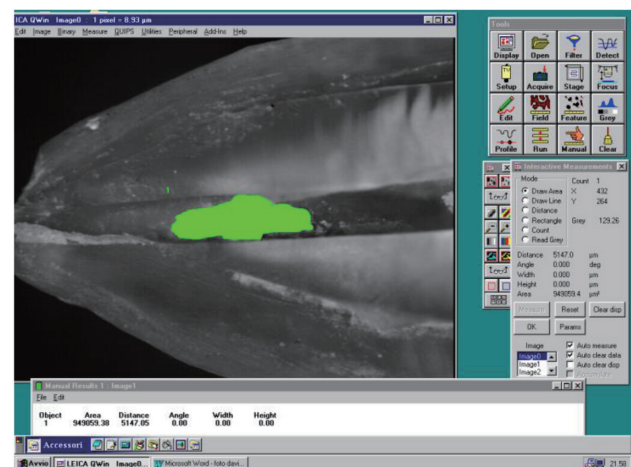


Fig. 2 Example of a residue variable surface area in the treatment groups analysed by the image analyser (Leica Q500IW®).

when necessary. Values of  $p < 0.05$  were considered significant.

## RESULTS

### Results of the retreatment time T1 and T2

The results of the retreatment times are showed in Tables 1 and 2.

The data's analysis leads to a significant Kruskal-Wallis test with a  $p$ -value=0.0054 ( $< 0.05$ ) for the T1 and a  $p$ -value=0.0048 ( $< 0.05$ ) for the T2, so that we can assert that there is a mean difference among the 3 groups for the variables T1 and T2.

Once the significance of the difference between the groups has been established, it must be assessed which groups are different and in which of these groups the difference can be considered significant. For this

purpose, one of the non-parametric *post-hoc* tests for multiple comparisons, the Dunn's test was used and the following results were obtained:

#### 1. T1 variable

Concerning variable T1 (Tables 1–3), the test was performed at a significance level of 5%. Between Warm Vertically compacted gutta-percha (WV) and GuttaCore Pink® (GCP) the  $p$ -value was not significant ( $> 0.05$ ), therefore we can say that there is no difference in the means of the two groups. While for the Warm Vertically compacted gutta-percha-Thermafil® (TH) and GuttaCore Pink®-Thermafil® comparison, the  $p$ -value was significant ( $< 0.05$ ).

In particular we can say:

- Warm Vertically compacted gutta-percha-Thermafil®: Warm Vertically compacted gutta-

Table 1 The descriptive statistics of the T1 variable in the treatment groups

Group	Samples number	Mean-time (s)	Minimum-time (s)	Maximum-time (s)	St deviation
TH	15	136.9	50	418	103.629468
WV	15	78.1	29	248	72.9483108
GCP	15	64.5	20	243	61.495025

TH=Thermafil®; WV=Warm Vertically compacted gutta-percha; GCP=GuttaCore Pink®

Table 2 The descriptive statistics of the T2 variable in the treatment groups

Group	Samples number	Mean time (s)	Minimum time (s)	Maximum time (s)	St deviation
TH	15	112	29	227	57.9784443
WV	15	55.2	17	150	31.6839648
GCP	15	58.1	29	114	29.4372618

TH=Thermafil®; WV=Warm Vertically compacted gutta-percha; GCP=GuttaCore Pink®

Table 3 Dunn's test T1 variable

Comparing groups	Mean difference	$p$ -value Dunn's test
WV vs. GC	13.34	0.2478
WV vs. TH	-58.86	0.0187
GC vs. TH	-72.27	0.024

TH=Thermafil®; WV=Warm Vertically compacted gutta-percha; GCP=GuttaCore Pink®

Table 4 Dunn's test T2 variable

Comparing groups	Mean difference	$p$ -value Dunn's test
WV vs. GC	-2.92	0.4887
WV vs. TH	-56.79	0.0049
GC vs. TH	-53.87	0.0059

TH=Thermafil®; WV=Warm Vertically compacted gutta-percha; GCP=GuttaCore Pink®

Table 5 The descriptive statistics of the area variable in the treatment groups

Group	Samples number	Mean area (mm <sup>2</sup> )	Minimum area (mm <sup>2</sup> )	Maximum area (mm <sup>2</sup> )	Standard deviation
TH	15	0.21	0	0.88	0.32295941
WV	15	0.30	0	1.27	0.39928141
GCP	15	0.42	0	2.11	0.6392836

TH=Thermafil<sup>®</sup>; WV=Warm Vertically compacted gutta-percha; GCP=GuttaCore Pink<sup>®</sup>

percha technique has mean T1 values that are smaller than Thermafil<sup>®</sup> and the result is significant even if the *p*-value is very close to the limit.

- GuttaCore Pink<sup>®</sup>-Thermafil<sup>®</sup>: the GuttaCore Pink<sup>®</sup> technique has significantly lower values of T1 than Thermafil<sup>®</sup>.

## 2. T2 variable

Concerning variable T2 (Tables 2–4), the *p*-value is not significant for the Warm Vertically compacted gutta-percha-GuttaCore Pink<sup>®</sup> pair, so there is no mean difference for what concerns variable T2, while for the other two pairs, there is a *p*-value that is significant, so we can say that GuttaCore Pink<sup>®</sup> and Warm Vertically compacted gutta-percha have mean values of T2 significantly lower than Thermafil<sup>®</sup>.

### Results of the analysis of surface area of the remaining gutta-percha

Concerning the variable surface area (Table 5, Fig. 2), we summed the area of the sample A with the area of the sample B, since they correspond to the same sample divided into two parts.

Basically, Sample A and B represent half of each root. The root being divided into 2 to generates 2 sub-samples, which are named A and B. Therefore, both are added as part of the same sample.

## 1. Area variable

The descriptive statistics of the variable surface area in the treatment groups are summarized in the Table 5. The same procedures of the time variable T1 and T2 have been performed:

- Normality Assumption: violated (Shapiro-Wilks test with *p*-value<0.05)
- Hypothesis of homoscedasticity: accepted (Levene's test with *p*-value>0.05) (it means that the variance can be compared.)

So even in this case a non-parametric ANOVA homoscedastic was carried out, and the result of the Kruskal-Wallis test is not significant with a *p*-value=0.9028 (>0.05). Having found no significant difference, the Dunn's test was considered not necessary.

## DISCUSSION

In an orthograde root canal retreatment, it is necessary to remove the filling material from the root canal system in order to correctly address deficiency in cleaning, shaping and filling.

Takahashi *et al.*<sup>9)</sup> in their study demonstrated that all the retreatment techniques, using manual and rotary instruments have proved to be effective in the removal of the filling material and do not differ significantly from each other. However, concerning the speed in the retreatment of obturated canals, the PTUR without the aid of chloroform, have been proved to be faster than the manual instrumentation when used with the chloroform<sup>9)</sup>. It probably depends on the plasticity of the gutta-percha, as consequence of the rotation of the instrument, which causes a high temperature increase<sup>6)</sup>.

The soft gutta-percha is less resistant and easier to be removed<sup>7)</sup>. Moreover, according to Tasdemir *et al.*<sup>16)</sup> the use of rotary NiTi instruments could reduce working time. Giuliani *et al.*<sup>8)</sup> have found that PTURs are more effective in cleansing the canal walls compared to Profile and the manual files such as Hedstroem.

In this study all the retreatments were performed with PTUR without the aid of any solvent. Once the working length was reached with the D3, the removal of remaining gutta-percha was performed in a second step with a PTU F4, 0.40 mm-diameter, in order to enlarge, finish and clean the initial apical diameter that was 0.30 mm. The enlargement of the apical diameter was performed in accordance with the study of Hassanloo *et al.*<sup>17)</sup>, which noted that the amount of filling material residue inside the canal after a retreatment would be reduced when the apical preparation was greater than the previous size.

During the first phase of the retreatment (T1) there were no separations of PTUR, while a perforation of an obturated sample with Warm Vertically compacted gutta-percha occurred. Basically, the sample in which there was perforation had a lower curvature radius than most of the other samples.

The PTUR were used at 500 rpm, according to<sup>9,18,19)</sup>, and they were replaced with new instruments, if signs of deformation of the blades appeared.

During the second phase of the retreatment (T2) Two PTU F4 separated, both during the retreatment of two Thermafil<sup>®</sup> samples and always at the level of the

apical third where even the plastic carrier fractured during the T1 phase.

This event might suggest that the fracture of the plastic carrier would complicate the removal procedure. In fact, the plastic carrier would increase the torsional stress and the cyclic fatigue of the instruments compared to GuttaCore Pink®. Hayakawa *et al.*<sup>18)</sup> state that there may be different variables affecting on removal efficiency, such as the type of carrier, the type of cement used and the sectioning of the carrier, which should be considered as a complication.

Although it is not statistically possible to say that the two separations are due exclusively to the methodology applied, we can evaluate the separation as a further confirmation of the results obtained with the statistical timing analysis. So, the GuttaCore Pink® and Warm Vertically compacted gutta-percha techniques could be easier to retreat than Thermafil®.

Wilcox and Juhlin<sup>3)</sup> claim that success in the retreatment of obturated canals with Thermafil® depends primarily on the ability to remove the carrier, more than on the technique used to remove the gutta percha.

The manufacturer claims that as the GuttaCore Pink® possesses a rigid central core, composed by cross-linked gutta-percha, it is not affected by the heat of the oven and it is easier to remove than the previous systems based on plastic or metal carrier<sup>20)</sup>.

In accordance with the manufacturer, in our conditions the GuttaCore Pink® was significantly quicker to be removed from the canal compared to Thermafil®. Concerning instead the comparison between GuttaCore Pink® and Warm Vertically compacted gutta-percha, the GuttaCore Pink® is found to be better but not in a significant way.

The GuttaCore Pink® system could therefore be considered as a valid alternative to Thermafil®, especially in the removal of the handle and in the preparation of the post-space. Li *et al.*<sup>21)</sup> showed that the obturation system GuttaCore® is a valid alternative to warm-gutta-percha with vertical condensation technique, as they have not found significant differences between the two systems.

Therefore, we point out that GuttaCore Pink® system is easier to be removed when compared to the Thermafil®, when a Ni-Ti rotating instrument is used up to the working length. Our results complement the studies on the previous GuttaCore®<sup>12,13)</sup>. The second objective of our study was to compare the number of residues of gutta-percha in the apical third, more precisely in the last 6 mm, because as stated by Hulsmann and Bluhm<sup>6)</sup> the apical third of the canal would be the area in which there is a greater number of residues of gutta-percha. In order to satisfy this analysis, the samples were sectioned, and an image of the canal was taken under the microscope, as in previous studies<sup>9,13,22)</sup>.

The longitudinal cut of the sample was more effective for detecting the filling remaining inside the canal than the X-ray technique, because the X-rays offer two-dimensional images of a three-dimensional structure and can be subject to magnification and distortion<sup>22)</sup>.

The statistical analysis of the areas of gutta percha

inside the canal after retreatment, shows that Thermafil® group has a minor number of residues in the apical third compared to the Warm Vertical compaction group and especially to the GuttaCore Pink® group, although the difference is not statistically significant. This is also in accordance with the paper of<sup>13,15)</sup> on the previous GuttaCore®.

## CONCLUSION

Within the limitations of our study, our data show that the GuttaCore Pink® can be removed from the root canal system in a shorter time when compared to the Thermafil®; the results are in accordance with literature on the previous GuttaCore®, without the GuttaCore® problems on fractures during the introduction within the canal. Conversely, there is no significant difference between GuttaCore Pink® and the Warm Vertically compacted gutta-percha. Concerning the amount of gutta-percha left in the last 6 mm of the canal, there are no significant differences between the three obturation systems investigated in this study.

## REFERENCES

- 1) Selehrabi R, Rotstein I. Epidemiologic evaluation of outcomes of orthograde endodontic retreatment. *J Endod* 2010; 36: 790-792.
- 2) Wong R. Conventional endodontic failure and retreatment. *Dent Clin North Am* 2004; 48: 265-289.
- 3) Wilcox L, Juhlin J. Endodontic retreatment of Thermafil versus laterally condensed gutta-percha. *J Endod* 1994; 20: 115-117.
- 4) Viducic D, Jukic S, Karlovic Z, Bozic Z, Miletic I, Anic I. Removal of gutta-percha from root canals using an Nd:YAG laser. *Int Endod J* 2003; 36: 670-673.
- 5) Hammad M, Qualtrough A, Silikas N. Three-dimensional evaluation of effectiveness of hand and rotary instrumentation for retreatment of canals filled with different materials. *J Endod* 2008; 34: 1370-1373.
- 6) Hulsmann M, Bluhm V. Efficacy, cleaning ability and safety of different rotary NiTi instruments in root canal retreatment. *Int Endod J* 2004; 37: 468-476.
- 7) Bramante C, Betti L. Efficacy of Quantec rotary instruments for gutta-percha removal. *Int Endod J* 2000; 33: 463-467.
- 8) Giuliani V, Cocchetti R, Pagavino G. Efficacy of ProTaper universal retreatment files in removing filling materials during root canal retreatment. *J Endod* 2008; 34: 1381-1384.
- 9) Takahashi CM, Cunha RS, de Martin AS, Fontana CE, Silveira CF, da Silveira Bueno CE. In vitro evaluation of the effectiveness of ProTaper universal rotary retreatment system for gutta-percha removal with or without a solvent. *J Endod* 2009; 35: 1580-1583.
- 10) Whithorth J. Methods of filling root canals: principles and practices. *Endod Topics* 2005; 12: 2-24.
- 11) Johnson W. A new gutta-percha technique. *J Endod* 1978; 4: 184-188.
- 12) Beasley RT, Williamson AE, Justman BC, Qian F. Time required to remove guttacore, thermafil plus, and thermoplasticized gutta-percha from moderately curved root canals with protaper files. *J Endod* 2013; 39: 125-128.
- 13) Nevaes G, de Albuquerque DS, Bueno CE, Cunha RS. Is guttacore more easily removed from the root canal than thermafil? an ex-vivo study. *J Can Dent Assoc* 2015; 81: f22.
- 14) Endal U, Shen Y, Ma J, Yang Y, Haapasalo M. Evaluation

- of quality and preparation time of retrograde cavities in root canals filled with guttacore and cold lateral condensation technique. *J Endod* 2018; 44: 639-642.
- 15) Rödiger T, Wagner J, Wiegand A, Rizk M. Efficacy of the ProTaper retreatment system in removing Thermafil, GuttaCore or vertically compacted gutta-percha from curved root canals assessed by micro-CT. *Int Endod J* 2018; 51: 808-815.
  - 16) Taşdemir T, Er K, Yildirim T, Celik D. Efficacy of three rotary NiTi instruments in removing gutta-percha from root canals. *Int Endod J* 2008; 41: 191-196.
  - 17) Hassanloo A, Watson P, Finer Y, Friedman S. Retreatment efficacy of the Epiphany soft resin obturation system. *Int Endod J* 2007; 40: 633-643.
  - 18) Hayakawa T, Tomita F, Okiji T. Influence of the diameter and taper of root canals on the removal efficiency of Thermafil Plus plastic carriers using ProTaper Retreatment Files. *J Endod* 2010; 36: 1676-1678.
  - 19) Huang X, Ling J, Wei X, Gu L. Quantitative evaluation of debris extruded apically by using ProTaper Universal Tulsa rotary system in endodontic retreatment. *J Endod* 2007; 33: 1102-1105.
  - 20) Whitten RB, Levitan ME. The effect of canal preparation on fill length in straight root canals obturated with GuttaCore. *J Endod* 2015; 41: 155-156.
  - 21) Li GH, Niu LN, Selem LC, Eid AA, Bergeron BE, Chen JH, *et al.* Quality of obturation achieved by an endodontic core-carrier system with crosslinked gutta-percha carrier in single-rooted canals. *J Dent* 2014; 42: 1124-1134.
  - 22) Marques da Silva B, Baratto-Filho F, Leonardi DP, Henrique Borges A, Volpato L, Branco Barletta F. Effectiveness of ProTaper, D-RAce, and Mtwo retreatment files with and without supplementary instruments in the removal of root canal filling material. *Int Endod J* 2012; 45: 927-932.