



## Standardisation of nailfold capillaroscopy for the assessment of patients with Raynaud's phenomenon and systemic sclerosis



Vanessa Smith<sup>a,b,c,\*,1</sup>, Ariane L. Herrick<sup>d,e,1</sup>, Francesca Ingegnoli<sup>f,g,1</sup>, Nemanja Damjanov<sup>h</sup>, Rossella De Angelis<sup>i</sup>, Christopher P. Denton<sup>j</sup>, Oliver Distler<sup>k</sup>, Karinna Espejo<sup>l</sup>, Ivan Foeldvari<sup>m</sup>, Tracy Frech<sup>n</sup>, Boris Garro<sup>l</sup>, Marwin Gutierrez<sup>o</sup>, Genevieve Gyger<sup>p</sup>, Eric Hachulla<sup>q</sup>, Roger Hesselstrand<sup>r</sup>, Annamaria Iagnocco<sup>s</sup>, Cristiane Kayser<sup>t</sup>, Karin Melsens<sup>a,b</sup>, Ulf Müller-Ladner<sup>u</sup>, Sabrina Paolino<sup>v</sup>, Carmen Pizzorni<sup>v</sup>, Mislav Radic<sup>w</sup>, Valeria Ricciari<sup>x</sup>, Marcus Snow<sup>y</sup>, Wendy Stevens<sup>z</sup>, Alberto Sulli<sup>v</sup>, Jacob M. van Laar<sup>aa</sup>, Madelon C. Vonk<sup>bb</sup>, Amber Vanhaecke<sup>a,b</sup>, Maurizio Cutolo<sup>v</sup>, the EULAR Study Group on Microcirculation in Rheumatic Diseases and the Scleroderma Clinical Trials Consortium Group on Capillaroscopy

<sup>a</sup> Department of Internal Medicine, Ghent University, Ghent, Belgium

<sup>b</sup> Department of Rheumatology, Ghent University Hospital, Ghent, Belgium

<sup>c</sup> Unit for Molecular Immunology and Inflammation, VIB Inflammation Research Center (IRC), Ghent, Belgium

<sup>d</sup> Division of Musculoskeletal & Dermatological Sciences, The University of Manchester, Salford Royal NHS Foundation Trust, Manchester, UK

<sup>e</sup> NIHR Manchester Biomedical Research Centre, Manchester University NHS Foundation Trust, Manchester Academic Health Science Centre, Manchester, UK

<sup>f</sup> Department of Clinical Sciences and Community Health, University of Milan, Milan, Italy

<sup>g</sup> Division of Rheumatology, ASST G. Pini, Milan, Italy

<sup>h</sup> Institute of Rheumatology, University of Belgrade Medical School, Belgrade, Serbia

<sup>i</sup> Department of Clinical and Molecular Sciences, Rheumatology Unit, Carlo Urbani Hospital, Polytechnic University of Marche, Jesi, Ancona, Italy

<sup>j</sup> Department of Rheumatology, University College London, Royal Free Hospital, London, UK

<sup>k</sup> Department of Rheumatology, University Hospital Zurich, Zurich, Switzerland

<sup>l</sup> Universidad Peruana De Ciencias Aplicadas (UPC), Centro de Excelencia en Reumatología (CER-PERU), Lima, Peru

<sup>m</sup> Centre for Paediatric and Adolescent Rheumatology, Hamburg, Germany

<sup>n</sup> Department of Rheumatology, University of Utah, Salt Lake City, Utah, USA

<sup>o</sup> Division of Musculoskeletal and Rheumatic Disorders, Instituto Nacional de Rehabilitación, Mexico City, Mexico

<sup>p</sup> Division of Rheumatology, Jewish General Hospital, Department of Medicine, McGill University, Montreal, Quebec, Canada

<sup>q</sup> Univ. Lille, CHU Lille, Département de Médecine Interne et Immunologie Clinique, Centre de Référence des Maladies Systémiques et Auto-Immunes Rares du Nord-Ouest (CERAINO), LIRIC, INSERM, Lille, France

<sup>r</sup> Department of Rheumatology, Skåne University Hospital, Lund University, Lund, Sweden

<sup>s</sup> Academic Rheumatology Center, Department of Clinical and Biological Science, University of Turin, Turin, Italy

<sup>t</sup> Rheumatology Division, Escola Paulista de Medicina, Universidade Federal de São Paulo, São Paulo, Brazil

<sup>u</sup> Department of Rheumatology and Clinical Immunology, Justus-Liebig University of Giessen, Campus Kerckhoff, Bad Nauheim, Germany

<sup>v</sup> Research Laboratory and Academic Division of Clinical Rheumatology, Department of Internal Medicine, University of Genoa, IRCCS San Martino Polyclinic Hospital, Genoa, Italy

<sup>w</sup> Division of Rheumatology and Clinical Immunology, University Hospital Split, Split, Croatia

**Abbreviations:** ACR, American College of Rheumatology; ANA, anti-nuclear antibody; CTD, connective tissue disease; DM, dermatomyositis; EULAR, European League Against Rheumatism; EULAR SG MC/RD, EULAR Study Group on Microcirculation in Rheumatic Diseases; ICC, intra-class correlation coefficient; MES, microangiopathy evolution score; MCTD, mixed connective tissue disease; NVC, nailfold videocapillaroscopy; RP, Raynaud's phenomenon; SDS, scleroderma spectrum; SLE, systemic lupus erythematosus; SSc, systemic sclerosis; UCTD, undifferentiated connective tissue disease; VEDOSS, very early diagnosis of systemic sclerosis

\* Corresponding author at: Department of Rheumatology, Ghent University Hospital, Corneel Heymanslaan 10, 9000 Ghent, Belgium.

**E-mail addresses:** [vanessa.smith@ugent.be](mailto:vanessa.smith@ugent.be) (V. Smith), [ariane.herrick@manchester.ac.uk](mailto:ariane.herrick@manchester.ac.uk) (A.L. Herrick), [francesca.ingegnoli@unimi.it](mailto:francesca.ingegnoli@unimi.it) (F. Ingegnoli), [nemanjadamjanov@yahoo.com](mailto:nemanjadamjanov@yahoo.com) (N. Damjanov), [rossella.deangelis@sanita.marche.it](mailto:rossella.deangelis@sanita.marche.it) (R. De Angelis), [c.denton@medsch.ucl.ac.uk](mailto:c.denton@medsch.ucl.ac.uk) (C.P. Denton), [oliver.distler@usz.ch](mailto:oliver.distler@usz.ch) (O. Distler), [krev76@gmail.com](mailto:krev76@gmail.com) (K. Espejo), [foeldvari@t-online.de](mailto:foeldvari@t-online.de) (I. Foeldvari), [tracy.frech@hsc.utah.edu](mailto:tracy.frech@hsc.utah.edu) (T. Frech), [bgarrob1@gmail.com](mailto:bgarrob1@gmail.com) (B. Garro), [dr.gmarwin@gmail.com](mailto:dr.gmarwin@gmail.com) (M. Gutierrez), [genygyger@hotmail.com](mailto:genygyger@hotmail.com) (G. Gyger), [ehachulla2@yahoo.fr](mailto:ehachulla2@yahoo.fr) (E. Hachulla), [roger.hesselstrand@med.lu.se](mailto:roger.hesselstrand@med.lu.se) (R. Hesselstrand), [annamaria.iagnocco1@gmail.com](mailto:annamaria.iagnocco1@gmail.com) (A. Iagnocco), [cristiane.kayser@unifesp.br](mailto:cristiane.kayser@unifesp.br) (C. Kayser), [karin.melsens@ugent.be](mailto:karin.melsens@ugent.be) (K. Melsens), [u.mueller-ladner@kerckhoff-klinik.de](mailto:u.mueller-ladner@kerckhoff-klinik.de) (U. Müller-Ladner), [sabrina.paolino@unige.it](mailto:sabrina.paolino@unige.it) (S. Paolino), [carmen.pizzorni@unige.it](mailto:carmen.pizzorni@unige.it) (C. Pizzorni), [mislavradic@gmail.com](mailto:mislavradic@gmail.com) (M. Radic), [valeria.ricciari@uniroma1.it](mailto:valeria.ricciari@uniroma1.it) (V. Ricciari), [msnow@unmc.edu](mailto:msnow@unmc.edu) (M. Snow), [wendy.stevens@bigpond.com](mailto:wendy.stevens@bigpond.com) (W. Stevens), [albertosulli@unige.it](mailto:albertosulli@unige.it) (A. Sulli), [j.m.vanlaar@umcutrecht.nl](mailto:j.m.vanlaar@umcutrecht.nl) (J.M. van Laar), [madelon.vonk@radboudumc.nl](mailto:madelon.vonk@radboudumc.nl) (M.C. Vonk), [amber.vanhaecke@ugent.be](mailto:amber.vanhaecke@ugent.be) (A. Vanhaecke), [mcutolo@unige.it](mailto:mcutolo@unige.it) (M. Cutolo).

<https://doi.org/10.1016/j.autrev.2020.102458>

Available online 10 January 2020

1568-9972/ © 2020 The Authors. Published by Elsevier B.V. This is an open access article under the CC BY-NC-ND license (<http://creativecommons.org/licenses/by-nc-nd/4.0/>).

<sup>x</sup> Department of Internal Medicine and Medical Specialties, Sapienza University of Rome, Rome, Italy

<sup>y</sup> Department of Internal Medicine, Division of Rheumatology, University of Nebraska Medical Center, Omaha, NE, USA

<sup>z</sup> Department of Rheumatology, St Vincent's Hospital, Melbourne, Victoria, Australia

<sup>aa</sup> Department of Rheumatology and Clinical Immunology, University Medical Center Utrecht, Utrecht, The Netherlands

<sup>ab</sup> Department of Rheumatology, Radboud University Medical Center, Nijmegen, The Netherlands

## ABSTRACT

Capillaroscopy is a non-invasive and safe tool which allows the evaluation of the morphology of the microcirculation. Since its recent incorporation in the 2013 American College of Rheumatology (ACR)/European League Against Rheumatism (EULAR) classification criteria for systemic sclerosis together with its assessed role to monitor disease progression, capillaroscopy became a 'mainstream' investigation for rheumatologists. Given its increasing use by a variety of physicians internationally both in daily practice to differentiate primary from secondary Raynaud's phenomenon, as well as in research context to predict disease progression and monitor treatment effects, standardisation in capillaroscopic image acquisition and analysis seems paramount. To step forward to this need, experts in the field of capillaroscopy/microcirculation provide in this very consensus paper their view on image acquisition and analysis, different capillaroscopic techniques, normal and abnormal capillaroscopic characteristics and their meaning, scoring systems and reliability of image acquisition and interpretation.

## 1. Introduction

Structural microvascular abnormalities are one of the key features of systemic sclerosis (SSc) related to the pathophysiological process and can be visualised non-invasively using the technique of nailfold capillaroscopy. This is because at the nailfold, capillaries run parallel rather than perpendicular to the skin surface and so their structure can be demonstrated [1]. Sometimes the capillaries are so abnormally altered that they can be seen with the naked eye (see Fig. 1), although magnification is usually required. The capillary walls themselves are invisible: what is seen is the column of red blood cells within the capillary.

Nailfold capillaroscopy is now a 'mainstream' investigation for rheumatologists, because (as discussed below) a "scleroderma pattern" helps to differentiate primary from secondary Raynaud's phenomenon (RP). "Abnormal nailfold capillaries" (when referring to the "scleroderma pattern") are included in the 2013 American College of Rheumatology (ACR)/ European League Against Rheumatism (EULAR) classification criteria for SSc, scoring two points out of the nine required for classification [2,3].

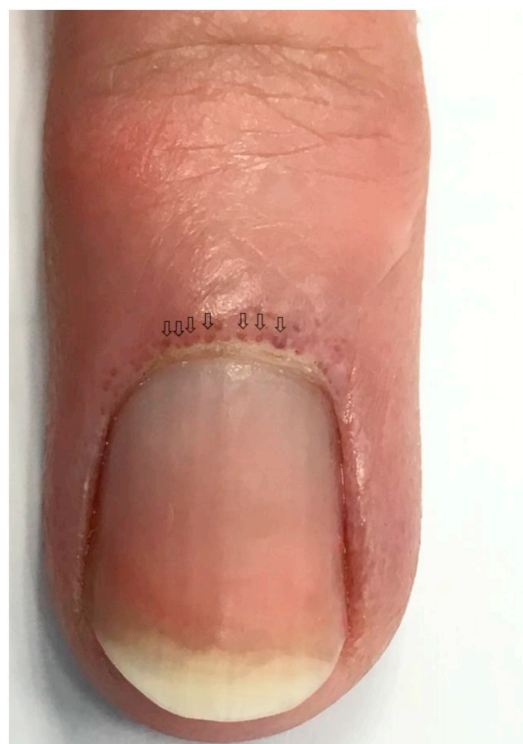With the increasing use of nailfold capillaroscopy internationally, it is important to have consensus concerning methods of acquiring and analysing nailfold capillaries, as well as having clarity concerning what the terminology "abnormal" means. After giving a brief background to the development of nailfold capillaroscopy as a diagnostic tool, this paper gives a consensus view from experts in capillaroscopy/microcirculation on image acquisition and analysis, different capillaroscopic techniques, normal and abnormal capillaroscopic characteristics and their meaning, scoring systems and reliability of image acquisition and interpretation.

## 2. Background and history

Readers interested in a full history of the development of capillaroscopy are referred to a chapter by Cutolo [4]. For rheumatologists, particularly for those with an interest in SSc, the story begins in the 1970s, with the seminal work by Maricq et al. on capillaroscopy in connective tissue diseases (CTDs) [5–7]. Maricq used a wide-field microscope (magnification in the order of 12×) which allows a view of the whole nailfold. The key abnormalities of a "scleroderma pattern" include widened capillaries, avascularity ("loop drop-out"), haemorrhages and distortion of the normal capillary architecture [5,6]. One of the factors leading to increasing interest in capillaroscopy in the 1990s was the development of high magnification videocapillaroscopy, which

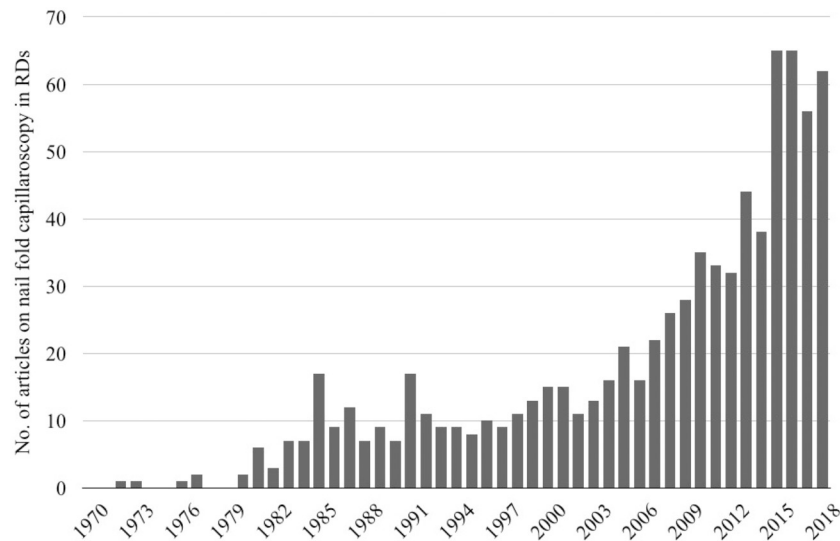
typically uses magnifications in the order of 200×.

Since the 1990s, capillaroscopy has continued to gain momentum in both clinical practice and research [8]. For the clinician, its main application is early identification of an underlying scleroderma spectrum (SDS) disorder in the patient presenting with RP [9–11]. Since 2004, EULAR training courses have been held on alternate years and have been oversubscribed, demonstrating the increased interest in capillaroscopy and training need. A recent survey amongst clinicians with an interest in SSc demonstrated that most respondents used nailfold videocapillaroscopy (NVC) in their everyday clinical practice [12]. From the research perspective, increasing numbers of publications



**Fig. 1.** Non-magnified picture of an abnormal nailfold. Non-magnified picture of an abnormal nailfold to show that specific abnormalities can sometimes even be detected with the unassisted eye. More specifically, a specific abnormality of the following capillaroscopic characteristic: "capillary dimension", i.e. giant capillaries can be seen with the naked eye (∩ "giants").

<sup>1</sup> These authors contributed equally to this study.



**Fig. 2.** Number of articles published on nailfold capillaroscopy in rheumatic diseases.

Full articles published from 1970 to 2018 were retrieved from PubMed using the search word “nailfold capillaroscopy”. Only articles on rheumatic diseases are represented in the graph.

reflect a large number of different areas of research (see Fig. 2), including associates of abnormal nailfold capillary characteristics; “scleroderma patterns” as a predictor of disease (e.g. of digital ulceration) [13–15] and reliability of image acquisition and interpretation [16–22]. Establishing reliability of different qualitative and quantitative nailfold parameters is especially important if nailfold capillaroscopy is to be used as an outcome measure in clinical trials (see “5. Scoring Systems”).

### 3. Capillaroscopy equipment

Different devices can be used to perform capillaroscopy, as it is an *in vivo* imaging investigation that consists of a magnified view of the structural aspects of the nailfold microcirculation. The commercially available tools range from the wide-field microscope and videocapillaroscope to smartphone devices and are characterized by different portability, costs, training period and image quality (see Table 1). The research tools will be discussed in section “5. Scoring Systems”.

In the seventies, Maricq described the presence of specific pathologic capillary abnormalities in patients with SDS disorders using wide-field microscopy [5,6,23]. To this purpose, a photomicrography system, made-up by a stereomicroscope connected with a reflex camera with good optical resolution (photos were developed with 3–4× magnification on the negative), was used [6]. This device is quite expensive and needs a longer training time than other devices due to difficulties in maintaining an optimal relationship between release times, field lighting, the presence of micro-movements of the patient's hand and reflections generated by the incidental light strip [5,6,23]. Nailfold stereomicroscopy allows physicians to see the whole nailfold area almost in a single frame and it is useful for a quick panoramic view of the entire microvascular network. The overall pattern is easily interpreted because in the wide-field view, overt capillary abnormalities are contrasted with surrounding normal areas. By contrast, the wide-field view cannot be easily used to analyse capillary details and apply measuring features, even though quantitative seminal studies have been performed (see also Supplementary File 1) [7,16].

Shortly thereafter, the ophthalmoscope has been proposed as an everyday instrument to extend the use of nailfold capillaroscopy in clinical practice [24,25]. Due to its low cost and good portability, it may be available to all physicians at the bedside or in the clinic [25]. It has been demonstrated that major capillary abnormalities related to SDS disorders can be detected with both the ophthalmoscope and

stereomicroscope [26–28]. On the other hand, the ophthalmoscope is not suitable for research purposes as images cannot be stored and analysed.

The dermatoscope, which is easier to use than the ophthalmoscope, is considered an appropriate device to perform nailfold capillaroscopy and is purchasable at reasonable cost [12]. Even though a higher percentage of images are not classifiable by the dermatoscope, the inter- and intra-rater reliability are comparable to NVC [27,29–33]. Hence experts agree it can be used to identify capillary abnormalities, which may be corroborated in a second step by NVC (see Fig. 3). Also, recently, nailfold dermatoscopy has been proposed as part of the rheumatology fellow curriculum in the USA [34].

Smartphones have an embedded digital camera that can be adapted for capillaroscopy, via the use of an adapted dermatoscope or macro-photography lens. Recently, the performance of the smartphone-dermatoscope and smartphone-lens was tested [35]. Both tools are novel and relatively inexpensive portable devices which performed acceptably, even in the hands of a novice. In this way they had a high specificity but a lower sensitivity than the wide-field microscope to discern “non-scleroderma” from “scleroderma patterns” [35]. Of note, the dermatoscope and the smartphone may be used as screening tools when the gold standard, the NVC is not available.

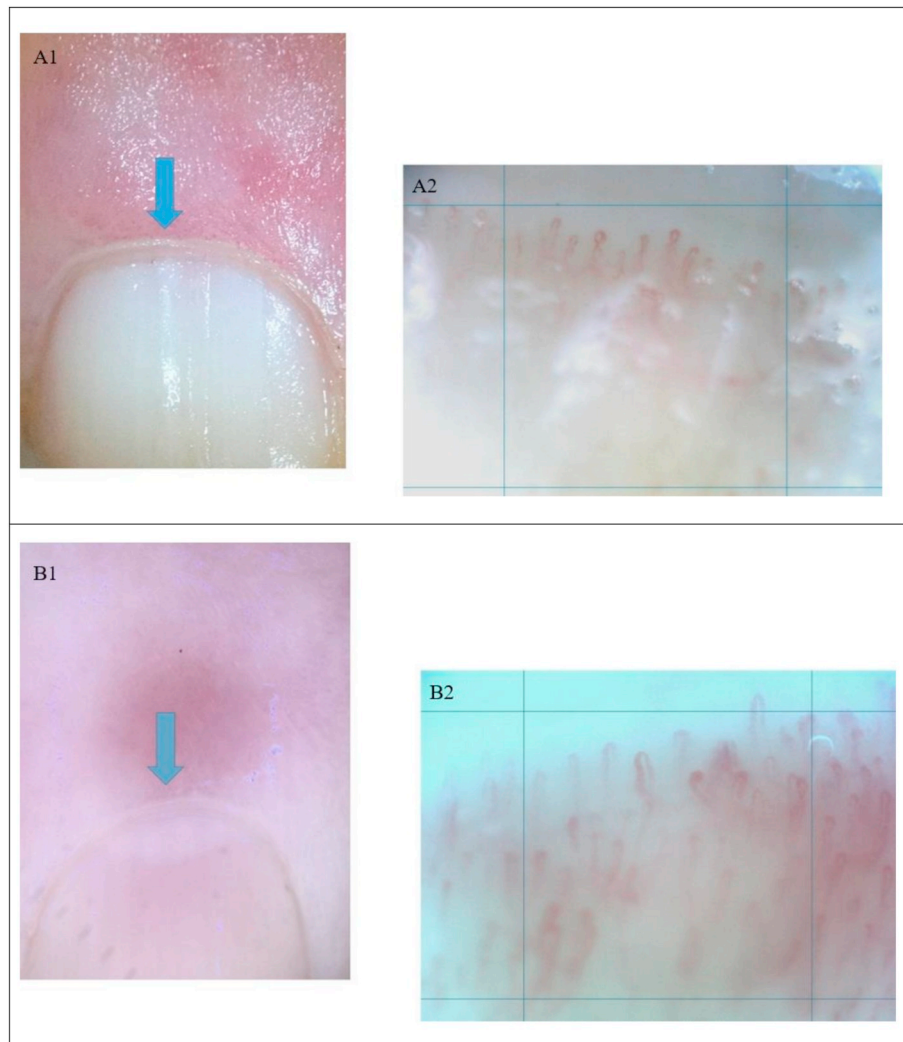
Digital USB microscopy is considered another useful tool to perform nailfold capillaroscopy, and the probe can be connected with a laptop allowing image storage. Because of simplicity of the equipment the training period is brief. The digital USB microscope can be used in clinical practice, but not at present in a research setting because software for measuring capillary density and dimensions is not commercially available [12].

The gold standard device is the digital videocapillaroscope that combines a microscope with a digital video camera. At this moment, it is the only tool which has attested the ability to be trained in such a way that capillaroscopists of any level of experience can classify images as “scleroderma pattern” or not, as well as a principal expert [22]. The high sensitivity of the camera and the co-axial illumination of the field allow images of high-resolution quality to be obtained. Moreover, digital filters such as grey scale, watershed and top-hat filters can be applied to separate the relevant areas from image background. Magnification can range between 50× and 500×, but the most used is the 200× magnification. The commercially available videocapillaroscope is able to store and analyse each single frame separately. To have a wider view of the nailfold area using frame registration, an innovative

**Table 1**  
Pros and cons of different capillaroscopic devices.

	Training duration	Image quality	Magnification	Image storage	Software for image analysis	Costs	Portability	Clinical practice	Research setting	Reliability
Stereomicroscopy (= wide-field microscopy)	Variable, depending on the image capturing system	Variable, depending on the image capturing system	Ranging between 10 and 200×	Possible; Depending on the image capturing system	NT	Medium to high	Not practical	Yes, but difficult to examine patients with flexion contractures	Yes, if it is connected to a computer with software analysis	Good
Ophthalmoscopy	Short, easy to use	Variable, depending on the magnification lens	Up to 15×	Not possible	NT	Low	Very good	Yes	No, no possibility of image storage and analysis	Good
Dermatoscopy	Short, easy to use	Variable, depending on the magnification lens	Up to 10×	Possible if attached to a camera	NT	Low to medium	Very good	Yes	No, no specific software	Good
Smartphone devices	Short, easy to use	Variable, depending on the magnification lens	Up to 20×	Possible	NT	Low	Very good	Yes	No, no control of the used magnification and lacking specific software	Good
Digital USB microscopy	Short, easy to use	Variable, depending on the quality of the probe	Up to 300×	Possible	NT	Low to medium	Good, the probe can be connected to a laptop	Yes	Yes, when adding image analysis software	NT
Digital videocapillaroscopy	Short, easy to use	Good	Ranging between 50 and 500×; However, 200× magnification is most frequently used	Possible; image storage and reproduction are highly reliable	Advanced image analysis and ability to produce medical reports	High	Good, if the probe can be connected to a laptop	Yes	Yes	Good

NT: not tested.



**Fig. 3.** Examples of capillaroscopic images obtained with a dermatoscope versus a nailfold videocapillaroscope.

The dermatoscope is a useful tool to detect capillary abnormalities, however uncertainty may arise when images are unclassifiable as a “scleroderma pattern” or not (A1, B1) or when there are changes in capillary density or capillary dimension (C1). In these cases, it is opportune to move on to the nailfold videocapillaroscope, which can give certainty (A2, B2, C2). Image D1 and D2 are pictures of easily recognisable “scleroderma patterns” both on the dermatoscope (D1) as well as on the nailfold videocapillaroscope (D2).

software that combines adjacent images has been designed in order to build up a panoramic “mosaic” of the entire nailfold at  $300\times$  magnification [36]. The videocapillaroscope is currently considered the most appropriate device for clinical and research purposes [12]. However, videocapillaroscopes are generally relatively expensive and consequently access to them is largely restricted to centres with a special interest in the area.

Measuring different capillaroscopic characteristics is fundamental for research studies (see below). At present, manual or semi-manual image analysis is time-consuming. To overcome this problem, software for automated or semi-automated analysis of nailfold capillaroscopic images is under evaluation (see “5. Scoring Systems”) [37–42]. These computerized systems may, in the near future, offer additional benefits such as the possibility of frame registration software [36], a much faster analysis and extremely precise measurements [37–42].

#### 4. Normality and abnormality

The NVC technique with  $200\times$  magnification, capturing at least two adjacent fields of 1 mm in the middle of the nailfold finger, is the gold standard capillaroscopic technique to perform nailfold capillaroscopy [1]. With NVC, images can be assessed qualitatively or (semi-

quantitatively. In qualitative assessment “overall pattern recognition” is being performed and images can be classified as “scleroderma pattern” or not [22]. In quantitative assessment capillary characteristics can be evaluated per unit of quantity (e.g. per linear mm). The following capillary characteristics can be evaluated when assessing an image: capillary density (number of capillaries), capillary morphology (shape of individual capillaries), capillary dimension (width of the apical limb of the capillary) and presence/absence of haemorrhages (see Table 2) [22,43–45]. Each capillaroscopic characteristic has a “normal” range (see Supplementary File 1). Certain characteristic capillaroscopic abnormalities or a combination of certain characteristic capillaroscopic abnormalities are specific to the “scleroderma pattern”. More specifically the presence of giant capillaries (“giants”, i.e. capillaries with an apical diameter  $\geq 50\ \mu\text{m}$ ) or the combination of abnormal shapes with an extremely lowered number of capillaries points to a “scleroderma pattern” (see below) [22,46]. Besides the “scleroderma patterns”, a variety of “non-scleroderma patterns” exists (i.e. stereotype “normal” or “non-specific abnormalities”), which can occur in healthy individuals or in CTDs other than SSc and may be a challenge to the non-experienced capillaroscopist (see Table 2 and Fig. 4) [45].

Of note, different definitions have been used to describe abnormal capillary morphology (e.g. “ramifications”, “neovascularisation” or

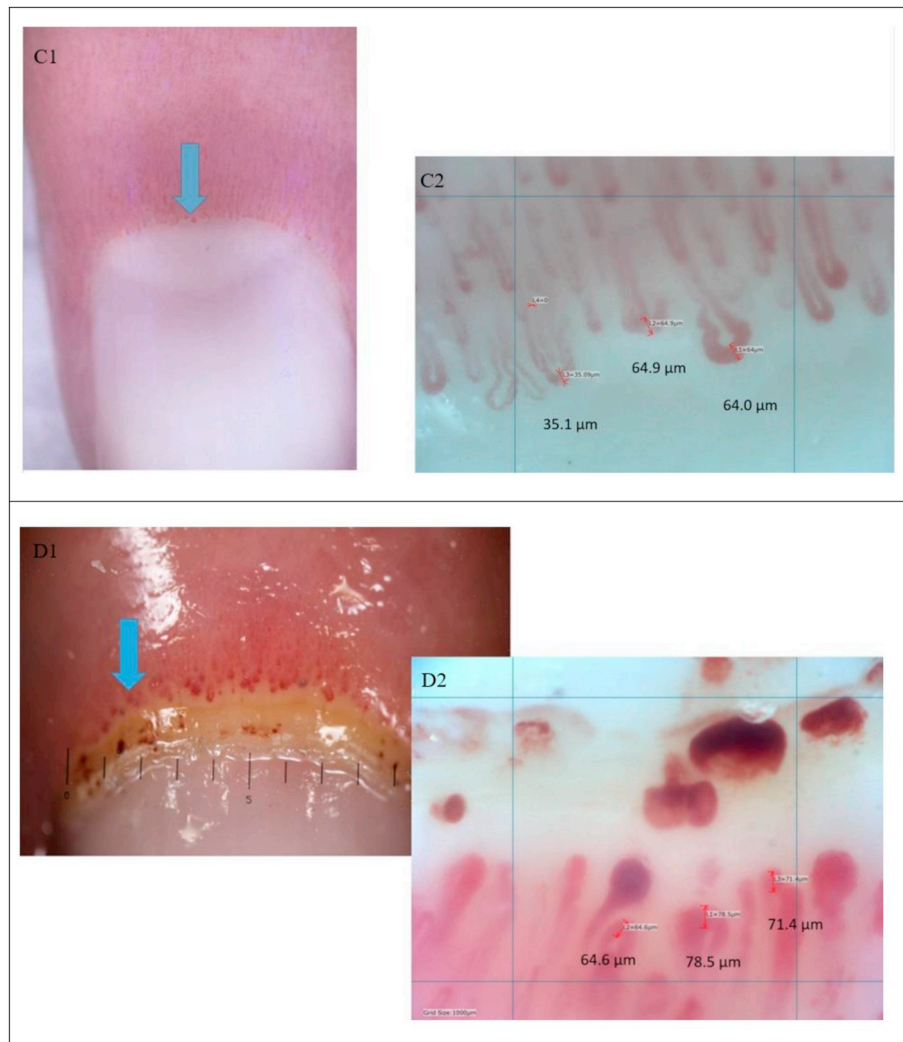


Fig. 3. (continued)

“meandering”) with low reliability [17,47]. To avoid confusion, the EULAR Study Group on Microcirculation in Rheumatic Diseases (EULAR SG MC/RD) has published by consensus a simple definition to evaluate a single capillary as “(ab)normal”, adoptable to all rheumatic diseases and capillaroscopic evaluations with the aim to have a standardized interpretation [48,49]. Capillaries with a “hairpin” shape, (once or twice) crossing shape or tortuous shape (the afferent and efferent limb bend [= undulate] but do not cross) are defined as being “normal”, on the condition that the tip of the capillary is convex (see Table 2) [47–49]. All other shapes are defined as being “abnormal”. This simple evaluation of single shapes of capillaries as “normal” or “abnormal” has demonstrated excellent reliability when applied by novices ( $n = 69$ ) as well as by independent expert raters ( $n = 5$ ) in a multicentre international study [48,49].

#### 4.1. A normal capillaroscopic pattern in primary Raynaud's phenomenon and pathognomonic capillaroscopic patterns in secondary Raynaud's phenomenon due to scleroderma spectrum disorders

In 1992 LeRoy et al. proposed criteria to distinguish primary from secondary Raynaud's due to SSc and SDS disorders. These criteria are easily applicable in daily practice [9]. In order to be classified as having primary RP, a patient needs to fulfil the criterion of having a normal capillaroscopy, conversely to patients with secondary RP due to SSc who usually have a “scleroderma pattern” on capillaroscopy [9]. The

wide variety of images which are “non-scleroderma pattern” may be challenging to the non-trained capillaroscopist as they consist of stereotype normal images, more specifically a normal range capillary density ( $\geq 7$  capillaries per linear mm), a normal capillary morphology (hairpin, tortuous or [once or twice] crossing shape), a normal capillary dimension (width of limbs  $< 20 \mu\text{m}$ ) and absence of large confluent bleedings, as well as “non-specific abnormalities” (see Fig. 4 and Supplementary File 1) [22,50].

The same authors proposed criteria for secondary RP due to “early” SSc. Patients with “early” SSc should have RP plus SSc-specific antibodies (i.e. anti-CENP-B, anti-Th/To, anti-topo I or anti-RNAP III) and/or a “scleroderma pattern” on nailfold capillaroscopy [51]. These criteria have recently been validated by a 20-year prospective study on patients with RP as sole presenting symptom [52]. Of those patients with RP fulfilling both the criteria for “early” SSc, 65.9% developed clinically overt SSc within 5 years and nearly 80% of them developed clinically overt SSc after long term follow-up [52]. On the contrary, only 1.8% of those patients having no SSc-specific antibodies and no “scleroderma pattern” on nailfold capillaroscopy developed clinically overt SSc after long term follow-up [52].

Even though specific definitions have been given by Maricq concerning “abnormality” due to SDS disorders, confusion has arisen to the non-expert rheumatologist concerning what “abnormality” refers to [7]. In this way, abnormality in one of the capillaroscopic characteristics has sometimes been incorrectly taken as “abnormality due to an

**Table 2**  
EULAR Study Group on Microcirculation in Rheumatic Diseases standardized capillaroscopy evaluation chart.

Capillaroscopic characteristics	Category 1				Category 2		
	Non-scleroderma pattern				Scleroderma Pattern		
	Normal	Non-Specific Abnormalities If any of the capillaroscopic characteristics is abnormal, alone or in any combination, as highlighted in yellow			Early	Active	Late
Density (/mm)	≥ 7	↓			≥ 7	Lowered density (4-6)	Further lowered density (≤3)
Dimension (μm)*	Normal		20-50		> 50 (giant)	> 50 (giant)	-
Abnormal morphology**	-			+	-	+	++
Haemorrhages	-			+	+/-	+/-	-

**\*Dimension**

**\*\*Morphology**

Some notes, considering scleroderma patterns:

- The **early** pattern NEVER presents with lowered density (cut-off ≥ 7 capillaries /mm).
- The **active** and **late** patterns ALWAYS present with lowered density (< 7 capillaries /mm); however, the cut-offs are not absolute.
- In the **active** pattern, the loss of capillaries is **combined** with giant capillaries; In the **late** pattern, the loss of capillaries is **combined** with abnormal shapes.
- In the **late** pattern, giant capillaries are NEVER found

“Adapted from Smith V. et al., Fast Track algorithm: How to differentiate a ‘scleroderma pattern’ from a ‘non-scleroderma pattern’, Copyright (2019), with permission from Elsevier.” [22]

SDS disorder” (see Table 2). To overcome this problem, the EULAR SG MC/RD has published a “Fast Track algorithm” based on landmark trials to discern a “scleroderma pattern”. This algorithm allows a capillaroscopist of any level of experience to differentiate a “scleroderma pattern” from a “non-scleroderma pattern”, with a high reliability to the principal expert [22].

Of note, in 2011, criteria for “very early” diagnosis of SSc (VEDOSS criteria), which resulted from a three Delphi-rounds consensus study, have been proposed [11]. These criteria also incorporate the presence of “scleroderma pattern” on nailfold capillaroscopy as an important criterion in addition to the presence of RP, puffy fingers, anti-nuclear antibody (ANA) positivity and SSc-specific antibodies [11]. The validation process of these latter criteria is ongoing. A first step in the validation of the VEDOSS criteria has been taken recently by the attestation of the fact that in the VEDOSS cohort the “early” scleroderma pattern (with predominance of giants and no overt loss of capillaries [see Fig. 5]) is the most prevalent pattern [53]. This lies in line with the Koenig prospective study in which overt capillary loss did not occur before the clinically overt disease had set in [52]. Of note, these criteria are supported by a recent meta-analysis suggesting that “scleroderma pattern” alone is a predictor for developing SSc in a 5 year-period (RR 11.81, 95%CI 4.07–34.25) and that the combination of a “scleroderma pattern” and ANA positivity implies an even higher risk (RR 40.45, 95%CI 14.02–116.77) [54].

In addition, in the VEDOSS patients the “late” scleroderma pattern does not occur [53]. This is conceivable, as in the clinically overt disease the “late” scleroderma pattern is associated with organ involvement [55,56]. Most patients with clinically recognizable SSc on the other hand, show a very characteristic combination of capillary abnormalities in the nailfold, which can easily be assessed through pattern recognition.

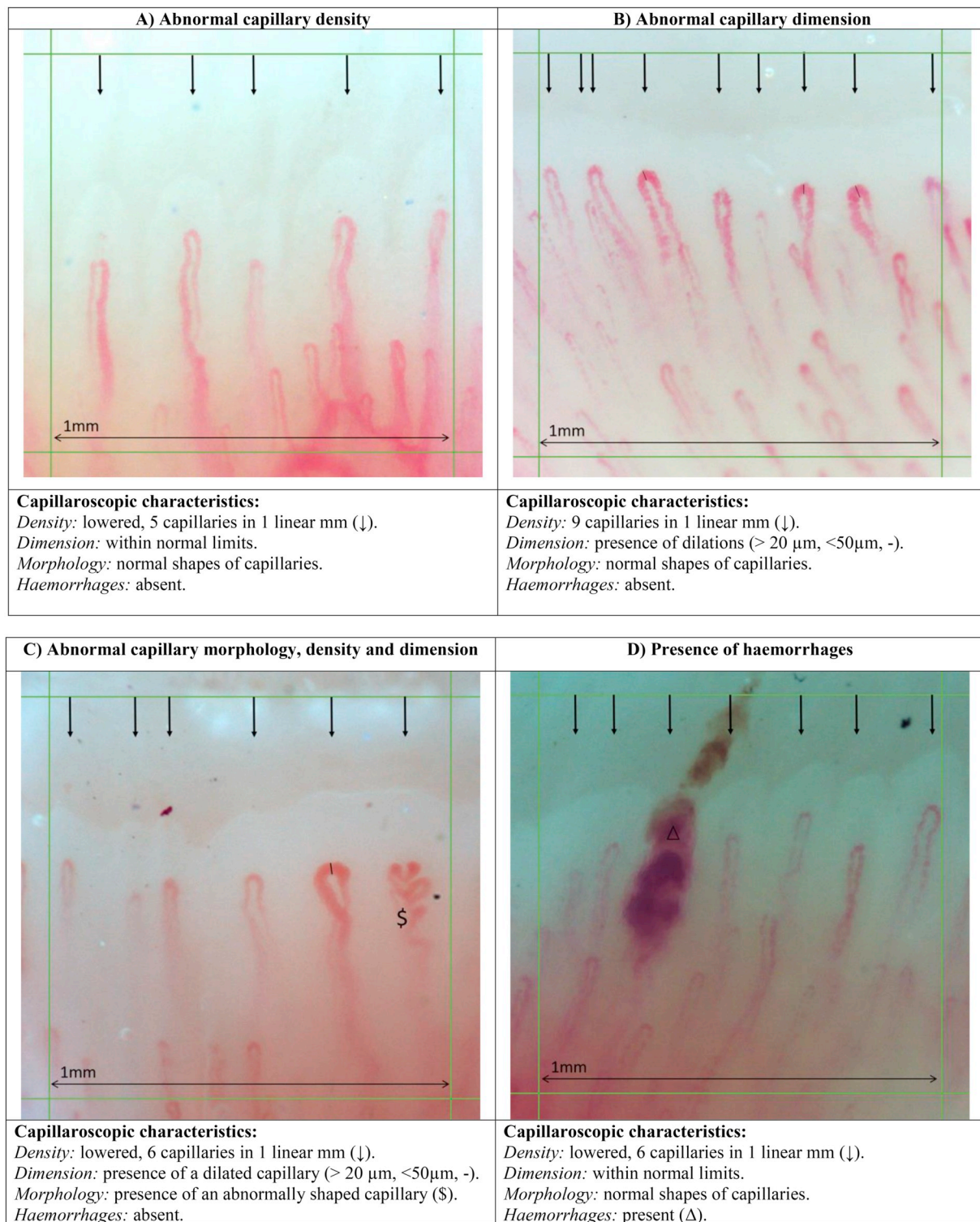
Maricq et al. described the “scleroderma pattern” with the wide-field technique [57]. This pathognomonic combination contains a striking widening of all three segments of the capillary loop (arterial,

venous and intermediate), loss of capillaries and disorganization of the nailfold capillary bed [57]. Many abnormal shapes, i.e. branched “bushy” capillaries may also be observed [57]. These scleroderma-type changes are also seen in SDS disorders, “other than” clinically recognizable SSc, such as patients with RP without a definite diagnosis of an associated disease, dermatomyositis (DM), mixed connective tissue disease (MCTD) and undifferentiated connective tissue disease (UCTD) [58]. Maricq et al. suggested that all these diseases may share some common pathogenic factors and referred to these diseases as the family of SDS disorders [58]. Maricq also defined these SDS patterns quantitatively, in which a “definitely enlarged” capillary was attested to be discriminant for SDS disorders [7]. More recently, Cutolo et al. qualitatively assessed the nailfolds of a SSc cohort with patients fulfilling the ACR criteria for SSc with a newer technique (i.e. the NVC technique with a 200× magnification) and subgraded the “scleroderma pattern” into the “early”, “active” and “late” scleroderma pattern (see Table 2, Fig. 5 and Supplementary File 2) [46].

Additionally, capillaroscopy has been incorporated in the 2013 ACR/EULAR criteria for the classification of SSc and in the assessment and monitoring recommendations of RP in children [2,3,59].

#### 4.2. “Non-specific abnormalities” in secondary Raynaud’s phenomenon due to connective tissue diseases “other than” scleroderma spectrum disorders

Opposite to the SDS disorders, the other connective tissue diseases, such as systemic lupus erythematosus (SLE), Sjogren’s syndrome etc., do not have “unique” capillary patterns. Normal patterns and a variety of “non-specific” capillary abnormalities have been observed, such as for example, lowered capillary density, change in capillary dimension (e.g. “elongated” capillaries, “widened” loops), prominence of the sub-papillary plexus, haemorrhages, abnormal shapes (e.g. “bushy” capillaries, “bizarre” capillaries) [45,60]. These abnormalities by themselves are not predictive of any defined condition and may be referred to as “non-specific abnormalities”. The fact that “non-specific abnormalities”



**Fig. 4.** Examples of “Non-specific abnormalities”.

Technique: nailfold videocapillaroscopy with a 200× magnification. A vast variety of “non-scleroderma patterns” (stereotype “normal” or “non-specific abnormalities” of capillaroscopic characteristics) may occur in a healthy population as well as in connective tissue diseases other than systemic sclerosis [22].


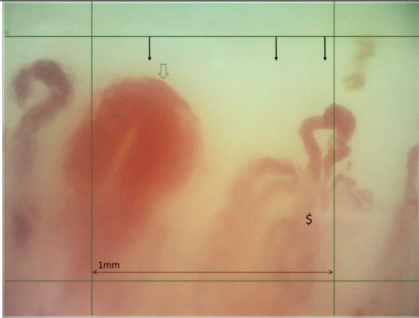
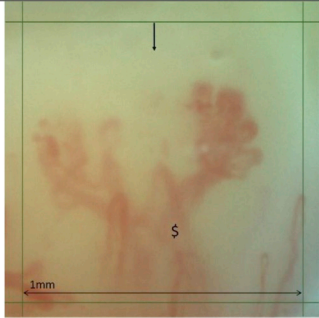
occur in primary RP may sometimes cause difficulties in differentiating primary from secondary RP.

Generally, when abnormalities are isolated or uncommon, they may represent variation of normal. When abnormalities are numerous or when several abnormalities occur in one individual, they are indicative of an underlying CTD. In this way, Andrade et al. registered a single anomaly in 25% of healthy individuals, while 8% presented two types

and 1% showed three types of abnormalities [47].

However, specific abnormalities such as giants or the combination of severe capillary loss with abnormal shapes are pathognomonic for “scleroderma patterns” (see Table 2) [22].



a) “Early” scleroderma pattern	b) “Active” scleroderma pattern	c) “Late” scleroderma pattern
		
<p><b>Capillaroscopic characteristics:</b></p> <p><i>Density:</i> 8 capillaries in 1 linear mm (↓).  <i>Dimension:</i> presence of giants (homogeneous enlargement of all three limbs of the capillary with the diameter <math>\geq 50 \mu\text{m}</math>, ↓).  <i>Morphology:</i> hairpin shaped capillaries.  <i>Haemorrhages:</i> present (<math>\Delta</math>).</p>	<p><b>Capillaroscopic characteristics:</b></p> <p><i>Density:</i> 3 capillaries in 1 linear mm (↓).  <i>Dimension:</i> presence of a giant (homogeneous enlargement of all three limbs of the capillary with the diameter <math>\geq 50 \mu\text{m}</math>, ↓).  <i>Morphology:</i> hairpin shaped capillaries and presence of an abnormally shaped capillary (<math>\\$</math>).  <i>Haemorrhages:</i> absent.</p>	<p><b>Capillaroscopic characteristics:</b></p> <p><i>Density:</i> 1 capillary in 1 linear mm (↓).  <i>Dimension:</i> not measured because of presence of abnormal shape.  <i>Morphology:</i> presence of an abnormally shaped capillary (<math>\\$</math>).  <i>Haemorrhages:</i> absent.</p>

**Fig. 5.** Examples of “scleroderma pattern” images. Technique: nailfold videocapillaroscopy with a  $200\times$  magnification.

## 5. Scoring systems

### 5.1. Qualitative, quantitative and semi-quantitative assessment of nailfold capillaroscopy

In NVC qualitative assessment, “scleroderma patterns” (subgraded as “early”, “active” and “late”) are able to distinguish between primary and secondary RP and represent an essential and reliable parameter for the early, as well as very early, diagnosis of SSc (see above) [22,46,48,53,61,62]. Of note, recent introduction of capillaroscopic assessment into the new 2013 ACR/EULAR classification criteria for SSc reflects its pivotal role in the diagnosis of the disease [2,3,9].

In NVC quantitative assessment, capillaroscopic characteristics (i.e. capillary density, capillary dimension, capillary morphology and presence/absence of haemorrhages) are standardly evaluated per unit of quantity, e.g. per linear mm (see Table 2 and Supplementary File 1) [22,43–45]. In this way for example, it has been attested recently that significantly more abnormal shapes occur in SLE patients than in healthy individuals [45]. Capillary density, as detected by NVC, is the most reliable capillaroscopic parameter and has been used for the prediction of disease progression as well as for the detection of effects of treatment [17,63–67]. Capillary density has also been used for the production of different predictive scoring systems in SSc, for example the “Capillaroscopy Skin Ulcer Risk Index” (even though a history of digital ulcers itself is still the strongest predictor for future development of digital ulcers), the “Microangiopathy Evolution Score” (MES, see below) and the simple day-to-day risk index to predict digital trophic lesions in SSc [14,65,68]. Additionally, successful treatment in open trial setting has been shown to reduce NVC alterations/scores in severe SSc cases [69]. These findings support the importance of NVC scoring in monitoring patients with SSc and suggest a putative role as an outcome measure in SSc clinical trials [64,69]. In addition, very early quantitative alterations of capillary diameter (i.e. dilations) have been found to play a predictive role in the development of the “early” scleroderma pattern [70]. Especially, the absence of a mean capillary diameter of  $\geq 30 \mu\text{m}$  in patients with RP is predictive of non-occurrence of a secondary RP due to SSc. Interestingly, a correlation between qualitative and quantitative NVC assessment and functional correlations (i.e.

peripheral blood flow changes) have also been clearly shown [71–73,83].

Of note, scoring per linear mm of the individual parameters which characterize the different qualitative NVC patterns has been attested to be reliable for the following characteristics: capillary density, giants (i.e. capillary dimension) and presence/absence of haemorrhages, but not for “ramifications” (i.e. capillary morphology) [17]. Hence, the EULAR SG MC/RD defined, for reasons of standardisation, a simple definition to define abnormal shapes encompassing “ramifications”, which has attested a high inter-rater reliability even in novice capillaroscopists [48,49,65].

Semi-quantitative and quantitative assessments have been proposed by several groups for research aims. In this way, non-exhaustively, a semi-quantitative rating scale to score microvascular parameters (0 = no changes, 1 =  $\leq 33\%$  of capillary alterations/reduction, 2 = 33–66% of capillary alterations/reduction, 3 =  $\geq 66\%$  of capillary alterations/reduction, per linear mm) was found to be a sensitive tool to quantify and to monitor the SSc microvascular damage within the 3 qualitative NVC patterns (i.e. “early”, “active” and “late”) [65].

This group also evaluated the MES (i.e. sum of three scores: capillary loss, disorganization of the microvascular array and abnormal capillary shapes, defined in that study as “ramifications”) to assess the progression of the vascular damage and attested the MES to increase during the progression of SSc [65]. Of note, quantitative assessment, i.e. standardly, rating of capillaroscopic characteristics (cfr. supra) per linear mm, has been used in international studies [15].

More recently, a study approaching the question as to how many (and which) fingers a clinician should routinely assess with NVC to detect abnormality (i.e. “giant capillaries” and “scleroderma pattern”), was published. It was shown that the sensitivity to detect capillary abnormalities increases as more fingers were examined: ranging from 31.7% to 46.6% for only one finger (right middle and left ring finger respectively), 59.8% for both ring fingers, 66.7% for a four-finger combination (both ring and middle fingers) and 74.6% for the eight-finger gold standard. As such, the authors concluded that all eight nailfold should be examined to accurately detect capillary abnormality. However, it should be noted that in case of time pressure, the best two-finger combination to detect capillary abnormalities is both ring fingers [74].

## 5.2. Automated NVC image analysis

The recent introduction of capillaroscopy in the 2013 ACR/EULAR classification criteria for SSc contributed to an intense research on automated systems for NVC image analysis, which is currently ongoing. Two recent systems merit attention. The Genoa system “AUTOCAP”, is a new fully automated method to determine in NVC images the absolute number of capillaries in an operator selected segment of the nailfold, which has attested to have a high reliability versus manual counting, not only in difficult SSc image subsets, but also in the more regular images obtained from healthy individuals and primary RP subject subsets [41,75]. Integration of fully automated systems into the pre-existing NVC imaging digital processing software present in every capillaroscopic computer may induce, according to the authors, a key quantitative biomarker in videocapillaroscopy which may be much easier, quicker and more standardized, as human interference in counting within the operator selected segment is no longer required.

As it may provide a human independent follow-up of SSc patients, fully automated systems for NVC image analysis may in the future be useful in clinical daily practice as well as for clinical research purposes including multicentre trials [75].

A group at the University of Manchester, UK, has developed a fully automated system for extracting five quantitative markers of capillary characteristics (including capillary density and apical width) [39], with more recent incorporation of flow (i.e. red blood cell velocity) [76,77]. The system uses a layered machine learning approach, with no manual steps between capturing an image and producing the quantitative data. This state-of-the-art system has the potential of providing objective outcome measures for monitoring in clinical studies, free from any observer bias, with the further advantage of fast operator times (operator time is only required for image acquisition, not for image analysis) and high performance characteristics to distinguish between subjects with and without SSc [77].

## 6. Reliability

For any method to be adopted into clinical or research practice, it has to be reliable: we must know the level of agreement between raters when reporting the different parameters which are most commonly used. These parameters (for NVC) include qualitative image grading (as “scleroderma pattern” or “non-scleroderma pattern” and subgrading as “early”, “active” or “late” according to Cutolo), semi-quantitative and quantitative measures including capillary density, apical width, presence of giant capillaries, abnormal morphology and presence of haemorrhages [45,48,49].

Of note, the distal row of capillaries cannot always be clearly seen (and therefore cannot always be evaluated): assessment of ‘evaluability’ varies between raters.

### 6.1. Reliability of image interpretation

Reliability to discern “scleroderma patterns” from “non-scleroderma patterns” (image level of evaluation) has been attested by wide-field and NVC to vary between good to excellent after training/consensus between rheumatologists of any level of experience [21,22]. The reliability of subgrading “scleroderma patterns” varies more widely though [17,21,78]. Evaluation of the reliability of individual capillaroscopic characteristics has been complicated by different studies examining different parameters. Several studies have assessed the reliability of quantitative measures including capillary density or apical diameter [16,18,20,21,36,79,80]. To overcome the plethora of definitions concerning capillary morphology, a simple consensus definition has been proposed by the EULAR SG MC/RD with high inter-rater reliability [48,49].

Reliability can be assessed at the patient level [16,17], at the whole image level or at the capillary level [48,49], with a recent study

suggesting that reliability of qualitative grading scales was similar when assessing one finger only (left 4th) or eight fingers [21].

These different studies examining intra- and inter-rater reliability have given differing results, but several broad themes emerge:

First, inter-rater reliability to discern a “scleroderma pattern” from a “non-scleroderma pattern” is good to excellent throughout studies in rheumatologists with varying capillaroscopy training level [21,22]. Importantly, simple one-hour training to novices allows them to classify an image as “scleroderma pattern” equally to a principal expert [22]. Logically, intra-rater reliability has been shown in several studies to be higher than inter-rater reliability [18,19,21].

Second, reliability has been reported to improve with training [21,78]. In this way, after consensus meetings, inter-rater agreement improved for both the Cutolo and the Maricq subgrading scales [21].

Third, evaluability of images remains a major challenge and relates in part to difficulties in obtaining high quality images from all patients and also to different opinions between raters concerning what can be defined as an evaluable nailfold. Evaluability varies across different nailfold capillary parameters. For example, in a recent reliability study involving 10 capillaroscopy experts, 73.0% of images from SSc patients were evaluable in terms of capillary density and presence/absence of giant capillaries, but only 46.2% in terms of image subgrading [19]. Subject to evaluability, certain capillaroscopic parameters (including, from a recent study, capillary density and apical diameter [apical “width”]) demonstrate high intra- and inter-rater reliability, hence, having potential as outcome measures in longitudinal studies [17,19].

Fourth, reliability differs across different capillaroscopic parameters [18,19,21]. By and large, number of capillaries is the most reliable parameter [17].

### 6.2. Reliability of image acquisition

This has been much less studied than reliability of image interpretation. Yet, reliability of image acquisition may be important to outcome measure adoption as we need to know how much variability between successive measures might relate to repeatability of the test. Several factors could influence repeatability, for example if a different section of the nailfold is captured at a second visit, results may be very different [81].

A small number of reliability studies have incorporated image acquisition as well as image interpretation [16,20,80,81]. A recent single rater study examined intra-rater reliability for intra-visit (i.e. interpreting the same image twice) and inter-visit (i.e. imaging the same finger twice, one week apart) [20]. Intra-visit reliability (intra-class correlation coefficient [ICC]) was > 0.90 for overall image grade, vessel density and apex diameter (limb “width”) and inter-visit reliability was also good for overall grade and apex diameter (limb “width”) (ICC 0.90 and 0.79 respectively). These results suggest that at least with a single rater, both image analysis and acquisition are reliable.

## 7. Conclusions on standardisation

With the recent incorporation of capillaroscopy in the 2013 ACR/EULAR classification criteria for SSc together with its assessed role in monitoring the progression of the disease [2,3,82], its increasing use by a variety of physicians internationally in daily practice as well as in research context and its promising results concerning predicting disease progression and monitoring of treatment effects, the achievement of standardisation in capillaroscopic image acquisition and analysis worldwide seems extremely important. This paper provides a consensus view from capillaroscopy experts concerning image acquisition and analysis, different capillaroscopic techniques, normal and abnormal capillaroscopic characteristics and their meaning, scoring systems and reliability of image acquisition and interpretation:

- (1) The nailfold videocapillaroscopic technique with 200×

magnification, capturing at least two adjacent fields of a linear millimetre in the middle of the finger, is the gold standard capillaroscopic technique to perform nailfold capillaroscopy. However, dermatoscopy, USB microscopy and ophthalmoscopy may be used as a screening tool.

- (2) The following capillaroscopic characteristics are evaluated in a standardized manner when quantitatively assessing a capillaroscopic image: capillary density, capillary dimension, presence/absence of abnormal shapes and presence/absence of haemorrhages.
- (3) In healthy individuals or in patients with CTDs other than SSc, both stereotype “normal” capillaroscopic characteristics, as well as a variety of capillaroscopic changes (i.e. “non-specific abnormalities”) may be present. In SSc, specific abnormalities (i.e. the “scleroderma pattern”) may be present.
- (4) Inter-rater reliability to discern a “scleroderma pattern” from a “non-scleroderma pattern” is good to excellent throughout studies in rheumatologists with different capillaroscopy training levels. Subgrading of the “scleroderma pattern” into “early”, “active” or “late” improves with training.
- (5) Research concerning automated measurement of capillaroscopic characteristics is quickly evolving. Automated measurement holds promise as clinical trial outcome measure.

Based on capillaroscopic characteristics (capillary density, capillary dimension, abnormal capillary morphology and presence/absence of haemorrhages), the assessor can deduct whether an image has changes specific to the “scleroderma pattern” as they occur in scleroderma spectrum diseases (i.e. presence of giant capillaries such as in the “early” or “active” scleroderma pattern, or presence of severe lowered density combined with abnormal shapes, such as in the “late” scleroderma pattern) or if the image is “normal” or has “non-specific” abnormalities as can occur in the healthy population, in primary RP or in connective tissue diseases other than systemic sclerosis [1–7].

#### Statement of author contribution, agreement and declaration

**Vanessa Smith:** Ideation of the study, substantial contributions to the design of the study, acquisition of data, analysis and interpretation of data, drafting of the article, critical revision of the intellectual content, final approval of the version to be published.

**Ariane L. Herrick:** Ideation of the study, substantial contributions to the design of the study, acquisition of data, analysis and interpretation of data, drafting of the article, critical revision of the intellectual content, final approval of the version to be published.

**Francesca Ingegnoli:** Analysis and interpretation of data, drafting of the article, critical revision of the intellectual content, final approval of the version to be published.

**Nemanja Damjanov:** Analysis and interpretation of data, drafting of the article, critical revision of the intellectual content, final approval of the version to be published.

**Rossella De Angelis:** Analysis and interpretation of data, drafting of the article, critical revision of the intellectual content, final approval of the version to be published.

**Christopher Denton:** Analysis and interpretation of data, drafting of the article, critical revision of the intellectual content, final approval of the version to be published.

**Oliver Distler:** Analysis and interpretation of data, drafting of the article, critical revision of the intellectual content, final approval of the version to be published.

**Karina Espejo:** Analysis and interpretation of data, drafting of the article, critical revision of the intellectual content, final approval of the version to be published.

**Ivan Foeldvari:** Analysis and interpretation of data, drafting of the article, critical revision of the intellectual content, final approval of the version to be published.

**Tracy Frech:** Analysis and interpretation of data, drafting of the

article, critical revision of the intellectual content, final approval of the version to be published.

**Boris Garro:** Analysis and interpretation of data, drafting of the article, critical revision of the intellectual content, final approval of the version to be published.

**Marwin Gutierrez:** Analysis and interpretation of data, drafting of the article, critical revision of the intellectual content, final approval of the version to be published.

**Genevieve Gyger:** Analysis and interpretation of data, drafting of the article, critical revision of the intellectual content, final approval of the version to be published.

**Eric Hachulla:** Analysis and interpretation of data, drafting of the article, critical revision of the intellectual content, final approval of the version to be published.

**Roger Hesselstrand:** Analysis and interpretation of data, drafting of the article, critical revision of the intellectual content, final approval of the version to be published.

**Annamaria Iagnocco:** Analysis and interpretation of data, drafting of the article, critical revision of the intellectual content, final approval of the version to be published.

**Cristiane Kayser:** Analysis and interpretation of data, drafting of the article, critical revision of the intellectual content, final approval of the version to be published.

**Karin Melsens:** Analysis and interpretation of data, drafting of the article, critical revision of the intellectual content, final approval of the version to be published.

**Ulf Müller-Ladner:** Analysis and interpretation of data, drafting of the article, critical revision of the intellectual content, final approval of the version to be published.

**Sabrina Paolino:** Analysis and interpretation of data, drafting of the article, critical revision of the intellectual content, final approval of the version to be published.

**Carmen Pizzorni:** Analysis and interpretation of data, drafting of the article, critical revision of the intellectual content, final approval of the version to be published.

**Mislav Radic:** Analysis and interpretation of data, drafting of the article, critical revision of the intellectual content, final approval of the version to be published.

**Valeria Ricciari:** Analysis and interpretation of data, drafting of the article, critical revision of the intellectual content, final approval of the version to be published.

**Marcus Snow:** Analysis and interpretation of data, drafting of the article, critical revision of the intellectual content, final approval of the version to be published.

**Wendy Stevens:** Analysis and interpretation of data, drafting of the article, critical revision of the intellectual content, final approval of the version to be published.

**Alberto Sulli:** Analysis and interpretation of data, drafting of the article, critical revision of the intellectual content, final approval of the version to be published.

**Jacob M. van Laar:** Analysis and interpretation of data, drafting of the article, critical revision of the intellectual content, final approval of the version to be published.

**Madelon C. Vonk:** Analysis and interpretation of data, drafting of the article, critical revision of the intellectual content, final approval of the version to be published.

**Amber Vanhaecke:** Analysis and interpretation of data, drafting of the article, critical revision of the intellectual content, final approval of the version to be published.

**Maurizio Cutolo:** Ideation of the study, substantial contributions to the design of the study, acquisition of data, analysis and interpretation of data, drafting of the article, critical revision of the intellectual content, final approval of the version to be published.

## Statement of conflict of interest

**Vanessa Smith:** Prof. Smith received a research grant from Boehringer Ingelheim; and received research funding from Actelion Pharmaceuticals Ltd., Bayer AG, F. Hoffman-La Roche AG, Galapagos NV and Sanofi.

**Ariane L. Herrick:** Received research funding from Actelion and Gesynta, speaker's fees from Actelion, and consultancy fees from Boehringer-Ingelheim, Gesynta and Camurus.

**Francesca Ingegnoli:** no conflicts of interest to declare for this study.

**Nemanja Damjanov:** no conflicts of interest to declare for this study.

**Rossella De Angelis:** no conflicts of interest to declare for this study.

**Christopher Denton:** Received research grants from GlaxoSmithKline, CSF Behring, and Inventiva and consulting fees from Roche/Genentech, Actelion, GlaxoSmithKline, Sanofi Aventis, Inventiva, CSL Behring, Boehringer-Ingelheim, UCB and Bayer.

**Oliver Distler:** Has consultancy relationship and/or has received research funding from A. Menarini, Acceleron Pharma, Amgen, AnaMar, Bayer, Boehringer Ingelheim, Catenion, CSL Behring, ChemomAb, Ergonex, GSK, Inventiva, Italfarmaco, iQone, iQvia, Lilly, medac, Medscape, Mitsubishi Tanabe Pharma, MSD, Novartis, Pfizer, Roche, Sanofi, Blade Therapeutics, Glenmark Pharmaceuticals, Target Bio Science and UCB in the area of potential treatments of scleroderma and its complications. In addition, Prof. Distler has a patent mir-29 for the treatment of systemic sclerosis issued (US8247389, EP2331143).

**Karina Espejo:** Medical advisor for Biopas and Janssen.

**Ivan Foeldvari:** Received consulting fees from Roche/Genentech, Ayer, Sanofi and Inventiva.

**Tracy Frech:** no conflicts of interest to declare for this study.

**Boris Garro:** Received speaker's fees from Janssen, Novartis, Pfizer, Ely Lilly, Roche and Eurofarma.

**Marwin Gutierrez:** no conflicts of interest to declare for this study.

**Genevieve Gyger:** no conflicts of interest to declare for this study.

**Eric Hachulla:** no conflicts of interest to declare for this study.

**Roger Hesselstrand:** no conflicts of interest to declare for this study.

**Annamaria Iagnocco:** no conflicts of interest to declare for this study.

**Cristiane Kayser:** no conflicts of interest to declare for this study.

**Karin Melsens:** no conflicts of interest to declare for this study.

**Ulf Müller-Ladner:** no conflicts of interest to declare for this study.

**Sabrina Paolino:** no conflicts of interest to declare for this study.

**Carmen Pizzorni:** no conflicts of interest to declare for this study.

**Mislav Radic:** no conflicts of interest to declare for this study.

**Valeria Riccieri:** no conflicts of interest to declare for this study.

**Marcus Snow:** no conflicts of interest to declare for this study.

**Wendy Stevens:** no conflicts of interest to declare for this study.

**Alberto Sulli:** no conflicts of interest to declare for this study.

**Jacob M. van Laar:** no conflicts of interest to declare for this study.

**Madelon C. Vonk:** no conflicts of interest to declare for this study.

**Amber Vanhaecke:** no conflicts of interest to declare for this study.

**Maurizio Cutolo:** no conflicts of interest to declare for this study.

### ORCID iD

**Vanessa Smith:**<https://orcid.org/0000-0001-6271-7945>

**Ariane Herrick:**<https://orcid.org/0000-0003-4941-7926>

**Francesca Ingegnoli:**<https://orcid.org/0000-0002-6727-1273>

**Nemanja Damjanov:**<https://orcid.org/0000-0001-6249-7428>

**Rossella De Angelis:**<https://orcid.org/0000-0003-0846-7695>

**Christopher Denton:**<https://orcid.org/0000-0003-3975-8938>

**Oliver Distler:**<https://orcid.org/0000-0002-0546-8310>

**Karina Espejo:**<https://orcid.org/0000-0003-2656-6566>

**Ivan Foeldvari:**<https://orcid.org/0000-0003-0659-5298>

**Tracy Frech:**<https://orcid.org/0000-0002-5472-3840>

**Boris Garro:**<https://orcid.org/0000-0001-6137-4434>

**Marwin Gutierrez:**<https://orcid.org/0000-0002-7995-1110>

**Genevieve Gyger:**<https://orcid.org/0000-0001-7251-3954>

**Eric Hachulla:**<https://orcid.org/0000-0001-7432-847X>

**Roger Hesselstrand:**<https://orcid.org/0000-0001-6794-2201>

**Annamaria Iagnocco:**<https://orcid.org/0000-0001-5592-724X>

**Cristiane Kayser:**<https://orcid.org/0000-0003-0543-5305>

**Ulf Müller-Ladner:**

**Karin Melsens:**<https://orcid.org/0000-0003-4125-7163>

**Sabrina Paolino:**<https://orcid.org/0000-0001-9269-5089>

**Carmen Pizzorni:**<https://orcid.org/0000-0001-5125-0200>

**Mislav Radic:**<https://orcid.org/0000-0003-3473-8428>

**Valeria Riccieri:**<https://orcid.org/0000-0002-7507-5483>

**Marcus Snow:**<https://orcid.org/0000-0001-6514-2024>

**Wendy Stevens:**<https://orcid.org/0000-0003-0237-165X>

**Alberto Sulli:**<https://orcid.org/0000-0003-3674-4880>

**Jacob M. van Laar:**<https://orcid.org/0000-0001-5544-5785>

**Amber Vanhaecke:**<https://orcid.org/0000-0002-1989-7060>

**Madelon C. Vonk:**<https://orcid.org/0000-0002-2266-9907>

**Maurizio Cutolo:**<https://orcid.org/0000-0002-4548-5334>

## Funding source declaration

Prof. Vanessa Smith is a Senior Clinical Investigator of the Research Foundation - Flanders (Belgium) (FWO) [1.8.029.15N]. The FWO was not involved in study design, collection, analysis and interpretation of data, writing of the report, nor in the decision to submit the article for publication.

## Acknowledgements

This work was supported by the NIHR Manchester Biomedical Research Centre.

## Appendix A. Supplementary data

Supplementary data to this article can be found online at <https://doi.org/10.1016/j.autrev.2020.102458>.

## References

- [1] Smith V, Cutolo M. When and how to perform the capillaroscopy. In: Cutolo M, editor. Atlas of Capillaroscopy in rheumatic diseases. Milano: Elsevier Srl; 2010.
- [2] van den Hoogen F, Khanna D, Fransen J, Johnson SR, Baron M, Tyndall A, et al. 2013 classification criteria for systemic sclerosis: an American college of rheumatology/European league against rheumatism collaborative initiative. *Annals of the rheumatic diseases* 2013;72(11):1747–55.
- [3] van den Hoogen F, Khanna D, Fransen J, Johnson SR, Baron M, Tyndall A, et al. 2013 classification criteria for systemic sclerosis: an American College of Rheumatology/European League against Rheumatism collaborative initiative. *Arthritis and rheumatism* 2013;65(11):2737–47.
- [4] Cutolo M. Capillaroscopy in rheumatic diseases from the XVIII to the XXI century. In: Cutolo M, Smith V, Sulli A, editors. Atlas of Capillaroscopy in Rheumatic Diseases. Elsevier; 2010.
- [5] Maricq HR, LeRoy EC. Patterns of finger capillary abnormalities in connective tissue disease by “wide-field” microscopy. *Arthritis Rheum* 1973;16(5):619–28.
- [6] Maricq HR. Wide-field capillary microscopy. Technique and rating scale for abnormalities seen in scleroderma and related disorders. *Arthritis Rheum* 1981;24(9):1159–65.
- [7] Maricq HR. Comparison of quantitative and semiquantitative estimates of nailfold capillary abnormalities in scleroderma spectrum disorders. *Microvasc Res* 1986;32(2):271–6.
- [8] Cutolo M, Sulli A, Smith V. How to perform and interpret capillaroscopy. *Best Pract Res Clin Rh* 2013;27(2):237–48.
- [9] LeRoy EC, Medsger Jr. TA. Raynaud's phenomenon: a proposal for classification. *Clin Exp Rheumatol* 1992;10(5):485–8.
- [10] Matucci-Cerinic M, Allanore Y, Czirkaj L, Tyndall A, Muller-Ladner U, Denton C, et al. The challenge of early systemic sclerosis for the EULAR Scleroderma Trial and Research group (EUSTAR) community. It is time to cut the Gordian knot and develop a prevention or rescue strategy. *Ann Rheum Dis* 2009;68(9):1377–80.
- [11] Avouac J, Fransen J, Walker UA, Riccieri V, Smith V, Muller C, et al. Preliminary criteria for the very early diagnosis of systemic sclerosis: results of a Delphi Consensus Study from EULAR Scleroderma Trials and Research Group. *Ann Rheum*

- Dis 2011;70(3):476–81.
- [12] Ingegnoli F, Ughi N, Dinsdale G, Orenti A, Boracchi P, Allanore Y, et al. An international SURvey on non-invasive techniques to assess the microcirculation in patients with Raynaud's phenomenon (SUNSHINE survey). *Rheumatol Int* 2017;37(11):1879–90.
- [13] Sebastiani M, Manfredi A, Colaci M, D'Amico R, Malagoli V, Giuggioli D, et al. Capillaroscopic skin ulcer risk index: a new prognostic tool for digital skin ulcer development in systemic sclerosis patients. *Arthritis Rheum* 2009;61(5):688–94.
- [14] Smith V, De Keyser F, Pizzorni C, Van Praet JT, Decuman S, Sulli A, et al. Nailfold capillaroscopy for day-to-day clinical use: construction of a simple scoring modality as a clinical prognostic index for digital trophic lesions. *Ann Rheum Dis* 2011;70(1):180–3.
- [15] Cutolo M, Herrick AL, Distler O, Becker MO, Beltran E, Carpentier P, et al. Nailfold videocapillaroscopic features and other clinical risk factors for digital ulcers in systemic sclerosis: a multicenter, prospective cohort study. *Arthritis Rheum* 2016;68(10):2527–39.
- [16] Sekiyama JY, Camargo CZ, Eduardo L, Andrade C, Kayser C. Reliability of widefield nailfold capillaroscopy and video capillaroscopy in the assessment of patients with Raynaud's phenomenon. *Arthritis Care Res* 2013;65(11):1853–61.
- [17] Smith V, Pizzorni C, De Keyser F, Decuman S, Van Praet JT, Descheppe E, et al. Reliability of the qualitative and semiquantitative nailfold videocapillaroscopy assessment in a systemic sclerosis cohort: a two-centre study. *Ann Rheum Dis* 2010;69(6):1092–6.
- [18] Hofstee HM, Serne EH, Roberts C, Hesselstrand R, Scheja A, Moore TL, et al. A multicentre study on the reliability of qualitative and quantitative nail-fold videocapillaroscopy assessment. *Rheumatology (Oxford)* 2012;51(4):749–55.
- [19] Dinsdale G, Moore T, O'Leary N, Tresadern P, Berks M, Roberts C, et al. Intra- and inter-observer reliability of nailfold videocapillaroscopy - a possible outcome measure for systemic sclerosis-related microangiopathy. *Microvasc Res* 2017;112:1–6.
- [20] Dinsdale G, Moore T, O'Leary N, Berks M, Roberts C, Manning J, et al. Quantitative outcome measures for systemic sclerosis-related microangiopathy - reliability of image acquisition in nailfold capillaroscopy. *Microvasc Res* 2017;113:56–9.
- [21] Boulon C, Devos S, Mangin M, Decamps-Le Chevoir J, Senet P, Lazareth I, et al. Reproducibility of capillaroscopic classifications of systemic sclerosis: results from the SCLEROCAP study. *Rheumatology (Oxford)* 2017;56(10):1713–20.
- [22] Smith V, Vanhaecke A, Herrick AL, Distler O, Guerra MG, Denton CP, et al. Fast track algorithm: How to differentiate a "scleroderma pattern" from a "non-scleroderma pattern" *Autoimmun Rev*. 2019;102394.
- [23] Maricq HR. "Wide-field" photography of nailfold capillary bed and a scale of plexus visualization scores (PVS). *Microvasc Res* 1970;2(3):335–40.
- [24] Herd JK. Nailfold capillary microscopy made easy. *Arthritis Rheum* 1976;19(6):1370–1.
- [25] Minkin W, Rabhan NB. Office nail fold capillary microscopy using ophthalmoscope. *J Am Acad Dermatol* 1982;7(2):190–3.
- [26] Anders HJ, Sigl T, Schattenkirchner M. Differentiation between primary and secondary Raynaud's phenomenon: a prospective study comparing nailfold capillaroscopy using an ophthalmoscope or stereomicroscope. *Ann Rheum Dis* 2001;60(4):407–9.
- [27] Baron M, Bell M, Bookman A, Buchignani M, Dunne J, Hudson M, et al. Office capillaroscopy in systemic sclerosis. *Clin Rheumatol* 2007;26(8):1268–74.
- [28] Ranft J, Lammersen T, Heidrich H. In vivo capillary microscopy findings and ophthalmoscopy findings in scleroderma. *Arthritis Rheum* 1987;30(10):1173–5.
- [29] Moore TL, Roberts C, Murray AK, Helbling I, Herrick AL. Reliability of dermoscopy in the assessment of patients with Raynaud's phenomenon. *Rheumatology*. 2010;49(3):542–7.
- [30] Dogan S, Akdogan A, Atakan N. Nailfold capillaroscopy in systemic sclerosis: is there any difference between videocapillaroscopy and dermatoscopy? *Skin Res Technol* 2013;19(4):446–9.
- [31] Beltran E, Toll A, Pros A, Carbonell J, Pujol RM. Assessment of nailfold capillaroscopy by x 30 digital epiluminescence (dermoscopy) in patients with Raynaud phenomenon. *Brit J Dermatol* 2007;156(5):892–8.
- [32] Bauersachs RM, Lossner F. The poor man's capillary microscope. A novel technique for the assessment of capillary morphology. *Ann Rheum Dis* 1997;56(7):435–7.
- [33] Hughes M, Moore T, O'Leary N, Tracey A, Ennis H, Dinsdale G, et al. A study comparing videocapillaroscopy and dermoscopy in the assessment of nailfold capillaries in patients with systemic sclerosis-spectrum disorders. *Rheumatology*. 2015;54(8):1435–42.
- [34] Hatzis C, Lerner D, Paget S, Cutolo M, Smith V, Spiera R, et al. Integration of capillary microscopy and dermoscopy into the rheumatology fellow curriculum. *Clin Exp Rheumatol* 2017;35(5):850–2.
- [35] Parker MJS, Oliffe MT, McGill NW. An evaluation of two novel capillaroscopy techniques in suspected scleroderma-spectrum disorders: a single-centre cross-sectional study. *Mod Rheumatol* 2018;28(4):676–80.
- [36] Anderson ME, Allen PD, Moore T, Hillier V, Taylor CJ, Herrick AL. Computerized nailfold video capillaroscopy—a new tool for assessment of Raynaud's phenomenon. *J Rheumatol* 2005;32(5):841–8.
- [37] Urwin SG, Griffiths B, Allen J. Quantification of differences between nailfold capillaroscopy images with a scleroderma pattern and normal pattern using measures of geometric and algorithmic complexity. *Physiol Meas* 2017;38(2):N32–41.
- [38] Murray AK, Feng KY, Moore TL, Allen PD, Taylor CJ, Herrick AL. Preliminary clinical evaluation of semi-automated nailfold capillaroscopy in the assessment of patients with Raynaud's phenomenon. *Microcirculation*. 2011;18(6):440–7.
- [39] Berks M, Tresadern P, Dinsdale G, Murray A, Moore T, Herrick A, editors. *An Automated System for Detecting and Measuring Nailfold Capillaries*. Cham: Springer International Publishing; 2014.
- [40] Hu QM, Mahler F. New system for image analysis in nailfold capillaroscopy. *Microcirculation*. 1999;6(3):227–35.
- [41] Cutolo M, Melsens K, Trombetta AC, Pizzorni C, Descheppe E, Sulli A, et al. Reliability of a new automated system for absolute capillary number counting (Autocapi) on systemic sclerosis nailfold videocapillaroscopic images. *Annals of the rheumatic diseases* 2017;76:914.
- [42] Karbalaie A, Abtahi F, Fatemi A, Etehadtavakol M, Emrani Z, Erlandsson BE. Elliptical broken line method for calculating capillary density in nailfold capillaroscopy: proposal and evaluation. *Microvasc Res* 2017;113:1–8.
- [43] Cutolo M, Smith V. Nailfold capillaroscopy and other methods to assess the microvasculopathy in systemic sclerosis. 2013 September 2013–June 2014. Third EULAR On-line Course on Systemic Sclerosis [Internet]. Third. 2014. [129–38].
- [44] Cutolo M, Sulli A, Smith V. Assessment tools of microvasculopathy. 2017. 7th EULAR On-line course on Systemic Sclerosis [Internet]. European League against Rheumatism; 2017.
- [45] Cutolo M, Melsens K, Wijnant S, Ingegnoli F, Thevissen K, De Keyser F, et al. Nailfold capillaroscopy in systemic lupus erythematosus: a systematic review and critical appraisal. *Autoimmun Rev* 2018;17(4):344–52.
- [46] Cutolo M, Sulli A, Pizzorni C, Accardo S. Nailfold videocapillaroscopy assessment of microvascular damage in systemic sclerosis. *J Rheumatol* 2000;27(1):155–60.
- [47] Andrade LE, Gabriel Junior A, Assad RL, Ferrari AJ, Atra E. Panoramic nailfold capillaroscopy: a new reading method and normal range. *Semin Arthritis Rheum* 1990;20(1):21–31.
- [48] Smith V, Beeckman S, Herrick A, Decuman S, Descheppe E, De Keyser F, et al. An EULAR study group pilot study on reliability of "simple" capillaroscopic definitions to describe capillary morphology in rheumatic diseases. *Rheumatology (Oxford)* 2016;55(5):883–90.
- [49] Cutolo M, Melsens K, Herrick AL, Foeldvari I, Descheppe E, De Keyser F, et al. Reliability of simple capillaroscopic definitions in describing capillary morphology in rheumatic diseases. *Rheumatology (Oxford)* 2018;57(4):757–9.
- [50] Ingegnoli F, Gualtierotti R, Lubatti C, Bertolazzi C, Gutierrez M, Boracchi P, et al. Nailfold capillary patterns in healthy subjects: a real issue in capillaroscopy. *Microvasc Res* 2013;90:90–5.
- [51] LeRoy EC, Medsger Jr. TA. Criteria for the classification of early systemic sclerosis. *J Rheumatol* 2001;28(7):1573–6.
- [52] Koenig M, Joyal F, Fritzler MJ, Roussin A, Abrahamowicz M, Boire G, et al. Autoantibodies and microvascular damage are independent predictive factors for the progression of Raynaud's phenomenon to systemic sclerosis: a twenty-year prospective study of 586 patients, with validation of proposed criteria for early systemic sclerosis. *Arthritis Rheum* 2008;58(12):3902–12.
- [53] Cutolo M, Smith V, Distler O, Kowal-Bielecka O, Allanore Y, Matucci-Cerenic M, et al. Preliminary analysis of nailfold capillaroscopy in the very early diagnosis of systemic sclerosis (VEDOSS): the capi-vedoss experience. *Ann Rheum Dis* 2017;76(Suppl. 2):65.
- [54] Ingegnoli F, Ughi N, Crotti C, Mosca M, Tani C. Outcomes, rates and predictors of transition of isolated Raynaud's phenomenon: a systematic review and meta-analysis. *Swiss Med Wkly* 2017;147:w14506.
- [55] Smith V, Decuman S, Sulli A, Bonroy C, Piette Y, Descheppe E, et al. Do worsening scleroderma capillaroscopic patterns predict future severe organ involvement? A pilot study. *Ann Rheum Dis* 2012;71(10):1636–9.
- [56] Ingegnoli F, Ardoini I, Boracchi P, Nailfold MCE. Capillaroscopy in systemic sclerosis: DATA from the EULAR scleroderma trials and research (EUSTAR) database. *Microvasc Res* 2013;89:122–8.
- [57] Maricq HR, Maize JC. Nailfold capillary abnormalities. *Clin Rheum Dis* 1982;8(2):455–78.
- [58] Maricq HR, Weinberger AB, LeRoy EC. Early detection of scleroderma-spectrum disorders by in vivo capillary microscopy: a prospective study of patients with Raynaud's phenomenon. *J Rheumatol* 1982;9(2):289–91.
- [59] Pain C, Constantin T, Toplak N, Moll M, Kling-Konert C, Pidot D, et al. Raynaud's syndrome in children: systematic review and development of recommendations for assessment and monitoring. *Clin Exp Rheumatol*. 2016;34(Suppl 100(5)):200–6.
- [60] Kabasakal Y, Elvins DM, Ring EF, McHugh NJ. Quantitative nailfold capillaroscopy findings in a population with connective tissue disease and in normal healthy controls. *Ann Rheum Dis* 1996;55(8):507–12.
- [61] Cutolo M, Pizzorni C, Sulli A, Smith V. Early diagnostic and predictive value of capillaroscopy in systemic sclerosis. *Curr Rheumatol Rev* 2013;9(4):249–53.
- [62] Boulon C, Blaise S, Lazareth I, Le Hello C, Pistorius MA, Imbert B, et al. Reproducibility of the scleroderma pattern assessed by wide-field capillaroscopy in subjects suffering from Raynaud's phenomenon. *Rheumatology (Oxford)* 2017;56(10):1780–3.
- [63] Emrani Z, Karbalaie A, Fatemi A, Etehadtavakol M, Erlandsson BE. Capillary density: an important parameter in nailfold capillaroscopy. *Microvasc Res* 2017;109:7–18.
- [64] Trombetta AC, Pizzorni C, Ruaro B, Paolino S, Sulli A, Smith V, et al. Effects of Longterm treatment with Bosentan and Iloprost on Nailfold absolute capillary number, fingertip blood perfusion, and clinical status in systemic sclerosis. *J Rheumatol* 2016;43(11):2033–41.
- [65] Sulli A, Secchi ME, Pizzorni C, Cutolo M. Scoring the nailfold microvascular changes during the capillaroscopic analysis in systemic sclerosis patients. *Ann Rheum Dis* 2008;67(6):885–7.
- [66] Avouac J, Lepri G, Smith V, Toniolo E, Hurabielle C, Vallet A, et al. Sequential nailfold videocapillaroscopy examinations have responsiveness to detect organ progression in systemic sclerosis. *Semin Arthritis Rheum* 2017;47(1):86–94.
- [67] Smith V, Distler O, Cutolo M. Might nailfold capillaroscopy be a "proxy" for lung involvement in connective tissue diseases? *J Rheumatol* 2019;46(9):1061–3.
- [68] Sebastiani M, Manfredi A, Cestelli V, Praino E, Cannarile D, Giuggioli M, et al.

- Validation study of predictive value of capillaroscopic skin ulcer risk index (CSURI) in scleroderma patients treated with bosentan. *Clin Exp Rheumatol*. 2015;33(Suppl 91(4)):196.
- [69] Mihai C, Smith V, Dobrota R, Gheorghiu AM, Cutolo M, Distler O. The emerging application of semi-quantitative and quantitative capillaroscopy in systemic sclerosis. *Microvasc Res* 2018;118:113–20.
- [70] Trombetta AC, Smith V, Pizzorni C, Meroni M, Paolino S, Cariti C, et al. Quantitative alterations of capillary diameter have a predictive value for development of the Capillaroscopic systemic sclerosis pattern. *J Rheumatol* 2016;43(3):599–606.
- [71] Sulli A, Ruaro B, Alessandri E, Pizzorni C, Gimmino M, Zampogna G, et al. Correlations between nailfold microangiopathy severity, finger dermal thickness and fingertip blood perfusion in systemic sclerosis patients. *Ann Rheum Dis* 2014;73(1):247–51.
- [72] Ruaro B, Sulli A, Pizzorni C, Paolino S, Smith V, Cutolo M. Correlations between skin blood perfusion values and nailfold capillaroscopy scores in systemic sclerosis patients. *Microvasc Res* 2016;105:119–24.
- [73] Lambrecht V, Cutolo M, De Keyser F, Decuman S, Ruaro B, Sulli A, et al. Reliability of the quantitative assessment of peripheral blood perfusion by laser speckle contrast analysis in a systemic sclerosis cohort. *Ann Rheum Dis* 2016;75(6):1263–4.
- [74] Dinsdale G, Roberts C, Moore T, Manning J, Berks M, Allen J, et al. Nailfold capillaroscopy-how many fingers should be examined to detect abnormality? *Rheumatology (Oxford England)*. 2019;58(2):284–8.
- [75] Cutolo M, Trombetta AC, Melsens K, Pizzorni C, Sulli A, Ruaro B, et al. Automated assessment of absolute nailfold capillary number on videocapillaroscopic images: proof of principle and validation in systemic sclerosis. *Microcirculation (New York NY: 1994)* 2018;25(4):e12447.
- [76] Berks M, Dinsdale G, Murray A, Moore T, Herrick A, Taylor C. Improved diagnosis of systemic sclerosis using nailfold capillary flow. *Medical Image Computing & Computer-Assisted Intervention: MICCAI 2016, LNCS; Athens, Greece 2016*. 2016. p. 344–52.
- [77] Berks M, Dinsdale G, Murray A, Moore T, Manning J, Taylor C, et al. Automated structure and flow measurement - a promising tool in nailfold capillaroscopy. *Microvasc Res* 2018;118:173–7.
- [78] Gutierrez M, Bertolazzi C, Tardella M, Becciolini A, D.I.C. M, Dottori M, et al. Interreader reliability in assessment of nailfold capillary abnormalities by beginners: pilot study of an intensive videocapillaroscopy training program. *J Rheumatol* 2012;39(6):1248–55.
- [79] Ingegnoli F, Gualtierotti R, Lubatti C, Zahalkova L, Meani L, Boracchi P, et al. Feasibility of different capillaroscopic measures for identifying nailfold microvascular alterations. *Semin Arthritis Rheum* 2009;38(4):289–95.
- [80] Hudson M, Masetto A, Steele R, Arthurs E, Baron M. Canadian scleroderma research G. reliability of widefield capillary microscopy to measure nailfold capillary density in systemic sclerosis. *Clin Exp Rheumatol* 2010;28(5 Suppl 62):S36–41.
- [81] Murray AK, Vail A, Moore TL, Manning JB, Taylor CJ, Herrick AL. The influence of measurement location on reliability of quantitative nailfold videocapillaroscopy in patients with SSC. *Rheumatology (Oxford)* 2012;51(7):1323–30.
- [82] Cutolo M, Soldano S, Smith V. Pathophysiology of systemic sclerosis: current understanding and new insights. *Expert Rev Clin Immunol* 2019;15(7):753–64.
- [83] Cutolo M, Vanhaecke A, Ruaro B, Deschepper E, Ickinger C, Melsens K, Piette Y, Trombetta AC, de Keyser F, Smith V. Is laser speckle contrast analysis (LASCA) the new kid on the block in systemic sclerosis? A systematic literature review and pilot study to evaluate reliability of LASCA to measure peripheral blood perfusion in scleroderma patients. *Autoimmun Rev* 2018;17:775–80. <https://doi.org/10.1016/j.autrev.2018.01.023>.