

## Barrett's esophagus in 2016: From pathophysiology to treatment

Irene Martinucci, Nicola de Bortoli, Salvatore Russo, Lorenzo Bertani, Manuele Furnari, Anna Mokrowiecka, Ewa Malecka-Panas, Vincenzo Savarino, Edoardo Savarino, Santino Marchi

Irene Martinucci, Nicola de Bortoli, Salvatore Russo, Lorenzo Bertani, Santino Marchi, Division of Gastroenterology, University of Pisa, 56124 Pisa, Italy

Manuele Furnari, Vincenzo Savarino, Division of Gastroenterology, University of Genoa, 16100 Genoa, Italy

Anna Mokrowiecka, Ewa Malecka-Panas, Department of Digestive Tract Diseases, Medical University of Lodz, 90-127 Lodz, Poland

Edoardo Savarino, Division of Gastroenterology, University of Padua, 35100 Padua, Italy

**Author contributions:** Martinucci I and de Bortoli N contributed to this paper by conceiving of and designing the study; Martinucci I, de Bortoli N and Savarino E reviewed and analyzed the literature; Martinucci I, de Bortoli N, Russo S, Bertani L, Furnari M, Mokrowiecka A and Malecka-Panas E drafted the paper; Savarino E, Savarino V and Marchi S performed the critical revision and editing of the manuscript. All authors approved the final version of the study.

**Conflict-of-interest statement:** The authors declare no potential conflicts of interest and no financial support.

**Open-Access:** This article is an open-access article which was selected by an in-house editor and fully peer-reviewed by external reviewers. It is distributed in accordance with the Creative Commons Attribution Non Commercial (CC BY-NC 4.0) license, which permits others to distribute, remix, adapt, build upon this work non-commercially, and license their derivative works on different terms, provided the original work is properly cited and the use is non-commercial. See: <http://creativecommons.org/licenses/by-nc/4.0/>

**Correspondence to:** Irene Martinucci, MD, Division of Gastroenterology, University of Pisa, Via Paradisa 2, 56124 Pisa, Italy. [martinucci.irene@gmail.com](mailto:martinucci.irene@gmail.com)  
Telephone: +39-050-997395  
Fax: +39-050-997436

Received: July 30, 2015  
Peer-review started: July 31, 2015

First decision: September 16, 2015  
Received: January 20, 2016  
Accepted: March 17, 2016  
Article in press:  
Published online: May 6, 2016

### Abstract

Esophageal complications caused by gastroesophageal reflux disease (GERD) include reflux esophagitis and Barrett's esophagus (BE). BE is a premalignant condition with an increased risk of developing esophageal adenocarcinoma (EAC). The carcinogenic sequence may progress through several steps, from normal esophageal mucosa through BE to EAC. A recent advent of functional esophageal testing (particularly multichannel intraluminal impedance and pH monitoring) has helped to improve our knowledge about GERD pathophysiology, including its complications. Those findings (when properly confirmed) might help to predict BE neoplastic progression. Over the last few decades, the incidence of EAC has continued to rise in Western populations. However, only a minority of BE patients develop EAC, opening the debate regarding the cost-effectiveness of current screening/surveillance strategies. Thus, major efforts in clinical and research practice are focused on new methods for optimal risk assessment that can stratify BE patients at low or high risk of developing EAC, which should improve the cost effectiveness of screening/surveillance programs and consequently significantly affect health-care costs. Furthermore, the area of BE therapeutic management is rapidly evolving. Endoscopic eradication therapies have been shown to be effective, and new therapeutic options for BE and EAC have emerged. The aim of the present review article is to highlight the status of screening/surveillance programs and the current progress of BE therapy. Moreover, we discuss the recent introduction of novel esophageal pathophysiological exams that have improved the knowledge of the mechanisms linking

GERD to BE.

**Key words:** Gastroesophageal reflux disease; Barrett's esophagus; Esophageal adenocarcinoma; Impedance and pH monitoring; Endoscopy

© **The Author(s) 2016.** Published by Baishideng Publishing Group Inc. All rights reserved.

**Core tip:** The review highlights the significant progress in the diagnostic and therapeutic management of Barrett's esophagus (BE) thanks to the development of up-and-coming endoscopic technologies. Moreover, we discuss the recent introduction of novel esophageal pathophysiological exams that have improved the knowledge of the mechanisms implicated in the genesis of esophageal mucosal damage, paving the way to the future possibility of predicting BE neoplastic progression. The comparison of endoscopic surveillance and eradication therapy recommendations for BE in currently available guidelines are provided.

Martinucci I, de Bortoli N, Russo S, Bertani L, Furnari M, Mokrowiecka A, Malecka-Panas E, Savarino V, Savarino E, Marchi S. Barrett's esophagus in 2016: From pathophysiology to treatment. *World J Gastrointest Pharmacol Ther* 2016; 7(2): 190-206 Available from: URL: <http://www.wjgnet.com/2150-5349/full/v7/i2/190.htm> DOI: <http://dx.doi.org/10.4292/wjgpt.v7.i2.190>

## INTRODUCTION

Gastroesophageal reflux disease (GERD) is defined as a condition that develops when the reflux of stomach contents causes troublesome symptoms and/or complications<sup>[1]</sup>. Esophageal complications caused by GERD include reflux esophagitis and Barrett's esophagus (BE), and the latter predisposes patients to esophageal adenocarcinoma (EAC)<sup>[1]</sup>. BE is a premalignant condition in which the normal stratified squamous epithelium of the distal esophagus is replaced by columnar mucosa with intestinal specialized metaplasia<sup>[2]</sup>.

GERD is a worldwide disease, and evidence suggests an overall increase in its prevalence since 1995<sup>[3,4]</sup>. As a result, costs related to GERD diagnosis, treatment and surveillance represent a substantial commitment of economic resources<sup>[5]</sup>. In parallel, over the last few decades, the incidence of EAC has continued to rise in Western populations<sup>[6-8]</sup>. The totality of evidence supports the idea that the different racial, ethnic and gender distributions of BE may drive the risk of EAC, with incidence rates much higher among male, non-Hispanic whites<sup>[7,9]</sup>. However, fewer than 10% of GERD patients are likely to progress to a diagnosis of BE at 5 years<sup>[10]</sup>, and only a minority of BE patients develop EAC; the previously estimated risk of 0.5% per year<sup>[11-13]</sup> was recently lowered to approximately 0.3% per year<sup>[14,15]</sup>. Furthermore, more than 90% of EAC

patients are not known to have BE before diagnosis<sup>[16]</sup>. In line with these assumptions, the current strategies of BE screening and surveillance programs are debated and show moderate to absent cost-effectiveness<sup>[17,18]</sup>.

The aim of the present review article is to highlight the status of screening/surveillance programs and the current progress of BE therapy. Moreover, we discuss the recent introduction of novel esophageal pathophysiological exams that have improved the knowledge of the mechanisms linking GERD to BE.

## ESOPHAGEAL PATHOPHYSIOLOGICAL EXAMS

The overall characteristics and composition of the refluxate, together along with the dysfunction of the anti-reflux barrier, the impairment of mucosal defence, visceral motility and esophageal clearance, represent the complex set of mechanisms that determines GERD manifestation and its complications<sup>[19]</sup>. To date, it is well known that the refluxate may contain varying concentrations of acid, pepsin, or duodenal contents (*i.e.*, bile acid, pancreatic enzymes) implicated in the development of esophageal mucosal damage<sup>[20-22]</sup>. In keeping with the spectrum model of GERD, several studies have demonstrated that severity of acid reflux increases from non-erosive reflux disease (NERD) through erosive reflux disease (ERD) up to short (*i.e.*, esophageal intestinal metaplasia up to 3 cm in length, SSBE) and long segments (*i.e.*, esophageal intestinal metaplasia more than 3 cm in length, LSBE) of BE<sup>[23-25]</sup>. Similarly, the presence of duodenogastroesophageal reflux (DGER), evaluated with a fiberoptic spectrophotometer (Bilitec), increases significantly across the spectrum of GERD from NERD to BE<sup>[26-29]</sup>. Of note, it has been established that acid and DGER occur simultaneously in the majority of the reflux episodes, and at best, bile reflux may have a synergistic role in producing esophageal damage<sup>[26,27]</sup>.

Over the past decade, the introduction of new technologies with which to study the esophagus from a functional point of view has helped improve our knowledge of GERD pathophysiology. The combination of multichannel intraluminal impedance and pH monitoring (MII-pH) provides a comprehensive characterization of reflux episodes during a 24-h period, detecting both chemical (*i.e.*, acid, weakly acidic or weakly alkaline) and physical properties (*i.e.*, liquid, mixed, gas, proximal extension)<sup>[30]</sup>. Regarding SSBE, by means of monitoring only pH, the acid exposure time (AET) may be similar to that found in NERD and normal in several patients<sup>[31]</sup>. Therefore, Frazzoni *et al.*<sup>[32]</sup> assessed reflux parameters *via* a combined MII-pH study in newly diagnosed SSBE, at baseline and during proton pump inhibitor (PPI) therapy. The authors found that MII-pH improved the overall diagnostic yield because the number of reflux episodes was altered in more than one half of patients with normal AET off PPI.

Moreover, 69% of SSBE patients on PPI therapy showed an increased number of total reflux events, the vast majority of which were weakly acidic refluxes<sup>[32]</sup>. These findings are consistent with other studies in which the number of both acid and weakly acidic reflux episodes was increased in patients with BE<sup>[33,34]</sup>. In particular, Savarino *et al.*<sup>[34]</sup> highlighted that the greater total exposure of esophageal mucosa to acid and weakly acidic reflux was due to intermittent reflux episodes. Indeed, the authors found a higher frequency of "re-reflux" episodes in BE than in ERD patients<sup>[34]</sup>. "Re-reflux" episodes (*i.e.*, the occurrence of a further reflux when the basal esophageal pH is already below 4) represent a diagnostic advantage obtained through MII-pH because pH-only monitoring equipment has a lower sampling frequency<sup>[35,36]</sup>. Moreover, intermittent reflux episodes determining a brief exposure of acid or bile might be more important than continuous exposure concerning the genesis of the overall alterations promoting the progression of BE<sup>[37,38]</sup>. With regard to the role of weakly acidic refluxes, it is important to realize that in an environment at a pH between 4 and 5.5, pepsins and bile acids can still damage esophageal mucosa<sup>[39,40]</sup>. Given that the main consequence of PPI therapy is to convert acid refluxes into weakly acidic refluxes without significant changes in the number of total reflux events<sup>[41]</sup>, a regression of intestinal metaplasia with long-term PPI therapy is somewhat doubtful. At last, Bredenoord *et al.*<sup>[33]</sup> found that in patients with BE, only a few reflux episodes reached the proximal esophagus that seems to be more sensitive, likely explaining, at least in part, why these subjects often report fewer symptoms than NERD patients<sup>[42,43]</sup>.

The recent introduction in the clinical and research practice of high-resolution manometry (HRM) has represented a major advance in characterizing esophageal motility abnormalities in GERD patients, with particular regard for dysfunction of the antireflux barrier and impaired esophageal clearance<sup>[44,45]</sup>. However, at present, the role of HRM in reflux remains restricted to preoperative testing, the identification of possible mechanisms and the exclusion of motility disorders<sup>[45]</sup>. Of note, several studies have shown that esophageal motility abnormalities are increasingly prevalent with increasing severity of GERD presentation<sup>[25,46-49]</sup>. In particular, Savarino *et al.*<sup>[50]</sup> evaluated 755 GERD patients through conventional or impedance esophageal manometry and/or MII-pH testing, and they found that ineffective esophageal motility gradually increased from controls and functional heartburn to NERD and from ERD to BE. Likewise, the esophageal clearing function decreased as the severity of mucosal damage increased, with ERD and BE patients having the greatest prevalence of bolus transit abnormalities, which occurred also in cases of normal motility pattern<sup>[50]</sup>.

Finally, a recent study by Frazzoni *et al.*<sup>[51]</sup> assessed that neoplastic progression in SSBE was associated with an impairment of esophageal chemical clearance. Impedance can be used to measure the clearance

of a swallowed bolus from the esophagus<sup>[52]</sup>, and a parameter representing esophageal chemical clearance, named the post-reflux swallow-induced peristaltic wave (PSPW) index, can be obtained through MII-pH monitoring<sup>[53]</sup>. The impairment of chemical clearance represents a crucial mechanism in the pathophysiology of GERD and is not affected by medical or surgical therapy. In fact, the PSPW index has increased the diagnostic yield of MII-pH in GERD patients<sup>[54,55]</sup>. In this setting, Frazzoni *et al.*<sup>[51]</sup> showed that the PSPW index was lower in SSBE patients with incident dysplasia than in those without it, and a PSPW index cut-off value of 26% was able to discriminate between these two groups of patients. Overall, the authors speculated that predicting neoplastic progression in SSBE based on a low PSPW index might be useful to select those patients deserving a close endoscopic follow-up, thus improving the cost-effectiveness of surveillance programs<sup>[51]</sup>.

---

## DIAGNOSTIC ROLE OF UPPER ENDOSCOPY

---

To date, the gold standard for the evaluation of BE is high-resolution white-light endoscopy with biopsy sampling performed according to the Seattle protocol<sup>[56-59]</sup>. The Prague classification represents a reliable and validated endoscopic classification of BE, which records the length of the esophagus involved circumferentially (C) in addition to the maximal length (M) involved at any point<sup>[60]</sup>.

The development of EAC in BE seems to occur through the progression of intestinal metaplasia to low-grade dysplasia (LGD) and high-grade dysplasia (HGD). Thus, the presence of dysplasia represents the most widely used marker of neoplastic progression in BE<sup>[61]</sup>. High-resolution endoscopes, allowing for a fine definition of the mucosal layer, seem to have high sensitivity for detecting dysplasia and BE-related early neoplasia<sup>[62]</sup>. Furthermore, a longer inspection time during white-light endoscopy seems to be associated with a higher detection rate of HGD/EAC<sup>[63]</sup>.

Some studies have investigated the detection of intestinal metaplasia with chromoendoscopy. Available data regarding the improvement of methylene blue-targeted biopsy samples, compared with random samples, are conflicting<sup>[64-67]</sup>. Moreover, methylene blue may damage DNA, so its use is not recommended<sup>[68]</sup>. The only randomized trial that has evaluated indigo carmine for the detection of dysplasia in BE has not found a higher rate of dysplasia than high-resolution white-light endoscopy<sup>[69]</sup>. Regarding virtual chromoendoscopy, narrow band imaging (NBI) is the most extensively studied in BE<sup>[70]</sup>. A meta-analysis of eight studies reported a NBI sensitivity and specificity of 95% and 65%, respectively, for the diagnosis of intestinal metaplasia and of 96% and 94%, respectively, for the diagnosis of HGD<sup>[71]</sup>. However, the interobserver agreement for the interpretation of NBI images is

moderate, and on a per-patient basis, high-resolution endoscopy alone seems to be sufficient to maximize dysplasia detection<sup>[72,73]</sup>.

Autofluorescence imaging alone has an excessively high false-positive rate of dysplasia detection<sup>[74]</sup>. Additionally, the use of endoscopic trimodal imaging (*i.e.*, high-resolution endoscopy, autofluorescence imaging and NBI), compared with standard endoscopy with random biopsy sampling, has shown contradictory results<sup>[75,76]</sup>. Regarding spectroscopy and optical coherence tomography, further studies are warranted to define their usefulness in BE surveillance<sup>[77,78]</sup>. Randomized crossover studies on the diagnostic yield of acetic acid-enhanced magnification endoscopy for BE intestinal metaplasia have produced contradictory data<sup>[79,80]</sup>. Using this technique, promising results have been obtained in dysplasia detection<sup>[81,82]</sup>, and it also seems to be more cost-effective than the Seattle protocol in a high-risk population<sup>[83]</sup>. However, further studies are necessary to ascertain the utility of this technique.

Recently, the use of probe-based confocal laser endomicroscopy combined with high-definition white-light endoscopy significantly improved the ability to detect neoplasia in BE patients compared with high-definition white-light endoscopy<sup>[84,85]</sup>.

Finally, molecular imaging, exploiting fluorescently labelled molecules that bind with a different affinity to dysplastic and non-dysplastic cells, is a promising technique<sup>[86,87]</sup>. In a recent study, using a novel peptide that binds to areas of HGD and neoplasia, Sturm *et al.*<sup>[88]</sup> reported 75% sensitivity and 97% specificity for neoplasia.

### Screening

Because the proportion of EAC patients with a prior diagnosis of BE is low, and given the low incidence of EAC in BE<sup>[15,89]</sup>, performing a screening program for BE with endoscopy in an unselected population is not cost-effective. Currently, most medical societies suggest endoscopic screening for BE in patients with chronic GERD symptoms and multiple risk factors (*i.e.*, 50 years of age or older, white race, male gender, obesity, history of smoking, family history for BE or EAC)<sup>[58,59]</sup> or in men older than 60 years with reflux symptoms for 10 years<sup>[90]</sup>.

New methods for BE screening are being evaluated with some promising results. Transnasal endoscopy is a well-tolerated method, and it seems to have good accuracy, but further validation is necessary<sup>[91]</sup>. Moreover, biopsy specimens taken with these endoscopes are small, which could increase sampling bias and hinder the interpretation<sup>[92]</sup>.

Cytosponge is a non-endoscopic esophageal sampling device coupled with immunocytochemistry for trefoil factor 3, a marker of columnar epithelium with intestinal metaplasia<sup>[93,94]</sup>. In a study involving 504 patients, Kadri *et al.*<sup>[93]</sup> reported a sensitivity and a specificity for the detection of BE of, respectively, 73%

and 94%. This test also appears to be more cost-effective for screening than conventional endoscopy<sup>[95]</sup>. However, the Cytosponge needs further validation, particularly considering the lower sensitivity for SSBE detection.

Recently, a risk-prediction model including multiple demographic and clinical variables (*i.e.*, GERD frequency and duration, age, sex, race, waist-to-hip ratio, *Helicobacter pylori* status), serum levels of cytokines (IL12p70, IL6, IL8, IL10) and leptin obtained an area under the curve of 0.85, a better result than that achieved by other non-invasive methods<sup>[96]</sup>.

### Surveillance

Observational studies have shown that patients with BE receiving an EAC diagnosis during endoscopic surveillance have earlier-stage tumours and higher survival rates than those whose tumours are discovered because of symptoms<sup>[97,98]</sup>. However, such studies are susceptible to biases that could overestimate the benefits of surveillance. Furthermore, recent studies have reported a lower annual risk of progression from BE to EAC than previously observed (approximately 0.3% per year)<sup>[14,15]</sup>. The risk of progressing to EAC could also be lower in patients with a persistence of non-dysplastic BE after several surveillance endoscopies<sup>[99]</sup>. Despite the lack of high-quality evidence, most guidelines recommend surveillance endoscopy every 2-5 years for non-dysplastic BE, as shown in Table 1<sup>[57-59,90,100,101]</sup>. In cases of an indefinite diagnosis for dysplasia (IND), the risk of progression seems to be only in the first year<sup>[102]</sup>, and it appears higher in patients with multifocal IND<sup>[103]</sup>. Current guidelines recommend a 6-12 mo interval to repeat, a biopsy (Table 1), and an increased acid suppression in cases of inflammatory infiltration and regenerative changes<sup>[57-59,90,100,101]</sup>. Because limited data are available, the natural history of LGD in BE is not yet clear. A recent meta-analysis found an annual rate of progression from LGD to EAC of 0.5% but a wide variability across studies<sup>[104]</sup>. The main issue for LGD diagnosis is a high degree of interobserver variability<sup>[105]</sup>, in part due to the difficulty in differentiating it from reactive changes<sup>[106]</sup>, therefore, a confirmation after an expert histological review is recommended<sup>[107]</sup>. Immunohistochemistry for p53 overexpression can be particularly useful to improve interobserver agreement for dysplasia detection<sup>[106]</sup>, and it can be recommended as an adjunct to histopathology<sup>[58]</sup>. In patients with LGD on a single occasion, a repeat endoscopy in 2-12 mo (time interval depending on the society) is recommended, along with a more frequent surveillance if LGD is confirmed (Table 1). There is also evidence that LSBE patients with persistent and multifocal LGD are more likely to progress to EAC<sup>[108]</sup>.

## MEDICAL THERAPY

A large retrospective study highlighted how the control of reflux is important in the management of BE,

**Table 1 Comparison of endoscopic surveillance recommendations for Barrett's esophagus in currently available guidelines**

Guidelines	NDBE	IND	LGD	HGD
BOB CAT <sup>[90]</sup>	Not recommended <sup>1</sup>	≤ 12 mo <sup>2</sup>	6-12 mo	Not recommended
ACPG <sup>[57]</sup>	< 3 cm 3-5 yr ≥ 3 cm 2-3 yr	≤ 6 mo	6 mo	Not recommended
BSG <sup>[58]</sup>	< 3 cm 3-5 yr ≥ 3 cm 2-3 yr	≤ 6 mo	6 mo	Not recommended
ASGE <sup>[100]</sup>	3-5 yr	No specific time frame	12 mo <sup>2</sup>	3 mo <sup>3</sup>
ACP <sup>[101]</sup>	3-5 yr	Not recommended	No specific time frame	No specific time frame
AGA <sup>[59]</sup>	3-5 yr	Not recommended	6-12 mo	3 mo <sup>3</sup>

<sup>1</sup>If undertaken, surveillance should be directed at high-risk groups (*i.e.*, composite risk factors including but not limited to 50 years of age or older, white race, male sex, central obesity, the length of the segment, and the symptom duration, frequency and severity), unless the life expectancy ≤ 5 years; <sup>2</sup>Six months to confirm LGD; <sup>3</sup>In the absence of eradication therapy. BOB CAT: Benign Barrett's and Cancer Taskforce; ACPG: Australian Clinical Practice Guidelines; BSG: British Society for Gastroenterology; ASGE: American Society for Gastrointestinal Endoscopy; ACP: American College of Physicians; AGA: American Gastroenterological Association; NDBE: Non-dysplastic Barrett's esophagus; IND: Indefinite for dysplasia; LGD: Low-grade dysplasia; HGD: High-grade dysplasia.

showing a significantly lower rate of progression to LGD, HGD, or EAC in patients who had a history of antireflux surgery or PPI use<sup>[109]</sup>. Moreover, a recent meta-analysis of observational studies showed that PPI therapy was associated with a 71% risk reduction in BE progression with a trend towards a dose-response relationship, considering PPI use for > 2-3 years, protective against EAC or HGD<sup>[110]</sup>. However, a considerable heterogeneity was observed, and chemopreventive high-quality prospective trials of PPIs in patients with BE are warranted<sup>[110,111]</sup>.

Complete, but not partial, acid suppression by PPIs over 6 mo, as measured by 24-h pH monitoring, decreases markers of epithelial proliferation and increases cell differentiation markers in patients with BE<sup>[112]</sup>. Similarly, a randomized clinical trial showed that a high-dose esomeprazole promoted a decrease in proliferative markers, concomitantly with a decrease in apoptotic cell death<sup>[113]</sup>. Overall, PPI therapy seems to be important not only because it reduces the acidity, and therefore the chemical damage, of the refluxate but also because PPIs have anti-inflammatory properties independent of their acid-suppressive effects<sup>[114]</sup>.

A large case-control study by Nguyen *et al*<sup>[115]</sup> indicated that using PPI, nonsteroidal anti-inflammatory drugs (NSAID)/aspirin, or statin therapy in patients with BE might reduce the risk of developing EAC. Furthermore, an interesting study found that the incubation of isolated cells from mucosal biopsies of BE metaplasia with aspirin and omeprazole together induced a significantly greater reduction in proliferative activity than that induced separately by any of the two drugs, thus suggesting a synergistic effect of the two

drugs<sup>[116]</sup>. To ascertain the efficacy of chemoprevention with PPIs and/or aspirin in BE metaplasia, a large clinical trial (Aspirin Esomeprazole Chemoprevention Trial - AspECT) was planned, the results of which are expected in 2016<sup>[117]</sup>.

Although the exact dose of PPIs and the therapeutic efficacy endpoint are not known, high-dosage PPIs are commonly prescribed in clinical practice. However, the currently available international guidelines are not in a total agreement regarding recommendations for the maintenance treatment with PPIs in patients with BE. The recent international Benign Barrett's and Cancer Taskforce (BOB CAT) consensus group hints at using medical over surgical therapies to prevent BE neoplastic progression<sup>[90]</sup>. The Australian Clinical Practice Guidelines suggests that only symptomatic patients with BE should be treated with PPI therapy, with the dose titrated to control symptoms<sup>[57]</sup>. According to the British Society of Gastroenterology, there is not yet sufficient evidence to recommend acid-suppression drugs as chemopreventive agents, even if PPIs have the best clinical profile for symptom management<sup>[58]</sup>. Moreover, the American Gastroenterological Association (AGA) highlighted that PPI therapy also has effects that, conceivably, might promote the development of cancer in BE (*i.e.*, increasing the serum levels of gastrin, a hormone than can induce proliferation in BE epithelium)<sup>[59]</sup>. Because the evidence to support potent acid suppression with PPIs as a chemopreventive strategy in BE is largely indirect, the AGA asserts that insufficient data are available to advocate the prescription of PPIs in dosages higher than those necessary to eliminate the symptoms and endoscopic signs of GERD or, for patients without such symptoms and signs, in dosages higher than those suggested as conventional for GERD treatment. Likewise, there are not sufficient data to support the use of esophageal pH monitoring to titrate the PPI dosage to normalize AET in patients with BE<sup>[59]</sup>.

## ENDOSCOPIC THERAPY

Over the past decade, evidence has been accumulating on the effectiveness of the endoscopic management in BE treatment. There is generally high level of agreement across various guidelines regarding the management of non-dysplastic BE and BE with HGD or EAC. However, the therapy administered to patients with LGD is often a controversial topic. The changing guidelines for the BE endoscopic management are shown in [Table 2](#).

### Management of non-dysplastic and LGD BE

In 2011, AGA proposed using radiofrequency ablation (RFA; with or without endoscopic mucosal resection, EMR) for selected non-dysplastic BE individuals at risk for progression; however, the risk criteria were not fully defined. Then, it was also stated that RFA in LGD leads to reversion to normal-appearing squamous epithelium in > 90% of cases, and ablation should be the

**Table 2 Recommendations for endoscopic eradication therapy in Barrett's esophagus**

Guidelines	NDBE	LGD	HGD/intramucosal EAC
ACG <sup>[118]</sup> AGA <sup>[59]</sup>	Not recommended RFA (± EMR) for select individuals at risk for progression	Not recommended RFA is a therapeutic option	Endoscopic ablation or surgical esophagectomy Endoscopic therapy with RFA, PDT or EMR EMR in BE dysplasia with a visible mucosal irregularity Before proceeding with esophagectomy, patients with HGD or intramucosal EAC should be referred for evaluation by surgical specialized centres
BAD CAT <sup>[120]</sup>	-	-	Endoscopic treatment should be preferred over endoscopic surveillance or surgery for the management of most patients with HGD/intramucosal EAC RFA is currently the best available ablation technique for the treatment of flat HGD and for the eradication of residual BE after focal EMR In the HGD endoscopic resection of all visible abnormalities, cap and snare and band ligation with resection are equally effective
ASGE (2012) <sup>[100]</sup>	Consider endoscopic ablation in select cases	Consider endoscopic resection or ablation	Consider endoscopic resection or RFA ablation. Consider EUS for local staging and lymphadenopathy Consider surgical consultation
BSG <sup>[58]</sup>	Not recommended	Not routinely recommended	Endoscopic therapy preferred over esophagectomy
ASGE (2013) <sup>[123]</sup>	-	-	EMR is indicated for nodular BE and T1a EAC and may be used for flat BE with HGD ESD can be used in similar situations but is preferred to EMR for large areas of dysplasia or T1b EAC ( <i>i.e.</i> , confined to the submucosa) Ablation techniques may be used alone or in combination with mucosal resection techniques
BOB CAT <sup>[90]</sup>	If the lesion is visible, endoscopic resection for diagnosis is then appropriate ablative therapy Not recommended	Lower risk: intense surveillance. Higher risk: ablative therapy with follow-up	-

ACG: American College of Gastroenterology; AGA: American Gastroenterology Association; BAD CAT: Barrett's Dysplasia and Cancer Taskforce; ASGE: American Society for Gastrointestinal Endoscopy; BSG: British Society for Gastroenterology; BOB CAT: Benign Barrett's and Cancer Taskforce; RFA: Radiofrequency ablation; EMR: Endoscopic mucosal resection; PDT: Photodynamic therapy; EUS: Endoscopic ultrasound; ESD: Endoscopic submucosal dissection; BE: Barrett's esophagus; NDBE: Non-dysplastic Barrett's esophagus; LGD: Low-grade dysplasia; HGD: High-grade dysplasia; EAC: Esophageal adenocarcinoma.

therapeutic option in those cases<sup>[59]</sup>. In the American Society for Gastrointestinal Endoscopy guidelines, endoscopic ablation therapy was suggested as the management option in selected patients with non-dysplastic BE. They also allowed the consideration of endoscopic resection or ablation in all LGD cases<sup>[100]</sup>. However, according to the British guidelines, the endoscopic treatment was not routinely recommended in non-dysplastic BE or in LGD<sup>[58]</sup>.

Recent management strategies, established by the international BOB CAT consensus, include the following: (1) endoscopic resection/ablation is not recommended in benign BE; and (2) patients with LGD on a single occasion, without higher-risk features, should be managed with endoscopic surveillance continued for 6-12 mo (provided the patient is fit for endoscopy and is not already undergoing therapy)<sup>[90]</sup>. The absence of dysplasia in two subsequent upper endoscopies identifies a cohort of patients, previously diagnosed with LGD, who are at low risk of neoplastic progression and can keep on routine surveillance. Moreover, the BOB CAT consensus states that BE patients with multifocal LGD and/or with LGD that persists have an increased risk for neoplastic progression than those with focal LGD

or with LGD detected on a single endoscopy<sup>[90]</sup>. The former group should be treated with ablative therapy rather than only followed up with<sup>[90]</sup>.

### Management of HGD and early-stage EAC

In HGD, there is a high rate of progression to EAC (6%-19% per year), and endoscopic therapy is a well-established therapy for these cases. All associations recommend endoscopic therapy (with a combination of EMR followed by the ablation of residual BE mucosa) for HGD and intramucosal EAC (Table 2)<sup>[58,59,118-120]</sup>. Previously, the standard of treatment was esophagectomy due to high cure rates, but it was also characterized by substantial mortality (2%-5%) and morbidity (30%-50%)<sup>[121]</sup>.

In 2013, the European Society for Medical Oncology stated that surgery is the treatment of choice in early EAC (Tis-T1a, N0). However, endoscopic resection is an alternative treatment option for selected patients because similar cure rates in specialized centres have been reported<sup>[122]</sup>. Similarly to BE with dysplasia, endoscopic therapy for early-stage EAC includes resection and ablation techniques<sup>[123]</sup>. EMR successfully eradicates 91% to 98% of T1a EAC<sup>[123,124]</sup>, with a

**Table 3 Ablation therapy in Barrett's esophagus**

Ablation modalities	Description of the technique	Outcome	Ref.
RFA	RFA uses a balloon-based circumferential array of closely spaced electrodes to deliver radiofrequency energy to the esophageal mucosa. With this technique, the mucosa is ablated to the submucosal level. A smaller, endoscope-mounted, radiofrequency catheter ablation device could be used for the focal ablation of metaplasia that could remain after treatment with the circumferential system. A follow-up endoscopy is at 3 mo when any remaining metaplasia is ablated, with a further follow-up endoscopy at 1 yr	A landmark large, multicentre, randomized trial showed that RFA can eliminate HGD, reducing the risk of EAC compared with a sham procedure. Overall, the eradication rates for HGD range from 79% to 90% and from 69% and 97% for NDBE/LGD patients  RFA is safer and easier to administer, and it causes fewer major complications, particularly stricture formation, than PDT	[133,145]
APC	APC produces a flow of ionized argon plasma that generates a high-frequency monopolar current to the BE surface under direct vision	Different eradication rates for NDBE and LGD in the short term ranged from 36% to 100% for NDBE and rates of recurrence between 62% and 100% for LGD patients	[133]
PDT	PDT is based on the injection of a light sensitizing drug (e.g., porfimer sodium) into the patient and then the exposure of a portion of the esophagus to light of a specific wavelength, which would lead to dysplasia cell death. Once the photosensitizer is activated by the light, it generates oxygen free radicals that result in cytotoxicity to the mucosal cells	The eradication rates for HGD range from 77% to 100%, and those for NDBE/LGD range from 50%-100% of patients  The limitations include the cost of the intravenous agent, the prolonged period (weeks) of photosensitivity following exposure, and an appreciable post-treatment stricture rate	[133]
CRY	CRY is a non-contact method of cryotherapy that involves an endoscopically directed spray of liquid nitrogen at -196 °C directly onto the Barrett's mucosa  The advantage is a lack of contact with mucosa and hence can be applied to irregularity, which would make the application of contact therapies such as RFA challenging	The rates of complete eradication are approximately 68%-97% for HGD and 57% for NDBE  The current literature is inadequate to assess the ability of CRY to achieve sustained reversion of the metaplastic mucosa to normal-appearing squamous epithelium in subjects at any stage of BE. Further longitudinal studies are needed	[133,156]
MPEC	MPEC uses an endoscopic multipolar electrical probe, which is used to control gastrointestinal haemorrhage that applies electrical energy at 50 W so that all BE surfaces are treated	Complete eradication in 65%-100% of NDBE.  This technique is very much operator dependent and causes dysphagia as the most common side effect	[133]

RFA: Radiofrequency ablation; APC: Argon plasma coagulation; PDT: Photodynamic therapy; CRY: Cryoablation; MPEC: Multipolar electrocoagulation; EAC: Esophageal adenocarcinoma; BE: Barrett's esophagus; IM: Intestinal metaplasia; NDBE: Non-dysplastic Barrett's esophagus; LGD: Low-grade dysplasia; HGD: High-grade dysplasia.

cancer-free survival similar to and a lower morbidity than surgical resection<sup>[125]</sup>. The long-term survival of 742 patients with TisN0M0 and T1N0M0 EAC treated with either endoscopic modalities (most commonly EMR) and surgical resection was similar<sup>[126]</sup>. Zehetner *et al.*<sup>[127]</sup> demonstrated similar survival in patients with HGD and intramucosal EAC treated with endoscopic resection and ablation than surgical resection, with a significantly lower morbidity associated with endoscopic treatment.

**Categories of endoscopic BE eradication modalities**

Multiple modalities may be employed for the endoscopic eradication of BE. There are two main types of endoscopic therapy: Tissue-acquiring techniques, which include EMR and endoscopic submucosal dissection (ESD), and ablative techniques, which include thermal techniques (RFA, multipolar electrocoagulation, argon plasma coagulation), cryotherapy and photochemical techniques (photodynamic therapy, PDT)<sup>[119]</sup>. Examples of ablative therapies are shown in Table 3.

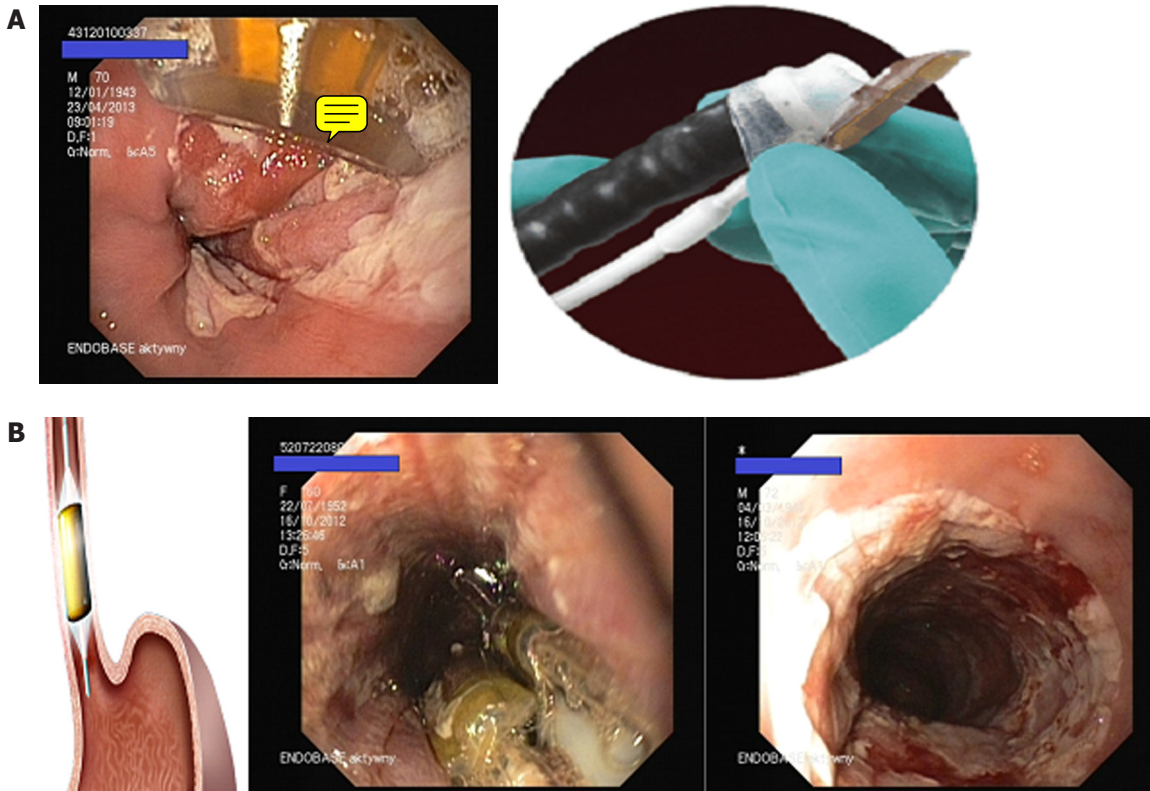
The great advantage of both EMR and ESD, compared to ablative therapies, is that specimens for histopathological analysis at the time of treatment can be obtained. The diagnosis of dysplasia and neoplasia in EMR specimens is improved, particularly because of the upstaging of cases previously diagnosed as dysplasia and the assessment of the depth of invasion with the

determination of margins of resection<sup>[119,128-130]</sup>, which have crucial implications in the appropriate choice of treatment and outcomes<sup>[131]</sup>. However, ablation therapies can be applied to larger surface areas and to different resection locations<sup>[132]</sup>.

The AGA guidelines recommended RFA, PDT, cryotherapy, thermal energy application, and EMR in BE eradication in 2011<sup>[59,133]</sup>. Currently, the most commonly used technologies are RFA and EMR used alone or in combination. In most cases, ablation techniques are used in combination with resection techniques (multimodal therapy), wherein ablation techniques are applied following EMR or ESD that are used to remove macroscopically visible lesions<sup>[119]</sup>.

**Endoscopic mucosal resection**

EMR is an endoscopic technique useful in the resection of macroscopically visible BE lesions that are less than 2 cm in diameter. To lift the lesion from the muscularis propria, normal saline or dilute epinephrine is first injected into submucosa<sup>[119]</sup>. EMR can be performed with either EMR-cap or EMR-ligation techniques. The former uses suction to retract the target tissue into a plastic cap that is attached to the endoscope, and a snare is closed around the lesion, followed by electrocautery. The latter uses suction to aspirate the tissue, followed by band deployment, to create a pseudopolyp. Then, a



**Figure 1** Radiofrequency ablation to treat Barrett's esophagus. A: HALO 90 to treat short segments, islands and tongues of Barrett's esophagus; B: Balloon ablation catheter (HALO 360) intended to treat long-segment circumferential Barrett's esophagus. Material from Department of Digestive Tract Disease, Medical University of Lodz, Poland.

hexagonal snare and electrocautery are used to resect the lesion<sup>[119]</sup>. These two techniques have shown similar diagnostic accuracy and safety<sup>[119,134]</sup>. However, with the ability to perform several resections with a single intubation and kit, EMR-ligation technique seems to be faster and less expensive<sup>[134]</sup>.

Complete remission of dysplasia and intestinal metaplasia is achieved in > 80%-90% of patients undergoing EMR with or without concurrent ablative therapy<sup>[135,136]</sup>. Recently, a large group of patients with BE and T1a EAC treated with endoscopic therapy reported a 96.3% complete response rate. The overall survival rate was 91% at 5 years and 75% at 10 years<sup>[137]</sup>.

Potential complications of EMR are bleeding, perforation, and stricture formation. Delayed bleeding is infrequent, but immediate post-resection bleeding can occur in 10% of patients<sup>[138]</sup>. Perforation rates are reported to be less than 3%. The extent of mucosa removed by EMR is the risk factor for stricture formations (37% of cases), the majority of which are successfully managed by endoscopic dilation<sup>[124,135,139]</sup>.

**Endoscopic submucosal dissection**

ESD is more likely to achieve an en bloc resection, usually of lesions > 2 cm. First, a lesion is lifted off the muscularis propria with an injected solution; then, dissection in the submucosal plane, using a variety of dissection knives, is performed. ESD in the esophagus

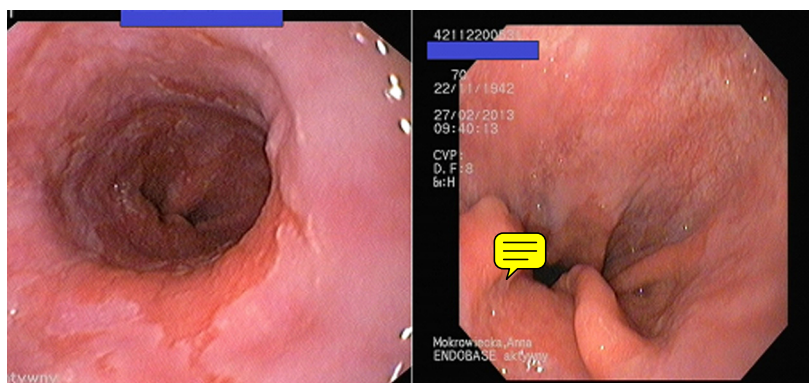
is technically more difficult, particularly due to narrow lumen, fibrosis caused by chronic reflux, and the thin wall of the esophagus. Furthermore, esophageal ESD showed frequent complications, such as bleeding, perforation (rates between 2% and 5%), and stricture formation (rates between 5% and 17.2%)<sup>[119,140-143]</sup>. Prophylactic steroid injection following esophageal ESD has been shown to decrease the risk of stricture formation<sup>[144]</sup>.

**Radiofrequency ablation**

RFA delivers high-frequency energy to the esophageal mucosa to achieve tissue necrosis. The depth of ablation is between 500 and 1000 μm. There are two systems available: A 3-cm-long balloon ablation catheter (HALO 360) intended to treat circumferential LSBE (Figure 1) and an endoscope-mounted targeted device (HALO 90, HALO 60, HALO ULTRA) to treat SSBE and BE islands and tongues (Figure 1)<sup>[132]</sup>. The technique involves mucosal ablation under endoscopic guidance followed by the removal of the adhered white coagulum in the ablated area and then by repeat treatment of the same area, all within one endoscopic session (Figure 2). Multiple endoscopic treatments may be required depending on the length of the BE segment and the tissue response. Treatment is usually performed every 2-3 mo<sup>[132]</sup>.

Among patients undergoing RFA, a complete eradication of dysplasia occurred in 90.5% and in 81%





**Figure 2** Improvement after radiofrequency ablation of Barrett's esophagus. Material from Department of Digestive Tract Disease, Medical University of Lodz, Poland.

of LGD and HGD patients, respectively, at a 12-mo follow-up. Overall, 77.4% of patients in the ablation group had complete eradication of intestinal metaplasia<sup>[145]</sup>. Subsequently, RFA therapy provided an acceptable safety profile associated with a low rate of disease progression for up to 3 years<sup>[146]</sup>. RFA efficacy has been demonstrated in several other studies, with eradication rates of metaplasia and dysplasia ranging from approximately 81%-92.6% and 75%-88.2%, respectively<sup>[119,147,148]</sup>. Moreover, reductions in rates of progression from LGD and HGD to cancer have been demonstrated in randomized controlled trials with RFA<sup>[145,147]</sup>.

RFA is safe and well tolerated. The most common complications reported include chest pain lasting less than one week, strictures requiring dilation (6%-8%), gastrointestinal haemorrhage (1%), and perforation (less than 1%)<sup>[132,145,149]</sup>.

Incomplete response to ablation is possible, particularly in cases of a longer duration of dysplasia, longer BE segments, a loss of p16 locus or polysomy (detected by FISH) and poor reflux control<sup>[119,150-152]</sup>. The presence or persistence of intestinal metaplasia under new squamous epithelium is known as "buried metaplasia". Because of its malignant potential, it is important to remember that it could be invisible in endoscopic surveillance and in superficial biopsies. The prevalence of buried metaplasia was 14% after PDT and 0.9% after RFA, but the results could be underestimated<sup>[119,153,154]</sup>. Similar rates of recurrence have been reported with all modalities of BE endotherapy (RFA, PDT and cryotherapy). Most recurrences can be treated endoscopically if detected early. Thus, post-treatment endoscopic surveillance is needed<sup>[119,155,156]</sup>.

## SURGICAL THERAPY

Surgical treatment is indicated particularly in patients who need long-term treatment of GERD (*i.e.*, patients with persistent troublesome symptoms and/or a progression of disease despite adequate PPI therapy)<sup>[157,158]</sup>. To achieve an increase in the quality of life, proper diagnostic testing should be performed to

adequately select patients before surgery<sup>[157-159]</sup>.

Laparoscopic partial and total funduplications are currently the best available surgical techniques to treat severe GERD<sup>[158]</sup>. The two major competing procedures are the laparoscopic Nissen fundoplication and the posterior partial Toupet hemifundoplication. Randomized studies have shown a similar outcome at 5 years but a higher rate of side effects (dysphagia, bloating, and flatulence) and a higher reoperation rate in the Nissen group than in the Toupet group<sup>[160,161]</sup>. In contrast, other studies have reported minor side effects and a lower reoperation rate for the Nissen procedure<sup>[162-164]</sup>. Because of these controversies, the choice of fundoplication technique should be left to the individual preferences of the surgeon.

Recently, the LOTUS trial showed a comparable rate of symptom control between surgery and escalating doses of PPIs<sup>[165]</sup>. Surgery should be considered for younger patients, particularly in cases with a high risk of progression with large hiatal hernias, severe reflux symptoms, and a long history of disease to prevent the progression to BE<sup>[166,167]</sup>. However, there is limited evidence of the effectiveness of antireflux surgery in reducing the extent of BE and the risk of progression to cancer, as well as the regression of BE. Thus, after antireflux surgery, endoscopic surveillance has to be maintained<sup>[168-171]</sup>. Of note, it has been shown that neoplastic progression after antireflux surgery is due primarily to the subsequent recurrence of reflux<sup>[172]</sup>.

Surgery is still the treatment of choice in early EAC; however, in 2011, AGA stated that most patients with HGD BE (70%-80%) can be successfully treated with endoscopic eradication therapy. Esophagectomy in patients with HGD is an alternative; however, the current data suggest a lower morbidity with ablative therapy<sup>[59]</sup>. The important issue is the choice of surgical centres specializing in the treatment of foregut cancers and HGD. In 2012, the Barrett's Dysplasia and Cancer Task Force (BAD CAT) consensus group stated that endoscopic treatment is preferred to surgery in most cases of HGD; however, esophagectomy results in a long-term cure. Moreover, there is no strong evidence that fundoplication reverses HGD<sup>[120]</sup>.

For localized EAC without suspected lymph node involvement (T1-2 N0M0), surgery is regarded as a standard treatment. However, the long-term survival does not exceed 25% if regional lymph nodes are involved (pN1-3). Therefore, preoperative treatment can also be justified<sup>[122,173]</sup>. Preoperative chemoradiotherapy is preferred in EAC for selected patients, particularly in high-risk patients (*i.e.*, those with locally more advanced stages). Even after a complete tumour response to preoperative chemoradiotherapy, operable patients with EAC should proceed to surgery<sup>[122]</sup>.

## CONCLUSION

BE is a premalignant condition that affects 1.3%-2% of the adult population<sup>[174-176]</sup>. Patients with BE have an increased risk of developing EAC through a gradual process, in which metaplastic epithelium without dysplasia evolves to LGD, HGD and eventually EAC. GERD is considered to play a major role in the development of these histologic changes<sup>[61,177]</sup>. Indeed, GERD symptoms, ERD, and BE have a number of common determinants (*i.e.*, esophagogastric junction dysfunction, impaired esophageal clearance, gastric and duodenal contents of the refluxate), which are implicated in the genesis of esophageal mucosal damage<sup>[19]</sup>. In keeping with the spectrum model of GERD, the severity of acid reflux, DGER, and esophageal motility abnormalities are increasingly prevalent with the increasing severity of GERD presentation, from NERD, through ERD, and up to BE<sup>[25,28]</sup>. Over the past decade, the introduction of new technologies (particularly with regard to MII-pH) has increased the overall diagnostic yield of the pathophysiological mechanisms underlying GERD manifestation and its complications (including BE)<sup>[32-34,50,51]</sup>. In particular, a proper evaluation of impairment of esophageal chemical clearance might help predict BE neoplastic progression<sup>[51]</sup>. However, future studies are expected to substantiate this finding.

To date, dysplasia is considered the most widely used marker of BE progression to cancer, and generally, its detection warrants intensified surveillance and/or treatment<sup>[59]</sup>. Considering the large increase in the incidence of EAC<sup>[8]</sup>, effective screening/surveillance programs of BE, coupled with improved therapeutic approaches, represent the hope to reverse this incidence. However, only a minority of BE patients develop EAC, with a current estimated risk of 0.3% per year<sup>[14,15]</sup>. Moreover, given the large number of subjects with BE, endoscopic examinations represent a substantial commitment of resources<sup>[5]</sup>. Thus, current strategies of screening and surveillance programs of BE are debated, showing moderate to absent cost-effectiveness<sup>[18]</sup>. New methods for BE screening are being evaluated with some promising results; however, we still await conclusive data for the best screening approach (*i.e.*, simple, minimally invasive), and additional studies are urgently needed. Clearly, the identification of subgroups of patients at reduced or increased risk for BE development and

degeneration would lead to more cost-effective strategies for the prevention of EAC, helping select those patients deserving a close endoscopic follow-up. At present, the management of patients with LGD represents a main issue due to its unpredictable natural history, the lack of cost-effectiveness data regarding the surveillance of LGD and high disagreement between pathologists in LGD diagnosis<sup>[100]</sup>.

The area of BE therapeutic management is rapidly evolving. Unequivocal data on the use of drugs such as PPIs, aspirin or statins in the chemoprevention of BE are lacking. At the moment, there is no doubt regarding the use of PPIs for symptom control<sup>[158,59]</sup>. Endoscopic eradication therapies have been shown to be effective in patients with BE/EAC, and new therapies have appeared. BE containing HGD and/or early-stage EAC can be treated endoscopically instead of with surgical esophagectomy. Moreover, recent management strategies, including a de-escalation strategy for lower-risk patients and escalation to intervention with follow-up for higher-risk patients, have been established<sup>[90,120]</sup>. The main objective of endoscopic therapy should be the elimination of all intestinal metaplasia because the recurrence of neoplasia appears to be higher in individuals who do not achieve a full eradication of BE<sup>[124]</sup>.

## REFERENCES

- 1 **Vakil N**, van Zanten SV, Kahrilas P, Dent J, Jones R. The Montreal definition and classification of gastroesophageal reflux disease: a global evidence-based consensus. *Am J Gastroenterol* 2006; **101**: 1900-1920; quiz 1943 [PMID: 16928254 DOI: 10.1111/j.1572-0241.2006.00630.x]
- 2 **Spechler SJ**. Barrett's esophagus. *Semin Oncol* 1994; **21**: 431-437 [PMID: 8042041]
- 3 **El-Serag HB**, Sweet S, Winchester CC, Dent J. Update on the epidemiology of gastro-oesophageal reflux disease: a systematic review. *Gut* 2014; **63**: 871-880 [PMID: 23853213 DOI: 10.1136/gutjnl-2012-304269]
- 4 **Ness-Jensen E**, Lindam A, Lagergren J, Hveem K. Changes in prevalence, incidence and spontaneous loss of gastro-oesophageal reflux symptoms: a prospective population-based cohort study, the HUNT study. *Gut* 2012; **61**: 1390-1397 [PMID: 22190483 DOI: 10.1136/gutjnl-2011-300715]
- 5 **Peery AF**, Dellon ES, Lund J, Crockett SD, McGowan CE, Bulsiewicz WJ, Gangarosa LM, Thiny MT, Stizenberg K, Morgan DR, Ringel Y, Kim HP, Dibanaventura MD, Carroll CF, Allen JK, Cook SF, Sandler RS, Kappelman MD, Shaheen NJ. Burden of gastrointestinal disease in the United States: 2012 update. *Gastroenterology* 2012; **143**: 1179-1187.e1-3 [PMID: 22885331 DOI: 10.1053/j.gastro.2012.08.002]
- 6 **Chang CY**, Cook MB, Lee YC, Lin JT, Ando T, Bhatia S, Chow WH, El-Omar EM, Goto H, Li YQ, McColl K, Reddy N, Rhee PL, Sharma P, Sung JJ, Ghoshal U, Wong JY, Wu JC, Zhang J, Ho KY. Current status of Barrett's esophagus research in Asia. *J Gastroenterol Hepatol* 2011; **26**: 240-246 [PMID: 21155883 DOI: 10.1111/j.1440-1746.2010.06529.x]
- 7 **Cook MB**, Chow WH, Devesa SS. Oesophageal cancer incidence in the United States by race, sex, and histologic type, 1977-2005. *Br J Cancer* 2009; **101**: 855-859 [PMID: 19672254 DOI: 10.1038/sj.bjc.6605246]
- 8 **Kroep S**, Lansdorp-Vogelaar I, Rubenstein JH, Lemmens VE, van Heijningen EB, Aragonés N, van Ballegooijen M, Inadomi JM. Comparing trends in esophageal adenocarcinoma incidence

- and lifestyle factors between the United States, Spain, and the Netherlands. *Am J Gastroenterol* 2014; **109**: 336-343; quiz 335, 344 [PMID: 24343546 DOI: 10.1038/ajg.2013.420]
- 9 **Corley DA**, Kubo A, Levin TR, Block G, Habel L, Rumore G, Quesenberry C, Buffler P. Race, ethnicity, sex and temporal differences in Barrett's oesophagus diagnosis: a large community-based study, 1994-2006. *Gut* 2009; **58**: 182-188 [PMID: 18978173 DOI: 10.1136/gut.2008.163360]
  - 10 **Malfertheiner P**, Nocon M, Vieth M, Stolte M, Jaspersen D, Koelz HR, Labenz J, Leodolter A, Lind T, Richter K, Willich SN. Evolution of gastro-oesophageal reflux disease over 5 years under routine medical care--the ProGERD study. *Aliment Pharmacol Ther* 2012; **35**: 154-164 [PMID: 22070159 DOI: 10.1111/j.1365-2036.2011.04901.x]
  - 11 **Jankowski JA**, Provenzale D, Moayyedi P. Esophageal adenocarcinoma arising from Barrett's metaplasia has regional variations in the west. *Gastroenterology* 2002; **122**: 588-590 [PMID: 11845805 DOI: 10.1053/gast.2002.31599]
  - 12 **Shaheen NJ**, Crosby MA, Bozyski EM, Sandler RS. Is there publication bias in the reporting of cancer risk in Barrett's esophagus? *Gastroenterology* 2000; **119**: 333-338 [PMID: 10930368 DOI: 10.1053/gast.2000.9302]
  - 13 **Murray L**, Watson P, Johnston B, Sloan J, Mainie IM, Gavin A. Risk of adenocarcinoma in Barrett's oesophagus: population based study. *BMJ* 2003; **327**: 534-535 [PMID: 12958113 DOI: 10.1136/bmj.327.7414.534]
  - 14 **Hvid-Jensen F**, Pedersen L, Drewes AM, Sørensen HT, Funch-Jensen P. Incidence of adenocarcinoma among patients with Barrett's esophagus. *N Engl J Med* 2011; **365**: 1375-1383 [PMID: 21995385 DOI: 10.1056/NEJMoa1103042]
  - 15 **Bhat S**, Coleman HG, Yousef F, Johnston BT, McManus DT, Gavin AT, Murray LJ. Risk of malignant progression in Barrett's esophagus patients: results from a large population-based study. *J Natl Cancer Inst* 2011; **103**: 1049-1057 [PMID: 21680910 DOI: 10.1093/jnci/djr203]
  - 16 **Verbeek RE**, Leenders M, Ten Kate FJ, van Hillegersberg R, Vlegaar FP, van Baal JW, van Oijen MG, Siersema PD. Surveillance of Barrett's esophagus and mortality from esophageal adenocarcinoma: a population-based cohort study. *Am J Gastroenterol* 2014; **109**: 1215-1222 [PMID: 24980881 DOI: 10.1038/ajg.2014.156]
  - 17 **Corley DA**, Mehtani K, Quesenberry C, Zhao W, de Boer J, Weiss NS. Impact of endoscopic surveillance on mortality from Barrett's esophagus-associated esophageal adenocarcinomas. *Gastroenterology* 2013; **145**: 312-9.e1 [PMID: 23673354 DOI: 10.1053/j.gastro.2013.05.004]
  - 18 **Gordon LG**, Mayne GC. Cost-effectiveness of Barrett's oesophagus screening and surveillance. *Best Pract Res Clin Gastroenterol* 2013; **27**: 893-903 [PMID: 24182609 DOI: 10.1016/j.bpg.2013.08.019]
  - 19 **Bredenoord AJ**, Pandolfino JE, Smout AJ. Gastro-oesophageal reflux disease. *Lancet* 2013; **381**: 1933-1942 [PMID: 23477993 DOI: 10.1016/S0140-6736(12)62171-0]
  - 20 **Woodland P**, Sifrim D. The refluxate: The impact of its magnitude, composition and distribution. *Best Pract Res Clin Gastroenterol* 2010; **24**: 861-871 [PMID: 21126699 DOI: 10.1016/j.bpg.2010.09.002]
  - 21 **Lagergren J**, Bergström R, Lindgren A, Nyrén O. Symptomatic gastro-oesophageal reflux as a risk factor for esophageal adenocarcinoma. *N Engl J Med* 1999; **340**: 825-831 [PMID: 10080844 DOI: 10.1056/NEJM199903183401101]
  - 22 **Koek GH**, Tack J, Sifrim D, Lerut T, Janssens J. The role of acid and duodenal gastroesophageal reflux in symptomatic GERD. *Am J Gastroenterol* 2001; **96**: 2033-2040 [PMID: 11467629 DOI: 10.1111/j.1572-0241.2001.03863.x]
  - 23 **Loughney T**, Maydonovitch CL, Wong RK. Esophageal manometry and ambulatory 24-hour pH monitoring in patients with short and long segment Barrett's esophagus. *Am J Gastroenterol* 1998; **93**: 916-919 [PMID: 9647018 DOI: 10.1111/j.1572-0241.1998.00276.x]
  - 24 **Fass R**, Hell RW, Garewal HS, Martinez P, Pulliam G, Wendel C, Sampliner RE. Correlation of oesophageal acid exposure with Barrett's oesophagus length. *Gut* 2001; **48**: 310-313 [PMID: 11171818 DOI: 10.1136/gut.48.3.310]
  - 25 **Zentilin P**, Conio M, Mele MR, Mansi C, Pandolfo N, Dulbecco P, Gambaro C, Tessieri L, Iiritano E, Bilardi C, Biagini R, Vigneri S, Savarino V. Comparison of the main oesophageal pathophysiological characteristics between short- and long-segment Barrett's oesophagus. *Aliment Pharmacol Ther* 2002; **16**: 893-898 [PMID: 11966497 DOI: 10.1046/j.1365-2036.2002.01237.x]
  - 26 **Champion G**, Richter JE, Vaezi MF, Singh S, Alexander R. Duodenogastroesophageal reflux: relationship to pH and importance in Barrett's esophagus. *Gastroenterology* 1994; **107**: 747-754 [PMID: 8076761 DOI: 10.1016/0016-5085(94)90123-6]
  - 27 **Vaezi MF**, Richter JE. Role of acid and duodenogastroesophageal reflux in gastroesophageal reflux disease. *Gastroenterology* 1996; **111**: 1192-1199 [PMID: 8898632 DOI: 10.1053/gast.1996.v111.pm8898632]
  - 28 **Koek GH**, Sifrim D, Lerut T, Janssens J, Tack J. Multivariate analysis of the association of acid and duodeno-gastro-oesophageal reflux exposure with the presence of oesophagitis, the severity of oesophagitis and Barrett's oesophagus. *Gut* 2008; **57**: 1056-1064 [PMID: 18403496 DOI: 10.1136/gut.2006.119206]
  - 29 **Zaninotto G**, Portale G, Parenti A, Lanza C, Costantini M, Molena D, Ruol A, Battaglia G, Costantino M, Epifani M, Nicoletti L. Role of acid and bile reflux in development of specialised intestinal metaplasia in distal oesophagus. *Dig Liver Dis* 2002; **34**: 251-257 [PMID: 12038808 DOI: 10.1016/S1590-8658(02)80144-X]
  - 30 **Zentilin P**, Dulbecco P, Savarino E, Giannini E, Savarino V. Combined multichannel intraluminal impedance and pH-metry: a novel technique to improve detection of gastro-oesophageal reflux literature review. *Dig Liver Dis* 2004; **36**: 565-569 [PMID: 15460839 DOI: 10.1016/j.dld.2004.03.019]
  - 31 **Frazzoni M**, Manno M, De Micheli E, Savarino V. Pathophysiological characteristics of the various forms of gastro-oesophageal reflux disease. Spectrum disease or distinct phenotypic presentations? *Dig Liver Dis* 2006; **38**: 643-648 [PMID: 16627016 DOI: 10.1016/j.dld.2006.02.020]
  - 32 **Frazzoni M**, Savarino E, Manno M, Melotti G, Mirante VG, Mussetto A, Bertani H, Manta R, Conigliaro R. Reflux patterns in patients with short-segment Barrett's oesophagus: a study using impedance-pH monitoring off and on proton pump inhibitor therapy. *Aliment Pharmacol Ther* 2009; **30**: 508-515 [PMID: 19519732 DOI: 10.1111/j.1365-2036.2009.04063.x]
  - 33 **Bredenoord AJ**, Hemmink GJ, Smout AJ. Relationship between gastro-oesophageal reflux pattern and severity of mucosal damage. *Neurogastroenterol Motil* 2009; **21**: 807-812 [PMID: 19374635 DOI: 10.1111/j.1365-2982.2009.01306.x]
  - 34 **Savarino E**, Zentilin P, Frazzoni M, Cuoco DL, Pohl D, Dulbecco P, Marabotto E, Sammito G, Gemignani L, Tutuian R, Savarino V. Characteristics of gastro-oesophageal reflux episodes in Barrett's esophagus, erosive esophagitis and healthy volunteers. *Neurogastroenterol Motil* 2010; **22**: 1061-e280 [PMID: 20557468 DOI: 10.1111/j.1365-2982.2010.01536.x]
  - 35 **Sifrim D**, Castell D, Dent J, Kahrilas PJ. Gastro-oesophageal reflux monitoring: review and consensus report on detection and definitions of acid, non-acid, and gas reflux. *Gut* 2004; **53**: 1024-1031 [PMID: 15194656 DOI: 10.1136/gut.2003.033290]
  - 36 **Shay SS**, Johnson LF, Richter JE. Acid reflow: a review, emphasizing detection by impedance, manometry, and scintigraphy, and the impact on acid clearing pathophysiology as well as interpreting the pH record. *Dig Dis Sci* 2003; **48**: 1-9 [PMID: 12645783 DOI: 10.1023/A:1021762310433]
  - 37 **Kaur BS**, Ouatu-Lascar R, Omary MB, Triadafilopoulos G. Bile salts induce or blunt cell proliferation in Barrett's esophagus in an acid-dependent fashion. *Am J Physiol Gastrointest Liver Physiol* 2000; **278**: G1000-G1009 [PMID: 10859231]
  - 38 **Tselepis C**, Morris CD, Wakelin D, Hardy R, Perry I, Luong QT, Harper E, Harrison R, Attwood SE, Jankowski JA. Upregulation of the oncogene c-myc in Barrett's adenocarcinoma: induction of c-myc by acidified bile acid in vitro. *Gut* 2003; **52**: 174-180 [PMID: 12524396 DOI: 10.1136/gut.52.2.174]

- 39 **Roberts NB**. Review article: human pepsins - their multiplicity, function and role in reflux disease. *Aliment Pharmacol Ther* 2006; **24** Suppl 2: 2-9 [PMID: 16939427 DOI: 10.1111/j.1365-2036.2006.03038.x]
- 40 **Farré R**, van Malenstein H, De Vos R, Geboes K, Depoortere I, Vanden Berghe P, Fornari F, Blondeau K, Mertens V, Tack J, Sifrim D. Short exposure of oesophageal mucosa to bile acids, both in acidic and weakly acidic conditions, can impair mucosal integrity and provoke dilated intercellular spaces. *Gut* 2008; **57**: 1366-1374 [PMID: 18593808 DOI: 10.1136/gut.2007.141804]
- 41 **Hemmink GJ**, Bredenoord AJ, Weusten BL, Monkelbaan JF, Timmer R, Smout AJ. Esophageal pH-impedance monitoring in patients with therapy-resistant reflux symptoms: 'on' or 'off' proton pump inhibitor? *Am J Gastroenterol* 2008; **103**: 2446-2453 [PMID: 18684197 DOI: 10.1111/j.1572-0241.2008.02033.x]
- 42 **Bredenoord AJ**, Weusten BL, Timmer R, Smout AJ. Characteristics of gastroesophageal reflux in symptomatic patients with and without excessive esophageal acid exposure. *Am J Gastroenterol* 2006; **101**: 2470-2475 [PMID: 17090278 DOI: 10.1111/j.1572-0241.2006.00945.x]
- 43 **Emerenziani S**, Ribolsi M, Sifrim D, Blondeau K, Cicala M. Regional oesophageal sensitivity to acid and weakly acidic reflux in patients with non-erosive reflux disease. *Neurogastroenterol Motil* 2009; **21**: 253-258 [PMID: 19019016 DOI: 10.1111/j.1365-2982.2008.01203.x]
- 44 **Martinucci I**, de Bortoli N, Giacchino M, Bodini G, Marabotto E, Marchi S, Savarino V, Savarino E. Esophageal motility abnormalities in gastroesophageal reflux disease. *World J Gastrointest Pharmacol Ther* 2014; **5**: 86-96 [PMID: 24868489 DOI: 10.4292/wjgpt.v5.i2.86]
- 45 **DeVault K**, McMahon BP, Celebi A, Costamagna G, Marchese M, Clarke JO, Hejazi RA, McCallum RW, Savarino V, Zentilin P, Savarino E, Thomson M, Souza RF, Donohoe CL, O'Farrell NJ, Reynolds JV. Defining esophageal landmarks, gastroesophageal reflux disease, and Barrett's esophagus. *Ann N Y Acad Sci* 2013; **1300**: 278-295 [PMID: 24117649 DOI: 10.1111/nyas.12253]
- 46 **Kahrilas PJ**, Dodds WJ, Hogan WJ, Kern M, Arndorfer RC, Reece A. Esophageal peristaltic dysfunction in peptic esophagitis. *Gastroenterology* 1986; **91**: 897-904 [PMID: 3743966]
- 47 **Ho KY**, Kang JY. Reflux esophagitis patients in Singapore have motor and acid exposure abnormalities similar to patients in the Western hemisphere. *Am J Gastroenterol* 1999; **94**: 1186-1191 [PMID: 10235190 DOI: 10.1111/j.1572-0241.1999.01063.x]
- 48 **Diener U**, Patti MG, Molena D, Fisicella PM, Way LW. Esophageal dysmotility and gastroesophageal reflux disease. *J Gastrointest Surg* 2001; **5**: 260-265 [PMID: 11360049]
- 49 **Wu JC**, Cheung CM, Wong VW, Sung JJ. Distinct clinical characteristics between patients with nonerosive reflux disease and those with reflux esophagitis. *Clin Gastroenterol Hepatol* 2007; **5**: 690-695 [PMID: 17481961 DOI: 10.1016/j.cgh.2007.02.023]
- 50 **Savarino E**, Gemignani L, Pohl D, Zentilin P, Dulbecco P, Assandri L, Marabotto E, Bonfanti D, Inferrera S, Fazio V, Malesci A, Tutuian R, Savarino V. Oesophageal motility and bolus transit abnormalities increase in parallel with the severity of gastro-oesophageal reflux disease. *Aliment Pharmacol Ther* 2011; **34**: 476-486 [PMID: 21671968 DOI: 10.1111/j.1365-2036.2011.04742.x]
- 51 **Frazzoni M**, Bertani H, Conigliaro R, Frazzoni L, Losi L, Melotti G. Neoplastic progression in short-segment Barrett's oesophagus is associated with impairment of chemical clearance, but not inadequate acid suppression by proton pump inhibitor therapy. *Aliment Pharmacol Ther* 2014; **40**: 835-842 [PMID: 25087846 DOI: 10.1111/apt.12895]
- 52 **Conchillo JM**, Smout AJ. Review article: intra-oesophageal impedance monitoring for the assessment of bolus transit and gastro-oesophageal reflux. *Aliment Pharmacol Ther* 2009; **29**: 3-14 [PMID: 18945260 DOI: 10.1111/j.1365-2036.2008.03863.x]
- 53 **Frazzoni M**, Manta R, Mirante VG, Conigliaro R, Frazzoni L, Melotti G. Esophageal chemical clearance is impaired in gastro-oesophageal reflux disease--a 24-h impedance-pH monitoring assessment. *Neurogastroenterol Motil* 2013; **25**: 399-406, e295 [PMID: 23360178 DOI: 10.1111/nmo.12080]
- 54 **de Bortoli N**, Martinucci I, Savarino E, Tutuian R, Frazzoni M, Piaggi P, Bertani L, Furnari M, Franchi R, Russo S, Bellini M, Savarino V, Marchi S. Association between baseline impedance values and response proton pump inhibitors in patients with heartburn. *Clin Gastroenterol Hepatol* 2015; **13**: 1082-8.e1 [PMID: 25499991 DOI: 10.1016/j.cgh.2014.11.035]
- 55 **Frazzoni M**, Savarino E, de Bortoli N, Martinucci I, Furnari M, Frazzoni L, Mirante VG, Bertani H, Marchi S, Conigliaro R, Savarino V. Analyses of the Post-reflux Swallow-induced Peristaltic Wave Index and Nocturnal Baseline Impedance Parameters Increase the Diagnostic Yield of Impedance-pH Monitoring of Patients With Reflux Disease. *Clin Gastroenterol Hepatol* 2016; **14**: 40-46 [PMID: 26122764 DOI: 10.1016/j.cgh.2015.06.026]
- 56 **Levine DS**, Haggitt RC, Blount PL, Rabinovitch PS, Rusch VW, Reid BJ. An endoscopic biopsy protocol can differentiate high-grade dysplasia from early adenocarcinoma in Barrett's esophagus. *Gastroenterology* 1993; **105**: 40-50 [PMID: 8514061]
- 57 **Whiteman DC**, Appleyard M, Bahin FF, Bobryshev YV, Bourke MJ, Brown I, Chung A, Clouston A, Dickens E, Emery J, Eslick GD, Gordon LG, Grimpen F, Hebbard G, Holliday L, Hourigan LF, Kendall BJ, Lee EY, Levert-Mignon A, Lord RV, Lord SJ, Maule D, Moss A, Norton I, Olver I, Pavey D, Raftopoulos S, Rajendra S, Schoeman M, Singh R, Sitas F, Smithers BM, Taylor AC, Thomas ML, Thomson I, To H, von Dincklage J, Vuletic C, Watson DI, Yuloff IF. Australian clinical practice guidelines for the diagnosis and management of Barrett's esophagus and early esophageal adenocarcinoma. *J Gastroenterol Hepatol* 2015; **30**: 804-820 [PMID: 25612140 DOI: 10.1111/jgh.12913]
- 58 **Fitzgerald RC**, di Pietro M, Ragunath K, Ang Y, Kang JY, Watson P, Trudgill N, Patel P, Kaye PV, Sanders S, O'Donovan M, Bird-Lieberman E, Bhandari P, Jankowski JA, Attwood S, Parsons SL, Loft D, Lagergren J, Moayyedi P, Lyraztopoulos G, de Caestecker J. British Society of Gastroenterology guidelines on the diagnosis and management of Barrett's oesophagus. *Gut* 2014; **63**: 7-42 [PMID: 24165758 DOI: 10.1136/gutjnl-2013-305372]
- 59 **Spechler SJ**, Sharma P, Souza RF, Inadomi JM, Shaheen NJ. American Gastroenterological Association medical position statement on the management of Barrett's esophagus. *Gastroenterology* 2011; **140**: 1084-1091 [PMID: 21376940 DOI: 10.1053/j.gastro.2011.01.030]
- 60 **Sharma P**, Dent J, Armstrong D, Bergman JJ, Gossner L, Hoshihara Y, Jankowski JA, Junghard O, Lundell L, Tytgat GN, Vieth M. The development and validation of an endoscopic grading system for Barrett's esophagus: the Prague C & M criteria. *Gastroenterology* 2006; **131**: 1392-1399 [PMID: 17101315 DOI: 10.1053/j.gastro.2006.08.032]
- 61 **Hameeteman W**, Tytgat GN, Houthoff HJ, van den Tweel JG. Barrett's esophagus: development of dysplasia and adenocarcinoma. *Gastroenterology* 1989; **96**: 1249-1256 [PMID: 2703113]
- 62 **Wolfsen HC**, Crook JE, Krishna M, Achem SR, Devault KR, Bouras EP, Loeb DS, Stark ME, Woodward TA, Hemminger LL, Cayer FK, Wallace MB. Prospective, controlled tandem endoscopy study of narrow band imaging for dysplasia detection in Barrett's Esophagus. *Gastroenterology* 2008; **135**: 24-31 [PMID: 18442484 DOI: 10.1053/j.gastro.2008.03.019]
- 63 **Gupta N**, Gaddam S, Wani SB, Bansal A, Rastogi A, Sharma P. Longer inspection time is associated with increased detection of high-grade dysplasia and esophageal adenocarcinoma in Barrett's esophagus. *Gastrointest Endosc* 2012; **76**: 531-538 [PMID: 22732877 DOI: 10.1016/j.gie.2012.04.470]
- 64 **Sharma P**, Topalovski M, Mayo MS, Weston AP. Methylene blue chromoendoscopy for detection of short-segment Barrett's esophagus. *Gastrointest Endosc* 2001; **54**: 289-293 [PMID: 11522967]
- 65 **Canto MI**, Setrakian S, Willis J, Chak A, Petras R, Powe NR, Sivak MV. Methylene blue-directed biopsies improve detection of intestinal metaplasia and dysplasia in Barrett's esophagus. *Gastrointest Endosc* 2000; **51**: 560-568 [PMID: 10805842]
- 66 **Gossner L**, Pech O, May A, Vieth M, Stolte M, Ell C. Comparison

- of methylene blue-directed biopsies and four-quadrant biopsies in the detection of high-grade intraepithelial neoplasia and early cancer in Barrett's oesophagus. *Dig Liver Dis* 2006; **38**: 724-729 [PMID: 16911879 DOI: 10.1016/j.dld.2006.05.025]
- 67 **Ngamruengphong S**, Sharma VK, Das A. Diagnostic yield of methylene blue chromoendoscopy for detecting specialized intestinal metaplasia and dysplasia in Barrett's esophagus: a meta-analysis. *Gastrointest Endosc* 2009; **69**: 1021-1028 [PMID: 19215918 DOI: 10.1016/j.gie.2008.06.056]
- 68 **Davies J**, Burke D, Olliver JR, Hardie LJ, Wild CP, Routledge MN. Methylene blue but not indigo carmine causes DNA damage to colonocytes in vitro and in vivo at concentrations used in clinical chromoendoscopy. *Gut* 2007; **56**: 155-156 [PMID: 17172595 DOI: 10.1136/gut.2006.107300]
- 69 **Kara MA**, Peters FP, Rosmolen WD, Krishnadath KK, ten Kate FJ, Fockens P, Bergman JJ. High-resolution endoscopy plus chromoendoscopy or narrow-band imaging in Barrett's esophagus: a prospective randomized crossover study. *Endoscopy* 2005; **37**: 929-936 [PMID: 16189764 DOI: 10.1055/s-2005-870433]
- 70 **Sharma P**, Bansal A, Mathur S, Wani S, Cherian R, McGregor D, Higbee A, Hall S, Weston A. The utility of a novel narrow band imaging endoscopy system in patients with Barrett's esophagus. *Gastrointest Endosc* 2006; **64**: 167-175 [PMID: 16860063 DOI: 10.1016/j.gie.2005.10.044]
- 71 **Mannath J**, Subramanian V, Hawkey CJ, Raganath K. Narrow band imaging for characterization of high grade dysplasia and specialized intestinal metaplasia in Barrett's esophagus: a meta-analysis. *Endoscopy* 2010; **42**: 351-359 [PMID: 20200809 DOI: 10.1055/s-0029-1243949]
- 72 **Sharma P**, Hawes RH, Bansal A, Gupta N, Curvers W, Rastogi A, Singh M, Hall M, Mathur SC, Wani SB, Hoffman B, Gaddam S, Fockens P, Bergman JJ. Standard endoscopy with random biopsies versus narrow band imaging targeted biopsies in Barrett's esophagus: a prospective, international, randomised controlled trial. *Gut* 2013; **62**: 15-21 [PMID: 22315471 DOI: 10.1136/gutjnl-2011-300962]
- 73 **Curvers WL**, Bohmer CJ, Mallant-Hent RC, Naber AH, Ponsioen CI, Raganath K, Singh R, Wallace MB, Wolfsen HC, Song LM, Lindeboom R, Fockens P, Bergman JJ. Mucosal morphology in Barrett's esophagus: interobserver agreement and role of narrow band imaging. *Endoscopy* 2008; **40**: 799-805 [PMID: 18828075 DOI: 10.1055/s-2008-1077596]
- 74 **Kara MA**, Peters FP, Fockens P, ten Kate FJ, Bergman JJ. Endoscopic video-autofluorescence imaging followed by narrow band imaging for detecting early neoplasia in Barrett's esophagus. *Gastrointest Endosc* 2006; **64**: 176-185 [PMID: 16860064 DOI: 10.1016/j.gie.2005.11.050]
- 75 **Curvers WL**, Alvarez Herrero L, Wallace MB, Wong Kee Song LM, Raganath K, Wolfsen HC, Prasad GA, Wang KK, Subramanian V, Weusten BL, Ten Kate FJ, Bergman JJ. Endoscopic tri-modal imaging is more effective than standard endoscopy in identifying early-stage neoplasia in Barrett's esophagus. *Gastroenterology* 2010; **139**: 1106-1114 [PMID: 20600033 DOI: 10.1053/j.gastro.2010.06.045]
- 76 **Curvers WL**, van Vilsteren FG, Baak LC, Böhmer C, Mallant-Hent RC, Naber AH, van Oijen A, Ponsioen CY, Scholten P, Schenk E, Schoon E, Seldenrijk CA, Meijer GA, ten Kate FJ, Bergman JJ. Endoscopic trimodal imaging versus standard video endoscopy for detection of early Barrett's neoplasia: a multicenter, randomized, crossover study in general practice. *Gastrointest Endosc* 2011; **73**: 195-203 [PMID: 21168835 DOI: 10.1016/j.gie.2010.10.014]
- 77 **Wallace MB**, Perelman LT, Backman V, Crawford JM, Fitzmaurice M, Seiler M, Badizadegan K, Shields SJ, Itzkan I, Dasari RR, Van Dam J, Feld MS. Endoscopic detection of dysplasia in patients with Barrett's esophagus using light-scattering spectroscopy. *Gastroenterology* 2000; **119**: 677-682 [PMID: 10982761 DOI: 10.1053/gast.2000.16511]
- 78 **Evans JA**, Poneros JM, Bouma BE, Bressner J, Halpern EF, Shishkov M, Lauwers GY, Mino-Kenudson M, Nishioka NS, Tearney GJ. Optical coherence tomography to identify intramucosal carcinoma and high-grade dysplasia in Barrett's esophagus. *Clin Gastroenterol Hepatol* 2006; **4**: 38-43 [PMID: 16431303 DOI: 10.1016/S1542-3565(05)00746-9]
- 79 **Hoffman A**, Kiesslich R, Bender A, Neurath MF, Nafe B, Herrmann G, Jung M. Acetic acid-guided biopsies after magnifying endoscopy compared with random biopsies in the detection of Barrett's esophagus: a prospective randomized trial with crossover design. *Gastrointest Endosc* 2006; **64**: 1-8 [PMID: 16813794 DOI: 10.1016/j.gie.2005.09.031]
- 80 **Ferguson DD**, DeVault KR, Krishna M, Loeb DS, Wolfsen HC, Wallace MB. Enhanced magnification-directed biopsies do not increase the detection of intestinal metaplasia in patients with GERD. *Am J Gastroenterol* 2006; **101**: 1611-1616 [PMID: 16863568 DOI: 10.1111/j.1572-0241.2006.00622.x]
- 81 **Longcroft-Wheaton G**, Duku M, Mead R, Poller D, Bhandari P. Acetic acid spray is an effective tool for the endoscopic detection of neoplasia in patients with Barrett's esophagus. *Clin Gastroenterol Hepatol* 2010; **8**: 843-847 [PMID: 20601133 DOI: 10.1016/j.cgh.2010.06.016]
- 82 **Pohl J**, Pech O, May A, Manner H, Fissler-Eckhoff A, Ell C. Incidence of macroscopically occult neoplasias in Barrett's esophagus: are random biopsies dispensable in the era of advanced endoscopic imaging? *Am J Gastroenterol* 2010; **105**: 2350-2356 [PMID: 20664531 DOI: 10.1038/ajg.2010.280]
- 83 **Bhandari P**, Kandaswamy P, Cowlshaw D, Longcroft-Wheaton G. Acetic acid-enhanced chromoendoscopy is more cost-effective than protocol-guided biopsies in a high-risk Barrett's population. *Dis Esophagus* 2012; **25**: 386-392 [PMID: 21981061 DOI: 10.1111/j.1442-2050.2011.01267.x]
- 84 **Sharma P**, Meining AR, Coron E, Lightdale CJ, Wolfsen HC, Bansal A, Bajbouj M, Galmiche JP, Abrams JA, Rastogi A, Gupta N, Michalek JE, Lauwers GY, Wallace MB. Real-time increased detection of neoplastic tissue in Barrett's esophagus with probe-based confocal laser endomicroscopy: final results of an international multicenter, prospective, randomized, controlled trial. *Gastrointest Endosc* 2011; **74**: 465-472 [PMID: 21741642 DOI: 10.1016/j.gie.2011.04.004]
- 85 **Canto MI**, Anandasabapathy S, Brugge W, Falk GW, Dunbar KB, Zhang Z, Woods K, Almario JA, Schell U, Goldblum J, Maitra A, Montgomery E, Kiesslich R. In vivo endomicroscopy improves detection of Barrett's esophagus-related neoplasia: a multicenter international randomized controlled trial (with video). *Gastrointest Endosc* 2014; **79**: 211-221 [PMID: 24219822 DOI: 10.1016/j.gie.2013.09.020]
- 86 **Bird-Lieberman EL**, Neves AA, Lao-Sirieix P, O'Donovan M, Novelli M, Lovat LB, Eng WS, Mahal LK, Brindle KM, Fitzgerald RC. Molecular imaging using fluorescent lectins permits rapid endoscopic identification of dysplasia in Barrett's esophagus. *Nat Med* 2012; **18**: 315-321 [PMID: 22245781 DOI: 10.1038/nm.2616]
- 87 **Li M**, Anastasiades CP, Joshi B, Komarck CM, Piraka C, Elmunzer BJ, Turgeon DK, Johnson TD, Appelman H, Beer DG, Wang TD. Affinity peptide for targeted detection of dysplasia in Barrett's esophagus. *Gastroenterology* 2010; **139**: 1472-1480 [PMID: 20637198 DOI: 10.1053/j.gastro.2010.07.007]
- 88 **Sturm MB**, Joshi BP, Lu S, Piraka C, Khondee S, Elmunzer BJ, Kwon RS, Beer DG, Appelman HD, Turgeon DK, Wang TD. Targeted imaging of esophageal neoplasia with a fluorescently labeled peptide: first-in-human results. *Sci Transl Med* 2013; **5**: 184ra61 [PMID: 23658246 DOI: 10.1126/scitranslmed.3004733]
- 89 **Bhat SK**, McManus DT, Coleman HG, Johnston BT, Cardwell CR, McMenamin U, Bannon F, Hicks B, Kennedy G, Gavin AT, Murray LJ. Oesophageal adenocarcinoma and prior diagnosis of Barrett's oesophagus: a population-based study. *Gut* 2015; **64**: 20-25 [PMID: 24700439 DOI: 10.1136/gutjnl-2013-305506]
- 90 **Bennett C**, Moayyedi P, Corley DA, DeCaestecker J, Falck-Ytter Y, Falk G, Vakil N, Sanders S, Vieth M, Inadomi J, Aldulaimi D, Ho KY, Odze R, Meltzer SJ, Quigley E, Gittens S, Watson P, Zaninotto G, Iyer PG, Alexandre L, Ang Y, Callaghan J, Harrison R, Singh R, Bhandari P, Bisschops R, Geramizadeh B, Kaye P, Krishnadath S, Fennerty MB, Manner H, Nason KS, Pech O, Konda V, Raganath

- K, Rahman I, Romero Y, Sampliner R, Siersema PD, Tack J, Tham TC, Trudgill N, Weinberg DS, Wang J, Wang K, Wong JY, Attwood S, Malfertheiner P, MacDonald D, Barr H, Ferguson MK, Jankowski J. BOB CAT: A Large-Scale Review and Delphi Consensus for Management of Barrett's Esophagus With No Dysplasia, Indefinite for, or Low-Grade Dysplasia. *Am J Gastroenterol* 2015; **110**: 662-682; quiz 683 [PMID: 25869390 DOI: 10.1038/ajg.2015.55]
- 91 **Alashkar B**, Faulx AL, Hepner A, Pulice R, Vemana S, Greer KB, Isenberg GA, Falck-Ytter Y, Chak A. Development of a program to train physician extenders to perform transnasal esophagoscopy and screen for Barrett's esophagus. *Clin Gastroenterol Hepatol* 2014; **12**: 785-792 [PMID: 24161352 DOI: 10.1016/j.cgh.2013.10.014]
- 92 **Shariff MK**, Bird-Lieberman EL, O'Donovan M, Abdullahi Z, Liu X, Blazeby J, Fitzgerald R. Randomized crossover study comparing efficacy of transnasal endoscopy with that of standard endoscopy to detect Barrett's esophagus. *Gastrointest Endosc* 2012; **75**: 954-961 [PMID: 22421496 DOI: 10.1016/j.gie.2012.01.029]
- 93 **Kadri SR**, Lao-Sirieix P, O'Donovan M, DeBiram I, Das M, Blazeby JM, Emery J, Boussioutas A, Morris H, Walter FM, Pharoah P, Hardwick RH, Fitzgerald RC. Acceptability and accuracy of a non-endoscopic screening test for Barrett's oesophagus in primary care: cohort study. *BMJ* 2010; **341**: e4372 [PMID: 20833740 DOI: 10.1136/bmj.e4372]
- 94 **Lao-Sirieix P**, Boussioutas A, Kadri SR, O'Donovan M, DeBiram I, Das M, Harihar L, Fitzgerald RC. Non-endoscopic screening biomarkers for Barrett's esophagus: from microarray analysis to the clinic. *Gut* 2009; **58**: 1451-1459 [PMID: 19651633 DOI: 10.1136/gut.2009.180281]
- 95 **Benaglia T**, Sharples LD, Fitzgerald RC, Lyratzopoulos G. Health benefits and cost effectiveness of endoscopic and nonendoscopic cytosponge screening for Barrett's esophagus. *Gastroenterology* 2013; **144**: 62-73.e6 [PMID: 23041329 DOI: 10.1053/j.gastro.2012.09.060]
- 96 **Thrift AP**, Garcia JM, El-Serag HB. A multibiomarker risk score helps predict risk for Barrett's esophagus. *Clin Gastroenterol Hepatol* 2014; **12**: 1267-1271 [PMID: 24362047 DOI: 10.1016/j.cgh.2013.12.014]
- 97 **Corley DA**, Levin TR, Habel LA, Weiss NS, Buffler PA. Surveillance and survival in Barrett's adenocarcinomas: a population-based study. *Gastroenterology* 2002; **122**: 633-640 [PMID: 11874995 DOI: 10.1053/gast.2002.31879]
- 98 **Aldulaimi DM**, Cox M, Nwokolo CU, Loft DE. Barrett's surveillance is worthwhile and detects curable cancers. A prospective cohort study addressing cancer incidence, treatment outcome and survival. *Eur J Gastroenterol Hepatol* 2005; **17**: 943-950 [PMID: 16093872 DOI: 10.1097/00042737-200509000-00010]
- 99 **Gaddam S**, Singh M, Balasubramanian G, Thota P, Gupta N, Wani S, Higbee AD, Mathur SC, Horwath JD, Rastogi A, Young PE, Cash BD, Bansal A, Vargo JJ, Falk GW, Lieberman DA, Sampliner RE, Sharma P. Persistence of nondysplastic Barrett's esophagus identifies patients at lower risk for esophageal adenocarcinoma: results from a large multicenter cohort. *Gastroenterology* 2013; **145**: 548-553.e1 [PMID: 23714382 DOI: 10.1053/j.gastro.2013.05.040]
- 100 **Evans JA**, Early DS, Fukami N, Ben-Menachem T, Chandrasekhara V, Chathadi KV, Decker GA, Fanelli RD, Fisher DA, Foley KQ, Hwang JH, Jain R, Jue TL, Khan KM, Lightdale J, Malpas PM, Maple JT, Pasha SF, Saltzman JR, Sharaf RN, Shergill A, Dornitz JA, Cash BD. The role of endoscopy in Barrett's esophagus and other premalignant conditions of the esophagus. *Gastrointest Endosc* 2012; **76**: 1087-1094 [PMID: 23164510 DOI: 10.1016/j.gie.2012.08.004]
- 101 **Shaheen NJ**, Weinberg DS, Denberg TD, Chou R, Qaseem A, Shekelle P. Upper endoscopy for gastroesophageal reflux disease: best practice advice from the clinical guidelines committee of the American College of Physicians. *Ann Intern Med* 2012; **157**: 808-816 [PMID: 23208168 DOI: 10.7326/0003-4819-157-11-201212040-00008]
- 102 **Horvath B**, Singh P, Xie H, Thota PN, Allende DS, Pai RK, Patil DT, Plessec TP, Goldblum JR, Liu X. Risk for esophageal neoplasia in Barrett's esophagus patients with mucosal changes indefinite for dysplasia. *J Gastroenterol Hepatol* 2015; **30**: 262-267 [PMID: 25087917 DOI: 10.1111/jgh.12696]
- 103 **Younes M**, Lauwers GY, Ertan A, Ergun G, Verm R, Bridges M, Woods K, Meriano F, Schmulen C, Johnson C, Barroso A, Schwartz J, McKechnie J, Lechago J. The significance of "indefinite for dysplasia" grading in Barrett metaplasia. *Arch Pathol Lab Med* 2011; **135**: 430-432 [PMID: 21466357 DOI: 10.1043/2010-0097-OA.1]
- 104 **Singh S**, Manickam P, Amin AV, Samala N, Schouten LJ, Iyer PG, Desai TK. Incidence of esophageal adenocarcinoma in Barrett's esophagus with low-grade dysplasia: a systematic review and meta-analysis. *Gastrointest Endosc* 2014; **79**: 897-909.e4; quiz 983.e1, 983.e3 [PMID: 24556051 DOI: 10.1016/j.gie.2014.01.009]
- 105 **Wani S**, Falk GW, Post J, Yerian L, Hall M, Wang A, Gupta N, Gaddam S, Singh M, Singh V, Chuang KY, Boolchand V, Gavini H, Kuczynski J, Sud P, Bansal A, Rastogi A, Mathur SC, Young P, Cash B, Goldblum J, Lieberman DA, Sampliner RE, Sharma P. Risk factors for progression of low-grade dysplasia in patients with Barrett's esophagus. *Gastroenterology* 2011; **141**: 1179-1186, 1186.e1 [PMID: 21723218 DOI: 10.1053/j.gastro.2011.06.055]
- 106 **Kaye PV**, Haider SA, Ilyas M, James PD, Soomro I, Faisal W, Catton J, Parsons SL, Ragunath K. Barrett's dysplasia and the Vienna classification: reproducibility, prediction of progression and impact of consensus reporting and p53 immunohistochemistry. *Histopathology* 2009; **54**: 699-712 [PMID: 19438745 DOI: 10.1111/j.1365-2559.2009.03288.x]
- 107 **Duits LC**, Phoa KN, Curvers WL, Ten Kate FJ, Meijer GA, Seldenrijk CA, Offerhaus GJ, Visser M, Meijer SL, Krishnadath KK, Tijssen JG, Mallant-Hent RC, Bergman JJ. Barrett's oesophagus patients with low-grade dysplasia can be accurately risk-stratified after histological review by an expert pathology panel. *Gut* 2015; **64**: 700-706 [PMID: 25034523 DOI: 10.1136/gutjnl-2014-307278]
- 108 **Abdalla M**, Dhanekula R, Greenspan M, Mobarhan S, Patil A, Jakate S, Giusto D, Silva R, Li H, Melson J. Dysplasia detection rate of confirmatory EGD in nondysplastic Barrett's esophagus. *Dis Esophagus* 2014; **27**: 505-510 [PMID: 23020509 DOI: 10.1111/j.1442-2050.2012.01431.x]
- 109 **Brown CS**, Lapin B, Wang C, Goldstein JL, Linn JG, Denham W, Haggerty SP, Talamonti MS, Howington JA, Carbray J, Ujiki MB. Reflux control is important in the management of Barrett's Esophagus: results from a retrospective 1,830 patient cohort. *Surg Endosc* 2015; **29**: 3528-3534 [PMID: 25676204 DOI: 10.1007/s00464-015-4103-3]
- 110 **Singh S**, Garg SK, Singh PP, Iyer PG, El-Serag HB. Acid-suppressive medications and risk of oesophageal adenocarcinoma in patients with Barrett's oesophagus: a systematic review and meta-analysis. *Gut* 2014; **63**: 1229-1237 [PMID: 24221456 DOI: 10.1136/gutjnl-2013-305997]
- 111 **Islami F**, Kamangar F, Boffetta P. Use of proton pump inhibitors and risk of progression of Barrett's esophagus to neoplastic lesions. *Am J Gastroenterol* 2009; **104**: 2646-2648 [PMID: 19806109 DOI: 10.1038/ajg.2009.369]
- 112 **Ouatu-Lascar R**, Fitzgerald RC, Triadafilopoulos G. Differentiation and proliferation in Barrett's esophagus and the effects of acid suppression. *Gastroenterology* 1999; **117**: 327-335 [PMID: 10419913]
- 113 **de Bortoli N**, Martinucci I, Piaggi P, Maltinti S, Bianchi G, Ciancia E, Gambaccini D, Lenzi F, Costa F, Leonardi G, Ricchiuti A, Mumolo MG, Bellini M, Blandizzi C, Marchi S. Randomised clinical trial: twice dailyesomeprazole 40 mg vs. pantoprazole 40 mg in Barrett's oesophagus for 1 year. *Aliment Pharmacol Ther* 2011; **33**: 1019-1027 [PMID: 21385192 DOI: 10.1111/j.1365-2036.2011.04616.x]
- 114 **Kedika RR**, Souza RF, Spechler SJ. Potential anti-inflammatory effects of proton pump inhibitors: a review and discussion of the clinical implications. *Dig Dis Sci* 2009; **54**: 2312-2317 [PMID: 19714466 DOI: 10.1007/s10620-009-0951-9]
- 115 **Nguyen DM**, Richardson P, El-Serag HB. Medications (NSAIDs, statins, proton pump inhibitors) and the risk of esophageal adenocarcinoma in patients with Barrett's esophagus. *Gastroenterology* 2010; **138**: 2260-2266 [PMID: 20188100 DOI: 10.1053/j.gastro.2010.02.045]

- 116 **Richter JE**, Penagini R, Tenca A, Pohl D, Dvorak K, Goldman A, Savarino E, Zentilin P, Savarino V, Watson JT, Wong RK, Pace F, Casini V, Peura DA, Herzog SJ, Kamiya T, Pelosini I, Scarpignato C, Armstrong D, DeVault KR, Bechi P, Taddei A, Freschi G, Ringressi MN, Degli'Innocenti DR, Castiglione F, Masini E, Hunt RH. Barrett's esophagus: proton pump inhibitors and chemoprevention II. *Ann N Y Acad Sci* 2011; **1232**: 114-139 [PMID: 21950810 DOI: 10.1111/j.1749-6632.2011.06048.x]
- 117 **Das D**, Chilton AP, Jankowski JA. Chemoprevention of oesophageal cancer and the AspECT trial. *Recent Results Cancer Res* 2009; **181**: 161-169 [PMID: 19213566]
- 118 **Wang KK**, Sampliner RE. Updated guidelines 2008 for the diagnosis, surveillance and therapy of Barrett's esophagus. *Am J Gastroenterol* 2008; **103**: 788-797 [PMID: 18341497 DOI: 10.1111/j.1572-0241.2008.01835.x]
- 119 **Blevins CH**, Iyer PG. Endoscopic therapy for Barrett's oesophagus. *Best Pract Res Clin Gastroenterol* 2015; **29**: 167-177 [PMID: 25743464 DOI: 10.1016/j.bpg.2014.11.007]
- 120 **Bennett C**, Vakil N, Bergman J, Harrison R, Odze R, Vieth M, Sanders S, Gay L, Pech O, Longcroft-Wheaton G, Romero Y, Inadomi J, Tack J, Corley DA, Manner H, Green S, Al Dulaimi D, Ali H, Allum B, Anderson M, Curtis H, Falk G, Fennerty MB, Fullarton G, Krishnadath K, Meltzer SJ, Armstrong D, Ganz R, Cengia G, Going JJ, Goldblum J, Gordon C, Grabsch H, Haigh C, Hongo M, Johnston D, Forbes-Young R, Kay E, Kaye P, Lerut T, Lovat LB, Lundell L, Mairs P, Shimoda T, Spechler S, Sontag S, Malfertheiner P, Murray I, Nanji M, Poller D, Ragnath K, Regula J, Cestari R, Shepherd N, Singh R, Stein HJ, Talley NJ, Galmiche JP, Tham TC, Watson P, Yerian L, Ruge M, Rice TW, Hart J, Gittens S, Hewin D, Hochberger J, Kahrilas P, Preston S, Sampliner R, Sharma P, Stuart R, Wang K, Waxman I, Abley C, Loft D, Penman I, Shaheen NJ, Chak A, Davies G, Dunn L, Falck-Ytter Y, Decaestecker J, Bhandari P, Ell C, Griffin SM, Attwood S, Barr H, Allen J, Ferguson MK, Moayyedi P, Jankowski JA. Consensus statements for management of Barrett's dysplasia and early-stage esophageal adenocarcinoma, based on a Delphi process. *Gastroenterology* 2012; **143**: 336-346 [PMID: 22537613 DOI: 10.1053/j.gastro.2012.04.032]
- 121 **Perry KA**, Enestvedt CK, Pham T, Welker M, Jobe BA, Hunter JG, Sheppard BC. Comparison of laparoscopic inversion esophagectomy and open transhiatal esophagectomy for high-grade dysplasia and stage I esophageal adenocarcinoma. *Arch Surg* 2009; **144**: 679-684 [PMID: 19620549 DOI: 10.1001/archsurg.2009.113]
- 122 **Stahl M**, Mariette C, Haustermans K, Cervantes A, Arnold D. Oesophageal cancer: ESMO Clinical Practice Guidelines for diagnosis, treatment and follow-up. *Ann Oncol* 2013; **24** Suppl 6: vi51-vi56 [PMID: 24078662 DOI: 10.1093/annonc/mdt342]
- 123 **Evans JA**, Early DS, Chandraskhara V, Chathadi KV, Fanelli RD, Fisher DA, Foley KQ, Hwang JH, Jue TL, Pasha SF, Sharaf R, Shergill AK, Dominitz JA, Cash BD. The role of endoscopy in the assessment and treatment of esophageal cancer. *Gastrointest Endosc* 2013; **77**: 328-334 [PMID: 23410694 DOI: 10.1016/j.gie.2012.10.001]
- 124 **Pech O**, Behrens A, May A, Nachbar L, Gossner L, Rabenstein T, Manner H, Guenter E, Huijsmans J, Vieth M, Stolte M, Ell C. Long-term results and risk factor analysis for recurrence after curative endoscopic therapy in 349 patients with high-grade intraepithelial neoplasia and mucosal adenocarcinoma in Barrett's oesophagus. *Gut* 2008; **57**: 1200-1206 [PMID: 18460553 DOI: 10.1136/gut.2007.142539]
- 125 **Prasad GA**, Wu TT, Wigle DA, Buttar NS, Wongkeesong LM, Dunagan KT, Lutzke LS, Borkenhagen LS, Wang KK. Endoscopic and surgical treatment of mucosal (T1a) esophageal adenocarcinoma in Barrett's esophagus. *Gastroenterology* 2009; **137**: 815-823 [PMID: 19524578 DOI: 10.1053/j.gastro.2009.05.059]
- 126 **Das A**, Singh V, Fleischer DE, Sharma VK. A comparison of endoscopic treatment and surgery in early esophageal cancer: an analysis of surveillance epidemiology and end results data. *Am J Gastroenterol* 2008; **103**: 1340-1345 [PMID: 18510606 DOI: 10.1111/j.1572-0241.2008.01889.x]
- 127 **Zehetner J**, DeMeester SR, Hagen JA, Ayazi S, Augustin F, Lipham JC, DeMeester TR. Endoscopic resection and ablation versus esophagectomy for high-grade dysplasia and intramucosal adenocarcinoma. *J Thorac Cardiovasc Surg* 2011; **141**: 39-47 [PMID: 21055772 DOI: 10.1016/j.jtcvs.2010.08.058]
- 128 **Wani S**, Mathur SC, Curvers WL, Singh V, Alvarez Herrero L, Hall SB, Uluarac O, Cherian R, McGregor DH, Bansal A, Rastogi A, Ahmed B, Singh M, Gaddam S, Ten Kate FJ, Bergman J, Sharma P. Greater interobserver agreement by endoscopic mucosal resection than biopsy samples in Barrett's dysplasia. *Clin Gastroenterol Hepatol* 2010; **8**: 783-788 [PMID: 20472096 DOI: 10.1016/j.cgh.2010.04.028]
- 129 **Wani S**, Abrams J, Edmundowicz SA, Gaddam S, Hovis CE, Green D, Gupta N, Higbee A, Bansal A, Rastogi A, Early D, Lightdale CJ, Sharma P. Endoscopic mucosal resection results in change of histologic diagnosis in Barrett's esophagus patients with visible and flat neoplasia: a multicenter cohort study. *Dig Dis Sci* 2013; **58**: 1703-1709 [PMID: 23633158 DOI: 10.1007/s10620-013-2689-7]
- 130 **Mino-Kenudson M**, Hull MJ, Brown I, Muzikansky A, Srivastava A, Glickman J, Park DY, Zuckerberg L, Misdraji J, Odze RD, Lauwers GY. EMR for Barrett's esophagus-related superficial neoplasms offers better diagnostic reproducibility than mucosal biopsy. *Gastrointest Endosc* 2007; **66**: 660-666; quiz 767, 769 [PMID: 17905005 DOI: 10.1016/j.gie.2007.02.063]
- 131 **Leggett CL**, Lewis JT, Wu TT, Schleck CD, Zinsmeister AR, Dunagan KT, Lutzke LS, Wang KK, Iyer PG. Clinical and histologic determinants of mortality for patients with Barrett's esophagus-related T1 esophageal adenocarcinoma. *Clin Gastroenterol Hepatol* 2015; **13**: 658-664.e1-3 [PMID: 25151255 DOI: 10.1016/j.cgh.2014.08.016]
- 132 **Davila ML**, Hofstetter WL. Endoscopic management of Barrett's esophagus with high-grade dysplasia and early-stage esophageal adenocarcinoma. *Thorac Surg Clin* 2013; **23**: 479-489 [PMID: 24199698 DOI: 10.1016/j.thorsurg.2013.07.010]
- 133 **Spechler SJ**, Sharma P, Souza RF, Inadomi JM, Shaheen NJ. American Gastroenterological Association technical review on the management of Barrett's esophagus. *Gastroenterology* 2011; **140**: e18-52; quiz e13 [PMID: 21376939 DOI: 10.1053/j.gastro.2011.01.031]
- 134 **Pouw RE**, van Vilsteren FG, Peters FP, Alvarez Herrero L, Ten Kate FJ, Visser M, Schenk BE, Schoon EJ, Peters FT, Houben M, Bisschops R, Weusten BL, Bergman JJ. Randomized trial on endoscopic resection-cap versus multiband mucosectomy for piecemeal endoscopic resection of early Barrett's neoplasia. *Gastrointest Endosc* 2011; **74**: 35-43 [PMID: 21704807 DOI: 10.1016/j.gie.2011.03.1243]
- 135 **Ell C**, May A, Pech O, Gossner L, Guenter E, Behrens A, Nachbar L, Huijsmans J, Vieth M, Stolte M. Curative endoscopic resection of early esophageal adenocarcinomas (Barrett's cancer). *Gastrointest Endosc* 2007; **65**: 3-10 [PMID: 17185072 DOI: 10.1016/j.gie.2006.04.033]
- 136 **May A**, Gossner L, Pech O, Fritz A, Günter E, Mayer G, Müller H, Seitz G, Vieth M, Stolte M, Ell C. Local endoscopic therapy for intraepithelial high-grade neoplasia and early adenocarcinoma in Barrett's oesophagus: acute-phase and intermediate results of a new treatment approach. *Eur J Gastroenterol Hepatol* 2002; **14**: 1085-1091 [PMID: 12362099]
- 137 **Pech O**, May A, Manner H, Behrens A, Pohl J, Weferling M, Hartmann U, Manner N, Huijsmans J, Gossner L, Rabenstein T, Vieth M, Stolte M, Ell C. Long-term efficacy and safety of endoscopic resection for patients with mucosal adenocarcinoma of the esophagus. *Gastroenterology* 2014; **146**: 652-660.e1 [PMID: 24269290 DOI: 10.1053/j.gastro.2013.11.006]
- 138 **Moss A**, Bourke MJ, Hourigan LF, Gupta S, Williams SJ, Tran K, Swan MP, Hopper AD, Kwan V, Bailey AA. Endoscopic resection for Barrett's high-grade dysplasia and early esophageal adenocarcinoma: an essential staging procedure with long-term therapeutic benefit. *Am J Gastroenterol* 2010; **105**: 1276-1283 [PMID: 20179694 DOI: 10.1038/ajg.2010.1]
- 139 **Gerke H**, Siddiqui J, Nasr I, Van Handel DM, Jensen CS. Efficacy and safety of EMR to completely remove Barrett's esophagus:

- experience in 41 patients. *Gastrointest Endosc* 2011; **74**: 761-771 [PMID: 21824611 DOI: 10.1016/j.gie.2011.06.009]
- 140 **Yoshinaga S**, Gotoda T, Kusano C, Oda I, Nakamura K, Takayanagi R. Clinical impact of endoscopic submucosal dissection for superficial adenocarcinoma located at the esophagogastric junction. *Gastrointest Endosc* 2008; **67**: 202-209 [PMID: 18226681 DOI: 10.1016/j.gie.2007.09.054]
- 141 **Teoh AY**, Chiu PW, Yu Ngo DK, Wong SK, Lau JY, Ng EK. Outcomes of endoscopic submucosal dissection versus endoscopic mucosal resection in management of superficial squamous esophageal neoplasms outside Japan. *J Clin Gastroenterol* 2010; **44**: e190-e194 [PMID: 20844363 DOI: 10.1097/MCG.0b013e3181ce52fb]
- 142 **Repici A**, Hassan C, Carlino A, Pagano N, Zullo A, Rando G, Strangio G, Romeo F, Nicita R, Rosati R, Malesci A. Endoscopic submucosal dissection in patients with early esophageal squamous cell carcinoma: results from a prospective Western series. *Gastrointest Endosc* 2010; **71**: 715-721 [PMID: 20363414 DOI: 10.1016/j.gie.2009.11.020]
- 143 **Chennat J**, Konda VJ, Ross AS, de Tejada AH, Noffsinger A, Hart J, Lin S, Ferguson MK, Posner MC, Waxman I. Complete Barrett's eradication endoscopic mucosal resection: an effective treatment modality for high-grade dysplasia and intramucosal carcinoma--an American single-center experience. *Am J Gastroenterol* 2009; **104**: 2684-2692 [PMID: 19690526 DOI: 10.1038/ajg.2009.465]
- 144 **Hashimoto S**, Kobayashi M, Takeuchi M, Sato Y, Narisawa R, Aoyagi Y. The efficacy of endoscopic triamcinolone injection for the prevention of esophageal stricture after endoscopic submucosal dissection. *Gastrointest Endosc* 2011; **74**: 1389-1393 [PMID: 22136782 DOI: 10.1016/j.gie.2011.07.070]
- 145 **Shaheen NJ**, Sharma P, Overholt BF, Wolfsen HC, Sampliner RE, Wang KK, Galanko JA, Bronner MP, Goldblum JR, Bennett AE, Jobe BA, Eisen GM, Fennerty MB, Hunter JG, Fleischer DE, Sharma VK, Hawes RH, Hoffman BJ, Rothstein RI, Gordon SR, Mashimo H, Chang KJ, Muthusamy VR, Edmundowicz SA, Spechler SJ, Siddiqui AA, Souza RF, Infantolino A, Falk GW, Kimmey MB, Madanick RD, Chak A, Lightdale CJ. Radiofrequency ablation in Barrett's esophagus with dysplasia. *N Engl J Med* 2009; **360**: 2277-2288 [PMID: 19474425 DOI: 10.1056/NEJMoa0808145]
- 146 **Shaheen NJ**, Overholt BF, Sampliner RE, Wolfsen HC, Wang KK, Fleischer DE, Sharma VK, Eisen GM, Fennerty MB, Hunter JG, Bronner MP, Goldblum JR, Bennett AE, Mashimo H, Rothstein RI, Gordon SR, Edmundowicz SA, Madanick RD, Peery AF, Muthusamy VR, Chang KJ, Kimmey MB, Spechler SJ, Siddiqui AA, Souza RF, Infantolino A, Dumot JA, Falk GW, Galanko JA, Jobe BA, Hawes RH, Hoffman BJ, Sharma P, Chak A, Lightdale CJ. Durability of radiofrequency ablation in Barrett's esophagus with dysplasia. *Gastroenterology* 2011; **141**: 460-468 [PMID: 21679712 DOI: 10.1053/j.gastro.2011.04.061]
- 147 **Phoa KN**, van Vilsteren FG, Weusten BL, Bisschops R, Schoon EJ, Ragnunath K, Fullarton G, Di Pietro M, Ravi N, Visser M, Offerhaus GJ, Seldenrijk CA, Meijer SL, ten Kate FJ, Tijssen JG, Bergman JJ. Radiofrequency ablation vs endoscopic surveillance for patients with Barrett esophagus and low-grade dysplasia: a randomized clinical trial. *JAMA* 2014; **311**: 1209-1217 [PMID: 24668102 DOI: 10.1001/jama.2014.2511]
- 148 **Orman ES**, Li N, Shaheen NJ. Efficacy and durability of radiofrequency ablation for Barrett's Esophagus: systematic review and meta-analysis. *Clin Gastroenterol Hepatol* 2013; **11**: 1245-1255 [PMID: 23644385 DOI: 10.1016/j.cgh.2013.03.039]
- 149 **Bulsiewicz WJ**, Kim HP, Dellon ES, Cotton CC, Pasricha S, Madanick RD, Spacek MB, Bream SE, Chen X, Orlando RC, Shaheen NJ. Safety and efficacy of endoscopic mucosal therapy with radiofrequency ablation for patients with neoplastic Barrett's esophagus. *Clin Gastroenterol Hepatol* 2013; **11**: 636-642 [PMID: 23103824 DOI: 10.1016/j.cgh.2012.10.028]
- 150 **Prasad GA**, Wang KK, Halling KC, Buttar NS, Wongkeesong LM, Zinsmeister AR, Brankley SM, Fritcher EG, Westra WM, Krishnadath KK, Lutzke LS, Borkenhagen LS. Utility of biomarkers in prediction of response to ablative therapy in Barrett's esophagus. *Gastroenterology* 2008; **135**: 370-379 [PMID: 18538141 DOI: 10.1053/j.gastro.2008.04.036]
- 151 **Krishnan K**, Pandolfino JE, Kahrilas PJ, Keefer L, Boris L, Komanduri S. Increased risk for persistent intestinal metaplasia in patients with Barrett's esophagus and uncontrolled reflux exposure before radiofrequency ablation. *Gastroenterology* 2012; **143**: 576-581 [PMID: 22609385 DOI: 10.1053/j.gastro.2012.05.005]
- 152 **Timmer MR**, Brankley SM, Gorospe EC, Sun G, Lutzke LS, Iyer PG, Halling KC, Krishnadath KK, Wang KK. Prediction of response to endoscopic therapy of Barrett's dysplasia by using genetic biomarkers. *Gastrointest Endosc* 2014; **80**: 984-991 [PMID: 25085335 DOI: 10.1016/j.gie.2014.06.023]
- 153 **Gray NA**, Odze RD, Spechler SJ. Buried metaplasia after endoscopic ablation of Barrett's esophagus: a systematic review. *Am J Gastroenterol* 2011; **106**: 1899-1908; quiz 1909 [PMID: 21826111 DOI: 10.1038/ajg.2011.255]
- 154 **Gupta N**, Mathur SC, Dumot JA, Singh V, Gaddam S, Wani SB, Bansal A, Rastogi A, Goldblum JR, Sharma P. Adequacy of esophageal squamous mucosa specimens obtained during endoscopy: are standard biopsies sufficient for postablation surveillance in Barrett's esophagus? *Gastrointest Endosc* 2012; **75**: 11-18 [PMID: 21907985 DOI: 10.1016/j.gie.2011.06.040]
- 155 **Dulai PS**, Pohl H, Levenick JM, Gordon SR, MacKenzie TA, Rothstein RI. Radiofrequency ablation for long- and ultralong-segment Barrett's esophagus: a comparative long-term follow-up study. *Gastrointest Endosc* 2013; **77**: 534-541 [PMID: 23290719 DOI: 10.1016/j.gie.2012.10.021]
- 156 **Gosain S**, Mercer K, Twaddell WS, Uradomo L, Greenwald BD. Liquid nitrogen spray cryotherapy in Barrett's esophagus with high-grade dysplasia: long-term results. *Gastrointest Endosc* 2013; **78**: 260-265 [PMID: 23622979 DOI: 10.1016/j.gie.2013.03.002]
- 157 **Fuchs KH**, Babic B, Breithaupt W, Dallemagne B, Fingerhut A, Furnee E, Granderath F, Horvath P, Kardos P, Pointner R, Savarino E, Van Herwaarden-Lindeboom M, Zaninotto G. EAES recommendations for the management of gastroesophageal reflux disease. *Surg Endosc* 2014; **28**: 1753-1773 [PMID: 24789125 DOI: 10.1007/s00464-014-3431-z]
- 158 **Galmiche JP**, Hatlebakk J, Attwood S, Ell C, Fiocca R, Eklund S, Långström G, Lind T, Lundell L. Laparoscopic antireflux surgery vs esomeprazole treatment for chronic GERD: the LOTUS randomized clinical trial. *JAMA* 2011; **305**: 1969-1977 [PMID: 21586712 DOI: 10.1001/jama.2011.626]
- 159 **Faria R**, Bojke L, Epstein D, Corbacho B, Sculpher M. Cost-effectiveness of laparoscopic fundoplication versus continued medical management for the treatment of gastro-oesophageal reflux disease based on long-term follow-up of the REFLUX trial. *Br J Surg* 2013; **100**: 1205-1213 [PMID: 23775366 DOI: 10.1002/bjs.9190]
- 160 **Strate U**, Emmermann A, Fibbe C, Layer P, Zornig C. Laparoscopic fundoplication: Nissen versus Toupet two-year outcome of a prospective randomized study of 200 patients regarding preoperative esophageal motility. *Surg Endosc* 2008; **22**: 21-30 [PMID: 18027055 DOI: 10.1007/s00464-007-9546-8]
- 161 **Zornig C**, Strate U, Fibbe C, Emmermann A, Layer P. Nissen vs Toupet laparoscopic fundoplication. *Surg Endosc* 2002; **16**: 758-766 [PMID: 11997817 DOI: 10.1007/s00464-001-9092-8]
- 162 **Patti MG**, Robinson T, Galvani C, Gorodner MV, Fischella PM, Way LW. Total fundoplication is superior to partial fundoplication even when esophageal peristalsis is weak. *J Am Coll Surg* 2004; **198**: 863-869; discussion 869-870 [PMID: 15194064 DOI: 10.1016/j.jamcollsurg.2004.01.029]
- 163 **Dallemagne B**, Weerts J, Markiewicz S, Dewandre JM, Wahlen C, Monami B, Jehaes C. Clinical results of laparoscopic fundoplication at ten years after surgery. *Surg Endosc* 2006; **20**: 159-165 [PMID: 16333553 DOI: 10.1007/s00464-005-0174-x]
- 164 **Fein M**, Bueter M, Thalheimer A, Pachmayr V, Heimbucher J, Freys SM, Fuchs KH. Less reflux recurrence following Nissen fundoplication: results of laparoscopic antireflux surgery after 10 years. *Chirurg* 2008; **79**: 759-764 [PMID: 18496658 DOI: 10.1007/s00104-008-1532-8]
- 165 **Attwood SE**, Lundell L, Hatlebakk JG, Eklund S, Junghard



- O, Galmiche JP, Ell C, Fiocca R, Lind T. Medical or surgical management of GERD patients with Barrett's esophagus: the LOTUS trial 3-year experience. *J Gastrointest Surg* 2008; **12**: 1646-1654; discussion 1654-1655 [PMID: 18709511 DOI: 10.1007/s11605-008-0645-1]
- 166 **Caygill CP**, Watson A, Lao-Sirieix P, Fitzgerald RC. Barrett's oesophagus and adenocarcinoma. *World J Surg Oncol* 2004; **2**: 12 [PMID: 15132744 DOI: 10.1186/1477-7819-2-12]
- 167 **Avidan B**, Sonnenberg A, Schnell TG, Chejfec G, Metz A, Sontag SJ. Hiatal hernia size, Barrett's length, and severity of acid reflux are all risk factors for esophageal adenocarcinoma. *Am J Gastroenterol* 2002; **97**: 1930-1936 [PMID: 12190156 DOI: 10.1111/j.1572-0241.2002.05902.x]
- 168 **Rossi M**, Barreca M, de Bortoli N, Renzi C, Santi S, Gennai A, Bellini M, Costa F, Conio M, Marchi S. Efficacy of Nissen fundoplication versus medical therapy in the regression of low-grade dysplasia in patients with Barrett esophagus: a prospective study. *Ann Surg* 2006; **243**: 58-63 [PMID: 16371737]
- 169 **Zaninotto G**, Parente P, Salvador R, Farinati F, Tieppo C, Passuello N, Zanatta L, Fassan M, Cavallin F, Costantini M, Mescoli C, Battaglia G, Ruol A, Ancona E, Rugge M. Long-term follow-up of Barrett's epithelium: medical versus antireflux surgical therapy. *J Gastrointest Surg* 2012; **16**: 7-14; discussion 14-15 [PMID: 22086718 DOI: 10.1007/s11605-011-1739-8]
- 170 **Chang EY**, Morris CD, Seltman AK, O'Rourke RW, Chan BK, Hunter JG, Jobe BA. The effect of antireflux surgery on esophageal carcinogenesis in patients with barrett esophagus: a systematic review. *Ann Surg* 2007; **246**: 11-21 [PMID: 17592284 DOI: 10.1097/01.sla.0000261459.10565.e9]
- 171 **Corey KE**, Schmitz SM, Shaheen NJ. Does a surgical antireflux procedure decrease the incidence of esophageal adenocarcinoma in Barrett's esophagus? A meta-analysis. *Am J Gastroenterol* 2003; **98**: 2390-2394 [PMID: 14638338 DOI: 10.1111/j.1572-0241.2003.08702.x]
- 172 **Löfdahl HE**, Lu Y, Lagergren P, Lagergren J. Risk factors for esophageal adenocarcinoma after antireflux surgery. *Ann Surg* 2013; **257**: 579-582 [PMID: 23426349 DOI: 10.1097/SLA.0b013e3182888384]
- 173 **Sjoquist KM**, Burmeister BH, Smithers BM, Zalcberg JR, Simes RJ, Barbour A, GebSKI V. Survival after neoadjuvant chemotherapy or chemoradiotherapy for resectable oesophageal carcinoma: an updated meta-analysis. *Lancet Oncol* 2011; **12**: 681-692 [PMID: 21684205 DOI: 10.1016/S1470-2045(11)70142-5]
- 174 **Ford AC**, Forman D, Reynolds PD, Cooper BT, Moayyedi P. Ethnicity, gender, and socioeconomic status as risk factors for esophagitis and Barrett's esophagus. *Am J Epidemiol* 2005; **162**: 454-460 [PMID: 16076833 DOI: 10.1093/aje/kwi218]
- 175 **Conio M**, Filiberti R, Bianchi S, Ferraris R, Marchi S, Ravelli P, Lapertosa G, Iaquinto G, Sablich R, Gusmaroli R, Aste H, Giacosa A. Risk factors for Barrett's esophagus: a case-control study. *Int J Cancer* 2002; **97**: 225-229 [PMID: 11774268 DOI: 10.1002/ijc.1583]
- 176 **Zagari RM**, Fuccio L, Wallander MA, Johansson S, Fiocca R, Casanova S, Farahmand BY, Winchester CC, Roda E, Bazzoli F. Gastro-oesophageal reflux symptoms, oesophagitis and Barrett's oesophagus in the general population: the Loiano-Monghidoro study. *Gut* 2008; **57**: 1354-1359 [PMID: 18424568 DOI: 10.1136/gut.2007.145177]
- 177 **Conio M**, Bianchi S, Lapertosa G, Ferraris R, Sablich R, Marchi S, D'Onofrio V, Lacchin T, Iaquinto G, Missale G, Ravelli P, Cestari R, Benedetti G, Macri G, Fiocca R, Munizzi F, Filiberti R. Long-term endoscopic surveillance of patients with Barrett's esophagus. Incidence of dysplasia and adenocarcinoma: a prospective study. *Am J Gastroenterol* 2003; **98**: 1931-1939 [PMID: 14499768 DOI: 10.1111/j.1572-0241.2003.07666.x]

**P- Reviewer:** Actis GC, Abdel-Salam O **S- Editor:** Kong JX  
**L- Editor:** A **E- Editor:** Wu HL