



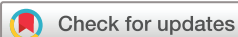ORIGINAL RESEARCH

Understanding the value of non-specific abnormal capillary dilations in presence of Raynaud's phenomenon: a detailed capillaroscopic analysis

Greta Pacini ,¹ Andrea Pogna,¹ Monica Pendolino,¹ Carmen Pizzorni,¹ Luca Carmisciano,² Emanuele Gotelli,¹ Alberto Sulli,¹ Sabrina Paolino,¹ Carlotta Schenone,¹ Vanessa Smith,³ Maurizio Cutolo ¹

To cite: Pacini G, Pogna A, Pendolino M, *et al.* Understanding the value of non-specific abnormal capillary dilations in presence of Raynaud's phenomenon: a detailed capillaroscopic analysis. *RMD Open* 2022;**8**:e002449. doi:10.1136/rmdopen-2022-002449

Received 2 May 2022
Accepted 22 August 2022



© Author(s) or their employer(s) 2022. Re-use permitted under CC BY-NC. No commercial re-use. See rights and permissions. Published by BMJ.

¹Laboratory of Experimental Rheumatology and Academic Division of Rheumatology, Postgraduate School of Rheumatology, Department of Internal Medicine and Specialties, IRCCS Ospedale Policlinico San Martino, Genova, Italy

²BioStatistics Unit, Department of Health Sciences, University of Genoa, Genova, Italy

³Department of Internal Medicine, Department of Rheumatology, University Hospital Ghent, Ghent, Belgium

Correspondence to
Professor Maurizio Cutolo;
mcutolo@unige.it

ABSTRACT

Background Nailfold videocapillaroscopy (NVC) non-specific abnormalities may be present in subjects with isolated Raynaud's phenomenon (RP) before the potential transition to systemic sclerosis (SSc) specific microvascular alterations ('scleroderma pattern'). This study aims to investigate NVC non-specific abnormalities, notably capillary dilations, in RP patients, as possible forerunners of the 'scleroderma pattern'.

Methods A 10-year retrospective NVC-based investigation evaluated 55 RP patients sorted into 3 sex-matched and age-matched groups according to clinical evolution: 18 later developing SSc (cases), 19 later developing other connective tissue disease and 18 maintaining primary RP at long-term follow-up (controls). All patients had a basal NVC showing non-specific abnormalities, namely non-specific >30 µm dilated capillaries (30–50 µm diameter). Sequential NVCs were longitudinally evaluated using current standardised approach. Statistical analysis assessed the risk for developing a 'scleroderma pattern'.

Results Significantly larger capillary diameters were observed in cases versus controls both at basal NVC and during follow-up NVC ($p < 0.05$ to < 0.001). Interestingly, controls showed stable NVC non-specific abnormalities over the study follow-up. The number of >30 µm dilated capillaries/mm at basal NVC was the strongest single predictor of 'scleroderma pattern' evolution with 24% increased risk per each dilated capillary (OR 1.24, 95% CI 1.17, 1.32). Additionally, a tree-based analysis suggested the efferent (venous) diameter of the most dilated capillary on basal NVC as a variable of interest to identify patients maintaining primary RP.

Conclusion This is the first study to describe an NVC 'prescleroderma signature' to potentially identify RP patients later developing a 'scleroderma pattern'.

BACKGROUND

Raynaud's phenomenon (RP) is a complex symptom triggered by an exaggerated microvascular response to cold or other inducers, generally occurring at body extremities.^{1,2} RP is classified as primary (PRP), when occurring

WHAT IS ALREADY KNOWN ON THIS TOPIC

- ⇒ Isolated Raynaud's phenomenon (RP) may evolve in secondary RP during the follow-up.
- ⇒ Nailfold videocapillaroscopy (NVC) non-specific changes might frequently precede 'scleroderma pattern' development.
- ⇒ The evolution from isolated RP towards 'scleroderma pattern' is unlikely when NVC capillary dilations have a 20–30 µm average diameter.

WHAT THIS STUDY ADDS

- ⇒ High rate of NVC capillary dilations with >30 µm average diameter seems a strong predictor of 'scleroderma pattern' in patients with isolated RP.
- ⇒ A large venous diameter may identify those patients maintaining primary RP at a follow-up.

HOW THIS STUDY MIGHT AFFECT RESEARCH, PRACTICE OR POLICY

- ⇒ Non-specific NVC >30 µm capillary dilations may be regarded as a 'prescleroderma signature' in patients assessed for isolated RP.
- ⇒ Quantitative measurement of NVC capillary dilations may improve clinical prediction.

as an isolated phenomenon, or secondary (SRP), when associated to other clinical conditions—typically a connective tissue disease (CTD).^{3,4}

Nailfold videocapillaroscopy (NVC) is a non-invasive, reliable and safe technique, which is currently considered the gold-standard investigation to differentiate PRP from SRP.^{2,5} NVC is performed at the nailfold capillary bed, qualitatively and semiquantitatively assessing ultrastructural microvascular architecture.⁶

For qualitative assessment, specific morphological abnormalities belonging to the 'scleroderma pattern' ('Early', 'Active' and 'Late'

patterns) can be identified, allowing the detection of a systemic sclerosis (SSc)-related SRP.^{7,8} Particularly, NVC has been demonstrated to have strong diagnostic, predictive and prognostic value for SSc, thus being incorporated into the 2013 American College of Rheumatology (ACR)/European Alliance of Associations for Rheumatology (EULAR) classification criteria.^{8–11}

Likewise, non-specific capillaroscopic abnormalities have increasingly been reported in both PRP and other CTDs, as mixed and undifferentiated CTD (MCTD and UCTD), systemic lupus erythematosus (SLE), Sjogren's syndrome and in antiphospholipid syndrome. Importantly, unlike the 'scleroderma pattern', these non-specific abnormalities by themselves are not predictive of any defined condition.^{12–16}

Recently, a consensus definition by the EULAR Study Group on Microcirculation in Rheumatic Diseases (EULAR SG MC/RD) and the Scleroderma Clinical Trial Consortium Group on Capillaroscopy has elaborated a standardised NVC interpretation and a fast-track distinction between 'scleroderma' and 'non-scleroderma patterns'.^{5,17}

Interestingly, since isolated RP is frequently reported as an early manifestation of CTDs, increasing attention has been recently focused on the detection and monitoring of very early NVC alterations as predictive of CTD development over time.^{18,19}

As for SSc, non-specific capillaroscopic abnormalities may be present in subjects with isolated RP before a potential transition to an SRP and the development of an overt 'scleroderma pattern'.^{8,20–23}

The present retrospective investigation aimed to evaluate NVC non-specific abnormalities, namely capillary dilations, in RP patients as possible forerunners of the 'scleroderma pattern' over time.

METHODS

Study population

We performed a retrospective case–control study on the NVC image dataset of RP patients evaluated at the Scleroderma Clinic of the Rheumatology Division of Genova University (Italy) from 2000 to 2020 and undergoing standard diagnostic procedures.

Building on our previous finding that NVC capillary average diameter ≤ 30 micrometre (μm) would have an independent negative predictive value (NPV) for developing a 'scleroderma pattern', only those RP patients with basal NVC showing ≥ 1 capillaries with a 30–50 μm average diameter (from now on referred to as '>30 μm dilated capillaries') were included in the study.²³ As matter of fact, the capillary diameter ≤ 20 μm is by definition considered within normal range and an 'homogeneous' loop dilation >50 μm is a 'giant' capillary, specific feature of the 'scleroderma pattern'.⁵

For case selection, sequential NVCs of 273 RP patients later developing a 'scleroderma pattern' and being

diagnosed with SSc were initially reviewed from the NVC dataset.

Out of that, 18 RP patients were selected as cases having at least one NVC performed before the development of the 'scleroderma pattern' and with non-specific abnormalities, including >30 μm dilated capillaries.

Accordingly, sex-matched and age-matched RP patients (19 later developing other CTDs and 18 with stable PRP at long-term follow-up) having a basal NVC with non-specific abnormalities, including >30 μm dilated capillaries, were selected as controls.

The present retrospective observational non-interventional study was conducted in accordance with the principles of Good Clinical Practices and the Declaration of Helsinki.

All patients underwent clinical and laboratory examinations during the follow-up as part of the standard diagnostic investigation and guidelines approved for RP evaluation.^{3,24}

Informed consent was obtained, as the rule, from all subjects attending the scleroderma clinic during ordinary clinical evaluation and before any NVC examination, as previously approved by the local Ethics Committee.

Clinical data and laboratory tests

RP was diagnosed in presence of repetitive at least biphasic change in the skin colour of the digits induced by cold or stress.²⁵ SSc was diagnosed according to the 2013 ACR/EULAR classification criteria.^{9,26} SLE diagnosis met the 1997 ACR or the 2012 SLICC classification criteria, MCTD diagnosis was made according to either 1987 Sharp's criteria or 1987 Alarcon-Segovia's criteria or 1987 Kasukawa's criteria or 1991 Kahn's criteria, whereas UCTD was diagnosed when not fulfilling criteria for a definite CTD.^{27–32}

For each patient main demographic data, RP clinical features, comorbidities and therapy taken during the follow-up were retrieved from the NVC dataset. At the time of basal NVC, none of the subjects were treated with vasoactive (aminaftone, pentoxifylline, intravenous prostanoids, endothelin receptor antagonists) and/or immunosuppressive drugs (glucocorticoids, hydroxychloroquine, methotrexate, azathioprine, mycophenolate mofetil).

As for laboratory analysis, all patients were tested for antinuclear antibodies using indirect immunofluorescence on Hep-2/liver cells (EUROPLUS ANA Mosaic FA 1510–1), with a 1:80 serum dilution as cut-off value. When appropriate, extractable nuclear antigen antibodies (anti-ENA) and SSc-related Abs were also tested through ELISA (EUROASSAY Anti-ENA ProfilePlus 1 ELISA IgG, EA 1590–1G) and immunoblot (EUROLINE Systemic sclerosis Profile (Nucleoli) DL 1532 G). All tests were performed according to the manufacturer's instructions.³³

NVC analysis

Before the NVC analysis, each subject was acclimatised inside the building for a minimum of 15 min at room temperature of 20°C–22°C. Nailfolds from the second to fifth fingers of both hands were examined in each patient, recording two adjacent nailfold fields of 1 linear millimetre (mm) for each finger (total 16 images). All NVCs were performed by the same operator, using an optical probe with 200X magnification contact lens connected to the storage software (VideoCap 10.00.13 DS Medica Srl, Milan, Italy).

All NVC images were evaluated by a validated qualitative and quantitative assessment using standardised approach stated per consensus by the EULAR SG MC/RD and the Scleroderma Clinical Trial Consortium Group on Capillaroscopy.^{5,17} Retrospective analysis of all NVC images was independently performed by two experts in the field of NVC qualitative and semiquantitative assessment who had no prior clinical information on the evaluated subjects.

Specific ‘scleroderma patterns’ (‘Early’, ‘Active’ and ‘Late’) and ‘scleroderma-like pattern’ were described according to previous definitions.^{34,35}

As for quantitative assessment, capillaries site-specific diameters (arterial, apical, venous) were measured for each image following a semiautomatic procedure. Specifically, the operator manually measured the space between the two parallel layers of the vessel wall, then the software displayed the diameter in μm . The average capillary diameter was calculated as the average of arterial, apical and venous diameters. Accordingly, $>30\ \mu\text{m}$ dilated capillaries were defined as capillary with an average diameter $>30\ \mu\text{m}$ (figure 1).

For the specific purpose of the study, the following variables were recorded for each NVC analysis: (1) total number of capillaries per linear mm, counted at distal row and expressed as average on 16 images; (2) proportion of $>30\ \mu\text{m}$ dilated capillaries, defined as the number of $>30\ \mu\text{m}$ dilated capillaries per linear mm over the total number of capillaries per linear mm, both expressed as

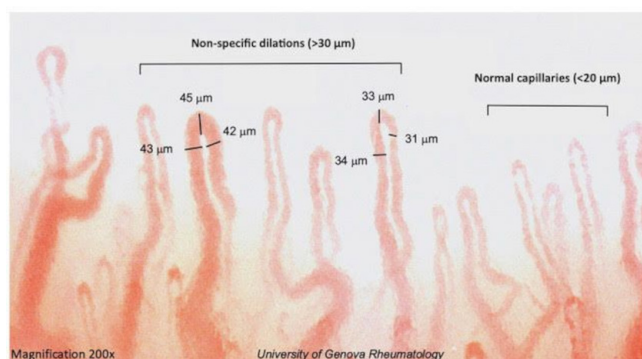


Figure 1 Nailfold videocapillaroscopic image of a Raynaud’s phenomenon patient later developing ‘scleroderma pattern’ and SSc. Image shows both normal capillaries ($<20\ \mu\text{m}$ diameter) and non-specific dilations ($>30\ \mu\text{m}$ diameter). Acquired using VideoCap V.8.14, Ds MediGroup at $\times 200$ magnification. SSc, systemic sclerosis.

average on 16 images, (3) site-specific (arterial, apical and venous) and average diameter of the ‘most dilated capillary’ (MDC) among all $>30\ \mu\text{m}$ dilated capillaries for each image, expressed as average on 16 images, (4) microhaemorrhages, counted as total number on 1 linear mm and expressed as average on 16 images.^{5,17,36}

Finally, two NVCs from each patient were included in the final analysis: (1) basal NVC: the first NVC showing $>30\ \mu\text{m}$ dilated capillaries before the ‘scleroderma pattern’ development/CTD diagnosis (in cases and CTD controls, respectively) or the first available NVC showing $>30\ \mu\text{m}$ dilated capillaries (in PRP controls); (2) follow-up NVC: the first NVC since the ‘scleroderma pattern’ development/CTD diagnosis (in cases and CTD controls, respectively) or the last available NVC (in PRP controls).

Sequential NVCs were analysed in cases and controls to assess capillary dilations trend over time.

Statistical analysis

Categorical variables were reported with count and percentages, continuous variables with median and interquartile range (IQR). Kruskal-Wallis’s and Mann-Whitney tests were used to detect parameter heterogeneity between patient groups and in head-to-head comparisons, respectively.

A multivariable binomial logistic regression model was designed to investigate potential associations between ‘scleroderma pattern’ development, assessing parameters on basal NVC with the late development of SSc used as dependent variable and all the reported NVC parameter at baseline used as independent variables.

With the exploratory aim of ranking the NVC parameters that could have a higher ‘scleroderma pattern’ discriminative capability, we also performed a bidirectional stepwise selection of the logistic regression model predictors and a recursive partitioning technique assessing the optimal decision rules for clinical evolution classification using NVC basal parameters as starting variables (where higher importance is represented by the presence of a decision nodes closer to the tree-root) (figure 2). Recursive partitioning results were presented as both the optimal dichotomous variables cut-offs and the final decision tree. To avoid overcomplexity the decision tree was limited to a maximum depth of two ramifications³⁷ (figure 2).

A $p<0.05$ was considered statistically significant. R-software V.4.2.0 was used for all statistical analyses (with the packages ‘rpart’ V.4.1.16, ‘rpart.plot’ V.3.1.0 and ‘caret’ V.6.0–92).

RESULTS

Demographic data and clinical features of the study population are summarised in table 1. No significant differences were observed in demographic data and comorbidities between cases and controls.

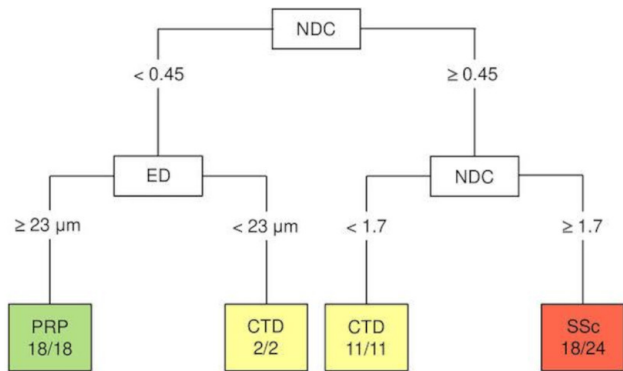


Figure 2 Decision tree of clinical evolution according to baseline NVC parameters. In the recursive partitioning model, the optimal set of decision rules was limited to two dichotomic variables, resulting in a maximum depth of two ramifications. Image reports the set of decision rules who were identified for each group. CTD, connective tissue disease; ED, efferent (venous) diameter of the most dilated capillary for each NVC images (calculated as average on 16 images); NDC, number of >30 µm dilated capillaries for linear mm (calculated as average on 16 images); NVC, nailfold videocapillaroscopy; PRP, primary Raynaud's phenomenon; SSc, systemic sclerosis.

As expected, RP duration (calculated as the time interval between RP onset and the last NVC included in the study) and NVC follow-up time was significantly higher in controls. Consistently, basal NVC was performed at a median time of 21 months (IQR 14–41), 43 months (22–122) and 84 months (IQR 48–192) from RP onset in SSc, CTD and persistent PRP group, respectively (table 1).

As for cases, diagnosis of both 'scleroderma pattern' and associated SSc were made after a median of 4 years (IQR 2–8) from RP onset. Interestingly, the time-varying transition from non-specific capillaroscopic abnormalities to the 'scleroderma pattern' in patients then developing SSc, was observed in only a median 13 months follow-up time (IQR 7–22). Specifically, 13 patients (72%) developed an 'Early' 'scleroderma pattern', 1 patient developed an 'Active' 'scleroderma pattern' and 4 patients (22%) developed a 'scleroderma-like pattern' (data not shown).

Conversely, sequential NVC images performed in controls during the follow-up, showed a stable 'non-scleroderma pattern' over a median follow-up of 44 months (IQR 29–60) and 47 months (IQR 42–53), respectively for CTD and PRP group (table 1).

Capillaroscopic parameters of sequential NVCs in the study population are reported in tables 2 and 3. At basal NVC, significant differences were observed in NVC analysed parameters among the study population. Of note, in SSc group (cases) the amount of >30 µm dilated capillaries/linear mm—both in absolute number and proportion—as well as the apical diameter of the MDC were significantly higher than in control groups ($p < 0.05$ to < 0.001) and average diameter of the MDC was significantly larger than in CTD controls ($p < 0.05$). Collaterally,

the MDC efferent (venous) branch diameter was significantly larger in PRP controls than in cases ($p < 0.005$) (table 2).

Interestingly, during the follow-up, these differences were reinforced, becoming statistically significant for both total capillary number and all those parameters related to capillary dilations (i.e., diameters and amount per linear mm) ($p = < 0.01$ to < 0.001) (table 3).

Conversely, the number of microhaemorrhages did not significantly differ between cases and controls either at baseline NVC or during the follow-up (tables 2 and 3).

Of note, in the stepwise logistic regression analysis, the absolute number of >30 µm dilated capillaries/linear mm, was the only variable to be independently associated with 'scleroderma pattern' development. Specifically, for each increase in a single >30 µm dilated capillary for linear mm, there was a 24% additional risk of evolution towards the 'scleroderma pattern' (OR 1.24, 95% CI 1.17 to 1.32).

As for the number of microhaemorrhages, not any significant association with the 'scleroderma pattern' development emerged from the univariate and multivariable analyses (data not shown).

Concerning serum SSc-related Abs status, only anti-Scl70 Abs positivity was found to significantly correlate with the number of >30 µm dilated capillaries/linear mm on basal NVC ($p < 0.05$) (data not shown).

Finally, a tree-based classification model was used to identify the three groups of clinical evolution (SSc, CTD, PRP) according to basal NVC parameters. Specifically, the following set of decision rules were identified for each group: (1) SSc: high number of >30 µm dilated capillaries (> 1.7 /mm); (2) CTD: mid-range number of >30 µm dilated capillaries (0.45–1.7/mm) OR low number of >30 µm dilated capillaries (< 0.45 /mm) and low efferent (venous) branch diameter of MDC (< 23 µm); (3) PRP: low number of >30 µm dilated capillaries (< 0.45 /mm) and low efferent (venous) branch diameter of MDC (≥ 23 µm). Accordingly, a cut-off of 1.7 capillary dilations (ie, >30 µm dilated capillaries)/linear mm could be interpreted as a predictive variable for 'scleroderma pattern' and SSc development with a positive predictive value (PPV) of 75% (18 patients effectively developing SSc out of 24 patients having > 1.7 capillary dilations/mm). Details on decision tree are presented in figure 2.

DISCUSSION

In this study, we found a statistically significant association between NVC non-specific capillary dilations and later 'scleroderma pattern' development. Specifically, the number of >30 µm dilated capillaries per linear mm proved to be a significant predictive factor for the evolution into a 'scleroderma pattern' and SSc.

Indeed, we demonstrated that each increase in a single >30 µm dilated capillary for linear mm at NVC carries an additional 24% risk of evolution towards the 'scleroderma pattern' (OR 1.24, 95% CI 1.17 to 1.32).

Table 1 Demographics, comorbidities and therapies of the study population

Variables	Overall (55)	SSc (18)	PRP (18)	CTD (19)	p value*
Demographics and laboratory					
Women, n (%)	52 (94.5)	18 (100.0)	16 (88.9)	18 (94.7)	0.340
Age at first NVC, median (IQR), years	52 (38–63)	50 (38–63)	50 (40–59)	52 (40–64)	0.950
Age at RP onset, median (IQR), years	39 (25–52)	46 (33–55)	34 (24–48)	32 (20–49)	0.179
RP duration, † median (IQR), years	7 (4–15)	4 (2–8)	8 (4–17)	9 (6–18)	0.008
Time from RP onset to first NVC, median (IQR), months	46 (18–116)	21 (14–41)	84 (48–192)	43 (22–122)	0.008
NVC follow-up, ‡ median (IQR), months	37 (20–51)	13 (7–22)	47 (42–53)	44 (29–60)	<0.001
ANA positivity, n (%)	37 (67.3)	18 (100.0)	0 (0.0)	19 (100.0)	
SSc-related Abs positivity, n (%)	18 (32.7)	18 (100.0)	0 (0.0)	0 (0.0)	
Comorbidities					
Autoimmune thyroiditis, n (%)	5 (9.1)	3 (16.7)	0 (0.0)	2 (10.5)	
Arterial hypertension, n (%)	16 (29.1)	4 (22.2)	8 (44.4)	4 (21.1)	
Dyslipidaemia, n (%)	11 (20.0)	4 (22.2)	3 (16.7)	4 (21.1)	
Osteoporosis, n (%)	5 (9.1)	2 (11.1)	2 (11.1)	1 (5.3)	
Neoplasms, n (%)	5 (9.1)	2 (11.1)	3 (16.7)	0 (0.0)	
Therapies					
Aminafone, n (%)	9 (16.4)	4 (22.2)	5 (27.8)	0 (0.0)	
Pentoxifylline, n (%)	4 (7.3)	1 (5.6)	3 (16.7)	0 (0.0)	
Acetylsalicylic acid, n (%)	20 (36.4)	9 (50.0)	5 (27.8)	6 (31.6)	
Oral anticoagulant, n (%)	2 (3.6)	1 (5.6)	0 (0.0)	1 (5.3)	
Intravenous prostanoids, n (%)	11 (20.0)	7 (38.9)	2 (11.1)	2 (10.5)	
Endothelin receptor antagonist, n (%)	3 (5.5)	3 (16.7)	0 (0.0)	0 (0.0)	
Statins, n (%)	9 (16.4)	2 (11.1)	3 (16.7)	4 (21.1)	
Beta-blockers, n (%)	13 (23.6)	5 (27.8)	3 (16.7)	5 (26.3)	
Calcium channel blockers, n (%)	12 (21.8)	4 (22.2)	6 (33.3)	2 (10.5)	
ACE inhibitors/ARBs, n (%)	7 (12.7)	2 (11.1)	4 (22.2)	1 (5.3)	
Diuretics, n (%)	9 (16.4)	2 (11.1)	3 (16.7)	4 (21.1)	
Glucocorticoids, n (%)	12 (21.8)	1 (5.6)	0 (0.0)	11 (57.9)	
Hydroxychloroquine, n (%)	8 (14.5)	1 (5.6)	0 (0.0)	7 (36.8)	
Methotrexate, n (%)	2 (3.6)	1 (5.6)	0 (0.0)	1 (5.3)	
Azathioprine, n (%)	2 (3.6)	0 (0.0)	0 (0.0)	2 (10.5)	
Mycophenolate mofetil, n (%)	3 (5.5)	2 (11.1)	0 (0.0)	1 (5.3)	

*Reported p values are the result of Kruskal-Wallis's test assessing heterogeneity between groups. Statistically significant p values are indicated in bold type.

†Time between RP onset and last NVC.

‡Time between baseline NVC and follow-up NVC, considered as the period of observation.

Abs, antibodies; ACE, angiotensin converting enzyme; ANA, anti-nuclear antibodies; ARBs, angiotensin II receptor blockers; CTD, connective tissue disease; IQR, interquartile range; NVC, Nailfold videocapillaroscopy; PRP, primary Raynaud's phenomenon; RP, Raynaud's phenomenon; SSc, systemic sclerosis.

Additionally, we proposed a tree-based decision model assessing total number of >30 µm dilated capillaries/linear mm and efferent (venous) branch diameter of the MDC on basal NVC as possible explanatory tool for later clinical evolution (SSc vs non-SSc conditions). In this model, a cut-off of 1.7 capillary dilations (i.e., >30 µm dilated capillaries)/linear mm was suggested as a

predictive variable for 'scleroderma pattern' and SSc development (PPV 75%).

These results are consistent with existing literature, that has suggested a pivotal role of capillary dilations in SSc microvascular damage and its progression.^{8 22 23 38}

In their seminal work, Koenig *et al.* already reported on the predictive role of specific capillary dilations (at least

Table 2 Capillaroscopic parameters on basal NVC in the study population

	SSc (18)	PRP (18)	CTD (19)	<i>p</i> value*	
				SSc vs PRP	SSc vs CTD
Total n° of capillaries/linear mm† median (IQR), n	7 (7–8)	8 (8–8)	8 (7–9)	0.289	
Total n° of >30 µm dilated capillaries/linear mm†‡ median (IQR), n	3 (3–4)	0 (0–0)	2 (1–2)	<0.001	<0.001
Proportion of >30 µm dilated capillaries/linear mm†‡ median (IQR), %	39 (34–50)	2 (1–3)	17 (9–25)	<0.001	<0.001
Average diameter of the MDC† median (IQR), µm	35 (33–37)	34 (32–35)	32 (28–33)	0.776	0.022
Arterial diameter of the MDC† median (IQR), µm	30 (27–33)	28 (27–31)	28 (22–30)	0.191	
Apical diameter of the MDC† median (IQR), µm	44 (42–47)	38 (35–44)	40 (38–43)	0.001	0.016
Venous diameter of the MDC† median (IQR), µm	29 (26–32)	34 (31–38)	26 (22–29)	0.001	0.395
Microhaemorrhages/linear mm† median (IQR), n	0 (0–1)	0 (0–2)	0 (0–0)	0.416	

*Reported *p* values are the results of Kruskal-Wallis's test or, if significant heterogeneity was detected, the results of head-to-head Mann-Whitney test between groups. Statistically significant *p* values are indicated in bold type.

†Calculated as the average number on 16 images.

‡More than 30 µm dilated capillaries are capillaries with average diameter >30 µm (average diameter is calculated as arterial+apical+venous diameters/3).

CTD, connective tissue disease; IQR, interquartile range; MDC, most dilated capillary for each NVC image; NVC, nailfold videocapillaroscopy; PRP, primary Raynaud's phenomenon; SSc, systemic sclerosis.

Table 3 Capillaroscopic parameters on follow-up NVC in the study population

	SSc (18)	PRP (18)	CTD (19)	<i>p</i> value*
Total number of capillaries/linear mm† median (IQR), n	7 (6–8)	8 (8–9)	8 (8–9)	0.006
Total number of >30 µm dilated capillaries/linear mm†‡ median (IQR), n	3 (2–4)	0 (0–0)	1 (1–2)	<0.001
Proportion of >30 µm dilated capillaries/ linear mm†‡ median (IQR), %	44 (33–54)	1 (0–3)	13 (6–26)	<0.001
Average diameter of the MDC† median (IQR), µm	43 (36–50)	33 (31–34)	30 (28–34)	<0.001
Arterial diameter of the MDC† median (IQR), µm	41 (32–48)	28 (26–30)	27 (25–30)	<0.001
Apical diameter of the MDC† median (IQR), µm	52 (45–56)	38 (37–40)	39 (36–42)	<0.001
Venous diameter of the MDC† median (IQR), µm	38 (32–44)	33 (31–34)	27 (25–30)	0.001
Microhaemorrhages/linear mm† median (IQR), n	0 (0–1)	0 (0–1)	0 (0–0)	0.347

*Reported *p* values are the results of Kruskal-Wallis's test assessing heterogeneity between groups. Statistically significant *p* values are indicated in bold type.

†Expressed as average number on 16 images.

‡ More than 30 µm dilated capillaries are capillaries with average diameter >30 µm (average diameter is calculated as arterial+apical+venous diameters/3).

CTD, connective tissue disease; MDC, most dilated capillary for each NVC image; NVC, nailfold videocapillaroscopy; PRP, primary Raynaud's phenomenon; SSc, systemic sclerosis.

four times-normal loop dilation) for the ‘scleroderma pattern’ development. However, this fundamental work had significant methodological limitations—that is, the use of widefield microscopy with limited magnification analysis (8–50X).^{8 38}

More recently, Ingegnoli *et al* included NVC specific capillary dimensional changes in the first prognostic index (PRINCE index) to identify RP patients eventually developing a scleroderma spectrum disorder (SSD).²² In this regard, it is interesting to observe that the PRINCE index did not include non-specific dilations but just giant capillaries—specific and pathognomonic features of the ‘scleroderma pattern’—as prognostic factors. This is rather not surprising since non-specific dilations, given their earlier presentation, may not achieve the statistical power to predict SSDs, still they might be a reliable predictor only of subsequent ‘scleroderma pattern’ development, as suggested by the present work, thus intercepting SSc damage at an earlier, preclinical stage.

Finally, recent findings from our group investigating NVC non-specific abnormalities have proved a 30 µm threshold value in average capillary dilations detected in RP patients having a significant NPV for not developing the ‘scleroderma pattern’ during the follow-up.²³

The present work is, therefore, to be intended as a more detailed investigation implementing the existing literature and establishing for the first time the positive predictive role of non-specific capillary dilations (>30 µm dilated capillaries) for the ‘scleroderma pattern’ development (cut-off of 1.7 capillary dilations/linear mm, PPV 75%).

Additionally, the tree-based decision model assessing detailed NVC parameters on basal evaluation—that is, total number of >30 µm dilated capillaries/linear mm and efferent (venous) branch diameter of the MDC—may be regarded as a possible further explanatory tool to be better investigated for later clinical evolution of RP patients.

The real interest of these preliminary data is also the demonstration of the progressive homogeneous capillary dilation involving all the capillary branches (classical giant capillaries when >50 µm) in SSc-related microangiopathy, which is at first more evident at apical capillary loop and then involves both the arterial and venous branches. As matter of fact, capillaroscopic alterations characterising the SSc-related ‘scleroderma pattern’ result from the microvascular damage evolving over time and progressively determining the specific abnormalities, makers of the pattern itself.^{8 21}

In strictly physiological terms, the apical capillary pressure results from a balance between precapillary and post-capillary resistance adjustments.^{39 40} In PRP, physiological regulatory mechanisms—as arteriolar vasoconstriction/vasodilation and venular compliance adjustments—can undergo functional alterations, resulting in increased luminal pressure and capillary dilation, mainly involving the apical loop.^{39 41} Conversely, in SSc microvascular damage, the loss of capillary wall efficiency results from

a complex immunopathogenic network activation determining endothelial damage, perivascular inflammation and profibrotic responses.^{21 42}

Therefore, the progressive dilation with diffuse involvement of the whole capillary loop might represent the structural progressive alteration preceding the formation of giant capillaries, established as pathognomonic NVC markers for the ‘scleroderma pattern’.^{23 34}

Incidentally, an increased likelihood of evolution to SSc-related SRP in patients having capillary dilations on baseline NVC had already been just suggested in our previous work, although not formally supported by a statistical significance at that time.²³

Another important aspect emerging from this study is the timing feature of SSc microvascular damage. Consistently with previous literature, a relatively long-time lag between RP onset and SSc diagnosis is confirmed in our study population (median 4 years, IQR 2–8). However, we observed a median transition time of only 13 months (IQR 7, 22) from the first detection of >30 µm dilated capillaries to the onset of a real ‘scleroderma pattern’.

Thus, given the significant predictive role of this latter NVC parameter (>30 µm dilated capillaries), this time interval could be of valuable clinical relevance, offering a window of opportunity for diagnostic and early prognostic intervention in a still preclinical—or ‘very early’—phase of SSc disease, especially when associated with the presence of immunological serum biomarkers, like auto-antibodies (i.e., anti-Scl70 Abs positivity).

Of note and as expected, not any significant evolution in non-specific NVC abnormalities was observed in PRP controls nor in CTD controls after a considerably long follow-up time (RP duration of 8 and 9 years and NVC follow-up time of 47 and 44 months for PRP and CTD, respectively; see [table 1](#)). These results reinforce previous data published by our group suggesting the absence of progression of microvascular damage during CTDs other than SSc.¹³ With respect to the different NVC follow-up time in SSc patients compared with control groups, it is worth noting that, NVC follow-up in cases was interrupted at the first detection of ‘scleroderma pattern’, while in controls only at the clinical diagnosis of disease (for CTD group) or at the last available NVC (for PRP group) (see the Methods section for details).

Concerning microhaemorrhages, no significant association with the ‘scleroderma pattern’ development was found in this study. However, moving from previous reports suggesting the role of microhaemorrhages in predicting SSDs, as well as their important diagnostic role for ‘scleroderma pattern’ definition, it could be of great interest to reconsider this point in future larger studies, possibly providing a validated quantitative scoring system.^{22 43}

Regarding serum SSc-related Abs, the results from our study reported a significant correlation between anti-Scl70 Abs positivity and the number of >30 µm dilated capillaries for linear mm. That is rather not surprising since it mirrors the previously reported association between the

presence of microvascular damage and anti-Scl70 Abs (immune system activation) with an higher risk of disease progression.^{44–47}

Collectively taken, these findings support the essential role of NVC for properly approaching and managing RP patients, together with a complete clinical evaluation and laboratory assessment.⁴⁸

Particularly, capillaroscopic non-specific abnormalities preceding the ‘scleroderma pattern’ seem to be a ‘very early’ preclinical hallmark to be accurately detected and monitored since they may represent potential precursor signals of an incoming overt and progressive SSc-related microangiopathy. That has a tremendous relevance since a proper diagnosis of ‘very early’ SSc must necessarily be made at a preclinical stage when organ involvement is not yet established. In fact, as recently reported, patients fulfilling the previously proposed criteria for the very early diagnosis of SSc quite invariably already presented clinical manifestation of the disease.⁴⁹

To our knowledge, this is the first study to show that the number of >30 µm dilated capillaries/linear mm is a significant predictive factor of evolution towards ‘scleroderma pattern’, thus being a warning flag in those patients routinely assessed for RP in clinical practice. Additionally, we have first described the progressive homogeneous capillary dilation in SSc-related microangiopathy that mirrors the evolving vascular damage, also identifying capillaroscopic warning parameters for evolution from PRP to SSc-related SRP.

Nevertheless, some limitation of the study must be mentioned.

First, this is a single-centre pilot study on a relatively small patient population attending one referral institution. Of note, the extension of the study follow-up over a 10-year period necessarily implied a reduced number of patients having sufficient data for the correct analysis. Still, the statistical analysis found a convincing significance despite this sample size limitation.

Second, being an NVC-based study, only those patients later developing a ‘scleroderma pattern’ among other criteria for SSc diagnosis were included as cases.

Additionally, since the retrospective study covered a 10-year time, some important clinical data—as clinical features progressively associating to RP, therapeutic interventions/lifestyles/comorbidities—could have been lost, possibly altering results interpretation. Similarly, the follow-up period is different for each enrolled patient, both in overall time and in timepoints of observation.

As for the tree-based classification model used in the recursive partitioning analysis, given its known vulnerability to overfitting, it was aimed at explorative purpose only. Confirmation of our findings with ensemble methods, larger sample size and denser timepoints are needed.

Finally, since this study has been conceived as a logical evolution of our previous investigation (showing the NPV of non-specific <30 µm capillary dilations for ‘scleroderma pattern’ development), only RP patients

with non-specific >30 µm capillary dilations on baseline NVC were included. From a pathogenic point of view, it could be reasonably assumed that even those PRP patients having non-specific >30 µm capillary dilations may evolve in SRP over a longer-term follow-up than that evaluated in this study. Anyway, as previously reported by our group, the NVC transition from PRP to SSc-related RP could be observed even in a relatively short time period (29.4±10 months).²⁰ Interestingly, this time interval appears to be consistently shorter in our study, showing a median transition time of 13 months from non-specific >30 µm capillary dilations to SSc-related NVC ‘scleroderma pattern’.

Nonetheless, this pilot capillaroscopic study may significantly contribute to current understanding of SSc-related and progressive microangiopathy.

In conclusion, this investigation showed that very early and multiple (>1.7/linear mm) homogeneous NVC non-specific capillary dilations (>30 µm capillary dilations) may contribute to identify RP patients who will develop a ‘scleroderma pattern’ within a relatively short follow-up time.

Further investigation is needed to confirm these preliminary original data in larger prospective studies, paving the way for a possible earlier clinical approach and a refined pathogenic insight into SSc disease.

Acknowledgements The authors would like to thank Dr. Giampaola Pesce for the laboratory analysis and Dr. Sara De Gregorio for her graphic support. MC, VS, EG, CP, AS, SP are BOARD members of the EULAR Study Group on Microcirculation in Rheumatic Diseases. MC and VS are BOARD members of the European Network on Rare and Complex Connective Tissue Diseases (ERN ReCONNECT). VS is a Senior Clinical Investigator of the Research Foundation - Flanders (Belgium) (FWO) (1.8.029.20N). The FWO was not involved in study design, collection, analysis and interpretation of data, writing of the report, nor in the decision to submit the article for publication.

Contributors MC conceived and designed the study, supervised and approved the final manuscript. GP performed important parts of the study, contributed to data interpretation and drafted the final manuscript. AP, MP and CP performed important parts of the study. CP performed all NVC analyses. LC performs the statistical analysis. VS contributed to the review of scientific contents. All authors contributed to the acquisition of data and read and approved the final manuscript. MC is the guarantor of the study who accepts full responsibility for the work and the conduct of the study, had access to the data, and controlled the decision to publish. VS and MC share last name.

Funding The authors have not declared a specific grant for this research from any funding agency in the public, commercial or not-for-profit sectors.

Competing interests None declared.

Patient consent for publication Not applicable.

Ethics approval This study involves human participants and was approved by ID n. 36/2010 Participants gave informed consent to participate in the study before taking part.

Provenance and peer review Not commissioned; externally peer reviewed.

Data availability statement Data are available on reasonable request.

Open access This is an open access article distributed in accordance with the Creative Commons Attribution Non Commercial (CC BY-NC 4.0) license, which permits others to distribute, remix, adapt, build upon this work non-commercially, and license their derivative works on different terms, provided the original work is properly cited, appropriate credit is given, any changes made indicated, and the use is non-commercial. See: <http://creativecommons.org/licenses/by-nc/4.0/>.

ORCID iDs

Greta Pacini <http://orcid.org/0000-0003-3678-4452>

Maurizio Cutolo <http://orcid.org/0000-0002-5396-0932>

REFERENCES

- 1 Flavahan NA. A vascular mechanistic approach to understanding Raynaud phenomenon. *Nat Rev Rheumatol* 2015;11:146–58.
- 2 Herrick AL, Cutolo M. Clinical implications from capillaroscopic analysis in patients with Raynaud's phenomenon and systemic sclerosis. *Arthritis Rheum* 2010;62:2595–604.
- 3 Cutolo M, Smith V, Furst DE, et al. Points to consider-Raynaud's phenomenon in systemic sclerosis. *Rheumatology* 2017;56:v45–8.
- 4 Herrick AL, Dinsdale G, Murray A, et al. New perspectives in the imaging of Raynaud's phenomenon. *Eur J Rheumatol* 2020;7:212–21.
- 5 Smith V, Herrick AL, Ingegnoli F, et al. Standardisation of nailfold capillaroscopy for the assessment of patients with Raynaud's phenomenon and systemic sclerosis. *Autoimmun Rev* 2020;19:102458.
- 6 Smith V, Thevissen K, Trombetta AC, et al. Nailfold capillaroscopy and clinical applications in systemic sclerosis. *Microcirculation* 2016;23:364–72.
- 7 Maricq HR. Wide-Field capillary microscopy. *Arthritis Rheum* 1981;24:1159–65.
- 8 Koenig M, Joyal F, Fritzier MJ, et al. Autoantibodies and microvascular damage are independent predictive factors for the progression of Raynaud's phenomenon to systemic sclerosis: a twenty-year prospective study of 586 patients, with validation of proposed criteria for early systemic sclerosis. *Arthritis Rheum* 2008;58:3902–12.
- 9 van den Hoogen F, Khanna D, Fransen J, et al. 2013 classification criteria for systemic sclerosis: an American College of Rheumatology/European League against rheumatism collaborative initiative. *Arthritis Rheum* 2013;65:2737–47.
- 10 Sulli A, Ruaro B, Smith V, et al. Progression of nailfold microvascular damage and antinuclear antibody pattern in systemic sclerosis. *J Rheumatol* 2013;40:634–9.
- 11 Smith V, Scirè CA, Talarico R, et al. Systemic sclerosis: state of the art on clinical practice guidelines. *RMD Open* 2019;4:e000782.
- 12 Cutolo M, Melsens K, Herrick AL, et al. Reliability of simple capillaroscopic definitions in describing capillary morphology in rheumatic diseases. *Rheumatology* 2018;57:757–9.
- 13 Cutolo M, Melsens K, Wijnant S, et al. Nailfold capillaroscopy in systemic lupus erythematosus: a systematic review and critical appraisal. *Autoimmun Rev* 2018;17:344–52.
- 14 Melsens K, Leone MC, Paolino S, et al. Nailfold capillaroscopy in Sjögren's syndrome: a systematic literature review and standardised interpretation. *Clin Exp Rheumatol* 2020;38 Suppl 126:150–7.
- 15 Ferrari G, Gotelli E, Paolino S, et al. Antiphospholipid antibodies and anticoagulant therapy: capillaroscopic findings. *Arthritis Res Ther* 2021;23:175.
- 16 Pizzorni C, Ferrari G, Schenone C, et al. Capillaroscopic analysis of the microvascular status in mixed versus undifferentiated connective tissue disease. *Microvasc Res* 2022;142:104367.
- 17 Smith V, Vanhaecke A, Herrick AL, et al. Fast track algorithm: How to differentiate a "scleroderma pattern" from a "non-scleroderma pattern". *Autoimmun Rev* 2019;18:102394.
- 18 Schneeberger D, Tyndall A, Kay J, et al. Systemic sclerosis without antinuclear antibodies or Raynaud's phenomenon: a multicentre study in the prospective EULAR scleroderma trials and research (EUSTAR) database. *Rheumatology* 2013;52:560–7.
- 19 Cutolo M, Smith V. State of the art on nailfold capillaroscopy: a reliable diagnostic tool and putative biomarker in rheumatology? *Rheumatology* 2013;52:1933–40.
- 20 Cutolo M, Pizzorni C, Sulli A. Identification of transition from primary Raynaud's phenomenon to secondary Raynaud's phenomenon by nailfold videocapillaroscopy: Comment on the article by Hirschl et al. *Arthritis Rheum* 2007;56:2102–3.
- 21 Cutolo M, Soldano S, Smith V. Pathophysiology of systemic sclerosis: current understanding and new insights. *Expert Rev Clin Immunol* 2019;15:753–64.
- 22 Ingegnoli F, Boracchi P, Gualtierotti R, et al. Prognostic model based on nailfold capillaroscopy for identifying Raynaud's phenomenon patients at high risk for the development of a scleroderma spectrum disorder: Prince (prognostic index for nailfold capillaroscopic examination). *Arthritis Rheum* 2008;58:2174–82.
- 23 Trombetta AC, Smith V, Pizzorni C, et al. Quantitative alterations of capillary diameter have a predictive value for development of the Capillaroscopic systemic sclerosis pattern. *J Rheumatol* 2016;43:599–606.
- 24 Belch J, Carlizza A, Carpentier PH, et al. ESVM guidelines - the diagnosis and management of Raynaud's phenomenon. *Vasa* 2017;46:413–23.
- 25 Mavarakis E, Patel F, Kronenberg DG. International consensus criteria for the diagnosis of Raynaud's phenomenon. *J Autoimmun* 2014;48:60–495.
- 26 Park J-S, Park M-C, Song JJ, et al. Application of the 2013 ACR/EULAR classification criteria for systemic sclerosis to patients with Raynaud's phenomenon. *Arthritis Res Ther* 2015;17.
- 27 Sharp GC. *Diagnostic criteria for classification of MCTD*. Elsevier, 1987.
- 28 Alarcón-Segovia D, Villareal M. *Classification and Diagnostic Criteria for Mixed Connective Tissue Disease*, Elsevier, 1987.
- 29 Kasukawa R, Tojo T, Miyawaki S. *Preliminary diagnostic criteria for classification of mixed connective tissue disease. Mixed Connective Tissue Disease and Antinuclear Antibodies*, Elsevier, 1987.
- 30 Kahn MF, Appeboom T. Syndrome de sharp. *Flammarion* 1991;3:545–56.
- 31 Antunes M, Scirè CA, Talarico R, et al. Undifferentiated connective tissue disease: state of the art on clinical practice guidelines. *RMD Open* 2018;4:e000786.
- 32 Chaigne B, Scirè CA, Talarico R, et al. Mixed connective tissue disease: state of the art on clinical practice guidelines. *RMD Open* 2019;4:e000783.
- 33 Jeong S, Hwang H, Roh J, et al. Evaluation of an automated screening assay, compared to indirect immunofluorescence, an extractable nuclear antigen assay, and a line immunoassay in a large cohort of Asian patients with antinuclear antibody-associated rheumatoid diseases: a multicenter retrospective study. *J Immunol Res* 2018;2018::9094217.
- 34 Cutolo M, Sulli A, Pizzorni C, et al. Nailfold videocapillaroscopy assessment of microvascular damage in systemic sclerosis. *J Rheumatol* 2000;27:155–60.
- 35 Smith V, Pizzorni C, De Keyser F, et al. Reliability of the qualitative and semiquantitative nailfold videocapillaroscopy assessment in a systemic sclerosis cohort: a two-centre study. *Ann Rheum Dis* 2010;69:1092–6.
- 36 Cutolo M, Sulli A, Smith V. Assessing microvascular changes in systemic sclerosis diagnosis and management. *Nat Rev Rheumatol* 2010;6:578–87.
- 37 Breiman L, Friedman JH, Olshen RA. *Classification and Regression Trees*. Routledge, 1984.
- 38 Maricq HR. Widefield capillary microscopy. technique and rating scale for abnormalities seen in scleroderma and related disorders. *Arthritis & Rheumatism* 1981;24:1159–65.
- 39 Mahy IR, Tooke JE, Shore AC. Capillary pressure during and after incremental venous pressure elevation in man. *J Physiol* 1995;485 (Pt 1):213–9.
- 40 Ubbink DT, Reneman RS, Jacobs MJ. Effects of venous pressure and posture on skin capillary perfusion. *Eur J Clin Invest* 1999;29:737–43.
- 41 Herrick AL, Clark S. Quantifying digital vascular disease in patients with primary Raynaud's phenomenon and systemic sclerosis. *Ann Rheum Dis* 1998;57:70–8.
- 42 Soldano S, Paolino S, Pizzorni C, et al. Dual endothelin receptor antagonists contrast the effects induced by endothelin-1 on cultured human microvascular endothelial cells. *Clin Exp Rheumatol* 2017;35:484–93.
- 43 Del Papa N, Pignataro F, Maglione W, et al. High NEMO score values in nailfold videocapillaroscopy are associated with the subsequent development of ischaemic digital ulcers in patients with systemic sclerosis. *Arthritis Res Ther* 2020;22:237.
- 44 Ingegnoli F, Boracchi P, Gualtierotti R, et al. Improving outcome prediction of systemic sclerosis from isolated Raynaud's phenomenon: role of autoantibodies and nail-fold capillaroscopy. *Rheumatology* 2010;49:797–805.
- 45 Valentini G, Marcoccia A, Cuomo G, et al. Early systemic sclerosis: marker autoantibodies and videocapillaroscopy patterns are each associated with distinct clinical, functional and cellular activation markers. *Arthritis Res Ther* 2013;15:R63.
- 46 Martin M, Martinez C, Arnaud L, et al. Association of antiphospholipid antibodies with active digital ulceration in systemic sclerosis. *RMD Open* 2019;5:e001012.
- 47 Landon-Cardinal O, Baril-Dionne A, Hoa S, et al. Recognising the spectrum of scleromyositis: HEP-2 ANA patterns allow identification of a novel clinical subset with anti-SMN autoantibodies. *RMD Open* 2020;6:e001357.
- 48 Cutolo M, Paolino S, Smith V. Nailfold capillaroscopy in rheumatology: ready for the daily use but with care in terminology. *Clin Rheumatol* 2019;38:2293–7.
- 49 Blaja E, Jordan S, Mihai C-M, et al. The challenge of very early systemic sclerosis: a combination of mild and early disease? *J Rheumatol* 2021;48:82–6.