

Plantar pain is not always fasciitis

N. Romano¹, A. Fischetti¹, V. Prono¹, S. Migone¹, F. Barbieri²,
C. Pizzorni², G. Garlaschi¹, M.A. Cimmino²

¹Division of Radiology, and ²Research Laboratory and Academic Division of Clinical Rheumatology, Department of Internal Medicine, University of Genoa, Genoa, Italy

SUMMARY

The case is described of a patient with chronic plantar pain, diagnosed as fasciitis, which was not improved by conventional treatment. Magnetic resonance imaging revealed flexor hallucis longus tenosynovitis, which improved after local glucocorticoid injection.

Key words: Plantar pain; Fasciitis; Tenosynovitis; Flexor hallucis longus.

Reumatismo, 2017; 69 (4): 189-190

RADIOLOGICAL VIGNETTE

Plantar pain is a frequent musculoskeletal problem. It is usually due to plantar fasciitis, a condition affecting 3.6% of the general population (1). When pain persists in spite of conservative treatment and rest, the cause could be inflammatory because enthesitis is a common manifestation of seronegative spondyloarthritides (2). Alternatively, pain could be caused by involvement of a different structure. We report a patient treated for one year for plantar fasciitis, who was affected by flexor hallucis longus (FHL) tenosynovitis diagnosed by magnetic resonance imaging (MRI).

A 50-year-old man presented with a one-year history of severe pain on the medial side of the sole of the feet that was more intense in the right foot. Pain intensity on a 100 mm visual analogue scale was 60 mm. His medical history was unremarkable except for dyslipidemia and previous rupture of the left Achilles tendon. He had been an active sportsman, who practiced jogging and climbing. Conventional radiography showed one entesophyte of the right calcaneum. Plantar fasciitis was diagnosed and he was treated with rest, NSAIDs, local injections of platelet rich plasma and physiotherapy without efficacy.

At physical examination in the rheumatology outpatient clinic, tenderness was present at pressure of the sole of the feet. This

was more intense on the right side. The calcaneal insertion of the fascia was not tender. Pain was not elicited at extension and flexion of the great toe.

An MRI exam was performed on a dedicated 0.3 T unit (Oscan, Esaote, Genova, Italy) with T1-weighted spin echo, STIR and 3DT1 sequences on the three planes of the space. Increased thickness (6 mm) of the medial band of the plantar fascia without signs of inflammation was seen in the sagittal plane. It was associated with slight edema of the adipose subcutaneous tissues. Fluid was seen surrounding the FHL tendon, a finding suggesting tenosynovitis (Figure 1a). In the axial plane, FHL tenosynovitis was demonstrated up to the level of the first cuneiform. No bone edema was observed. The other tendons and ligaments were normal (Figure 2a and b).

The patient was treated with deep peritendinous injection of long-acting glucocorticoids through a plantar approach. The needle was inserted based on the measurements obtained from the MRI images. After five weeks, pain intensity was decreased to 20 mm and a new MRI showed almost complete disappearance of tenosynovitis (Figures 1b and 2c).

FHL tenosynovitis is usually seen in dancers and long-distance runners (3). Associated symptoms can be felt anywhere along the length of the FHL from the posterior leg to the plantar foot and the hallux. Misdiag-

Corresponding author
Marco A. Cimmino
Research Laboratory
and Academic Division
of Clinical Rheumatology,
Department of Internal Medicine,
University of Genoa
Viale Benedetto XV, 6
16132 Genoa, Italy
E-mail: cimmino@unige.it

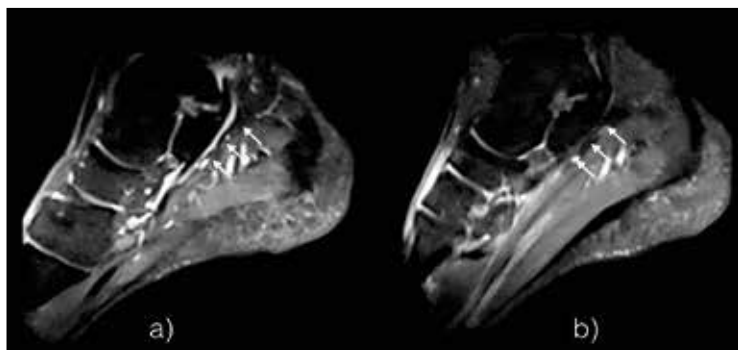


Figure 1 - Sagittal image of a STIR sequence of the foot showing the flexor hallucis longus tendon (arrows) at baseline (a) and five weeks after a local glucocorticoid injection (b). Note the fluid effusion around the tendon, which disappeared at follow up.

ent in our patient, however. In conclusion, FHL tenosynovitis was suspected in our patient at physical examination and confirmed by MRI. The diagnosis could also have been obtained by ultrasonography, which is cheaper and widely available. However, we had the opportunity to use a dedicated MRI machine in our outpatient clinic, which provided diagnostic aid in real time. MRI has the advantage of evaluating simultaneously the bone, synovial membrane and soft tissues.

Competing interests: There are no competing interests regarding this paper.

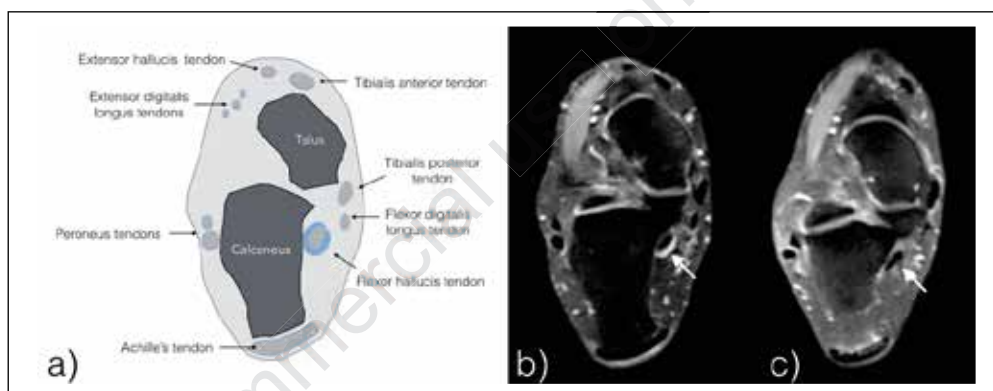


Figure 2 - Axial image of a STIR sequence of the foot showing the flexor hallucis longus tendon (arrow) at baseline (b) and five weeks after a local glucocorticoid injection (c). The drawing (a) shows the anatomical landmarks.

nosis of this condition as plantar fasciitis is made in 55.5% of patients (4). Conservative treatment is effective in the majority of patients, but surgery is necessary in about one third (3, 4).

Another possible differential diagnosis is os trigonum syndrome (5), a posterior impingement syndrome of the ankle, which presents with chronic pain. It is also frequent in dancers as result of an overuse syndrome. Os trigonum originates from the failure of a secondary ossification center to fuse to the lateral tubercle posterior process of the talus. When the FLH tendon travels between the medial and the lateral tubercle of the talar posterior process, compression of the tendon by the os trigonum with associated tenosynovitis can occur. Os trigonum was not pres-

REFERENCES

1. Pollack A, Britt H. Plantar fasciitis in Australian general practice. *Austr Fam Pract.* 2015; 44: 90-1.
2. Ansell RC, Shuto T, Busquets-Perez N, et al. The role of biomechanical factors in ankylosing spondylitis: the patient's perspective. *Reumatismo.* 2015; 67: 91-6.
3. Funasaki H, Hayashi H, Sakamoto K, et al. Arthroscopic release of flexor hallucis longus tendon sheath in female ballet dancers: dynamic pathology, surgical technique, and return to dancing performance. *Arthros Techn.* 2015; 4: e769-74.
4. Michelson J, Dunn L. Tenosynovitis of the flexor hallucis longus: a clinical study of the spectrum of presentation and treatment. *Foot Ankle Int.* 2015; 26: 291-303.
5. Song AJ, Del Giudice M, Lazarus ML, et al. Radiologic case study. Os trigonum syndrome. *Orthopedics* 2013; 36: 63-8.